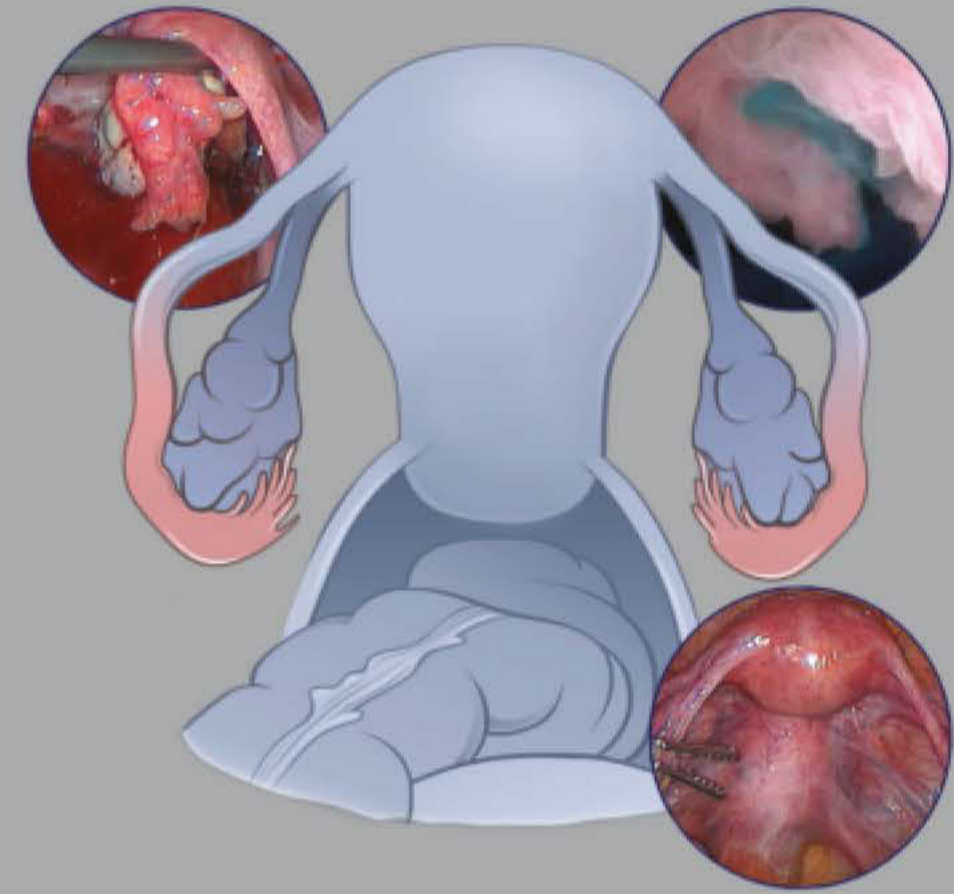


MANUAL OF GYNECOLOGICAL LAPAROSCOPIC SURGERY
Luca MENCAGLIA • Luca MINELLI • Arnaud WATTIEZ

MANUAL OF GYNECOLOGICAL LAPAROSCOPIC SURGERY

IInd Edition



**Luca MENCAGLIA
Luca MINELLI
Arnaud WATTIEZ**

MANUAL OF GYNECOLOGICAL LAPAROSCOPIC SURGERY

IInd Edition

Prof. **Luca MENCAGLIA**, M.D.

Scientific Head of the “Centro Oncologico Fiorentino” (CFO),
Florence, Italy

Dr. **Luca MINELLI**, M.D.

Head of Department of Gynecology and Obstetrics
“Sacro Cuore” General Hospital, Negrar, Italy

Prof. **Arnaud WATTIEZ**, M.D.

Head of Department of Gynecology and Obstetrics
Faculty of Medicine, University Hospital of Strasbourg, France

Co-authors:

Elizabet ABDALLA

Paulo AYROZA

Department of Gynecology and Obstetrics,
Medical School of the Santa Casa University
of São Paulo, Brazil

Fabrizio BARBIERI

Stefano LANDI

Department of Gynecology and Obstetrics,
“Sacro Cuore” General Hospital, Negrar, Italy

Cristiana BARBOSA

Sabrina CONSIGLI

Emmanuel LUGO

Centro Oncologico Fiorentino,
Florence, Italy

Fabio IMPERATO

Mario MALZONI

Malzoni Medical Center “Villa dei Platani”,
Avellino, Italy

Carlo TANTINI

Department of Gynecology and Obstetrics,
Hospital of Cecina, Italy

Daiana TONELLOTTI

Barra D’Or Hospital, Rio de Janeiro, Brazil

Beatrice VIDELA

Leopoldo Carlos VIDELA

Callao Surgical Institute,
Buenos Aires, Argentina

Correspondence Addresses:

Prof. Dr. **Luca Mencaglia**
 Centro Oncologico Fiorentino,
 Via Ragionieri, 101, 50019 Sesto Fiorentino, Firenze, Italy
 Phone: +39/05553010
 E-mail: info@centroncologicofiorentino.it
 Web: www.centroncologicofiorentino.it

Dr. Luca Minelli

Direttore U.O. di Ginecologia e Ostetricia,
 Ospedale "Sacro Cuore", Negrar – Verona
 Via Don A. Sempredoni, 5
 37024 Negrar (VR), Italy

Prof. Dr. Arnaud Wattiez

IRCAD/EITS, Hôpitaux Universitaires de Strasbourg
 Service de Gynécologie-Obstétrique
 1, place de l'Hôpital
 67091 Strasbourg Cedex, France

Please note:

Medical knowledge is constantly changing. As new research and clinical experience broaden our knowledge, changes in treatment and therapy may be required. The authors and editors of the material herein have consulted sources believed to be reliable in their efforts to provide information that is complete and in accordance with the standards accepted at the time of publication. However, in view of the possibility of human error by the authors, editors, or publisher of the work herein, or changes in medical knowledge, neither the authors, editors, publisher, nor any other party who has been involved in the preparation of this work, can guarantee that the information contained herein is in every respect accurate or complete, and they cannot be held responsible for any errors or omissions or for the results obtained from use of such information. The information contained within this brochure is intended for use by doctors and other health care professionals. This material is not intended for use

**Manual of Gynecological Laparoscopic Surgery
IInd Edition**

Prof. **Luca MENCAGLIA**, M.D.
 Scientific Head of „Centro Oncologico Fiorentino“,
 Florence, Italy

Dr. **Luca MINELLI**, M.D.
 Head of Department of Gynecology and Obstetrics,
 “Sacro Cuore” General Hospital, Negrar, Italy

Prof. **Arnaud WATTIEZ**, M.D.
 Head of Department of Gynecology and Obstetrics,
 Faculty of Medicine, University Hospital of Strasbourg,
 Strasbourg, France

© 2013 **Endo! Press**®, Tuttlingen, Germany
 Printed in Germany, ISBN 978-3-89756-405-3
 P.O. Box, D-78503 Tuttlingen, Germany
 Phone: +49 7461/14590
 Fax: +49 7461/708-529
 E-mail: Endopress@t-online.de

Editions in languages other than English and German are in preparation. For up-to-date information, please contact **Endo! Press**®, Tuttlingen, Germany, at the address given above.

Typesetting and color image processing:

Endo! Press®, 78532 Tuttlingen, Germany

Printed by:

Straub Druck+Medien AG, 78713 Schramberg, Germany

as a basis for treatment decisions, and is not a substitute for professional consultation and/or use of peer-reviewed medical literature.

Some of the product names, patents, and registered designs referred to in this booklet are in fact registered trademarks or proprietary names even though specific reference to this fact is not always made in the text. Therefore, the appearance of a name without designation as proprietary is not to be construed as a representation by the publisher that it is in the public domain.

All rights reserved. No part of this publication may be translated, reprinted or reproduced, transmitted in any form or by any means, electronic or mechanical, now known or hereafter invented, including photocopying and recording, or utilized in any information storage or retrieval system without the prior written permission of the copyright holder.


Contents

I	Instrumentation and Operating Room Setup Cristiana Barbosa and Luca Mencaglia	7
II	Use of Electricity in Laparoscopy Paulo Ayroza and Elizabet Abdalla	39
III	Ergonomics in Laparoscopy Arnaud Wattiez	47
IV	Gynecologic Laparoscopic Surgical Anatomy Cristiana Barbosa, Arnaud Wattiez and Luca Mencaglia	57
V	Suturing Techniques in Gynecologic Laparoscopy Daiana Tonello, Paulo Ayroza, Arnaud Wattiez and Luca Mencaglia	73
VI	The Role of Diagnostic Laparoscopy and Transvaginal Endoscopy (TVE) in Infertility and Assisted Reproduction Technology (ART) Emmanuel Lugo, Carlo Tantini and Luca Mencaglia	87
VII	Techniques of Laparoscopic Tubal Sterilization Emmanuel Lugo and Luca Mencaglia	97
VIII	Laparoscopic Tubal Surgery Emmanuel Lugo and Luca Mencaglia	103
IX	Laparoscopic Management of Ectopic Pregnancy Cristiana Barbosa and Luca Mencaglia	115
X	Laparoscopic Surgery for Symptomatic Endometriosis Luca Mencaglia, Arnaud Wattiez and Sabina Consigli	123
XI	Laparoscopic Management of Deep Endometriosis Luca Minelli and Stefano Landi	129
XII	Technique of Laparoscopic Myomectomy Stefano Landi and Luca Minelli	139
XIII	Laparoscopic Treatment of Adnexal Masses Mario Malzoni and Fabio Imperato	151
XIV	Laparoscopic Management of Borderline Ovarian Tumors Paulo Ayroza and Elizabet Abdalla	165
XV	Laparoscopic Hysterectomy Arnaud Wattiez	173
XVI	Laparoscopic Surgery of the Pelvic Floor Arnaud Wattiez	187
XVII	Laparoscopic Surgical Staging of Endometrial Carcinoma Fabrizio Barbieri and Luca Minelli	201
XVIII	Laparoscopic Pelvic and Lumbo-aortic Lymphadenectomy Fabrizio Barbieri and Luca Minelli	207
XIX	Complications in Laparoscopic Surgery Leopoldo Carlos Videla Rivero and Beatrice Videla Rivero	213
	Recommended Set for Gynecological Laparoscopic Surgery	227

Chapter I

Instrumentation and Operating Room Setup

Cristiana Barbosa and Luca Mencaglia
Centro Oncologico Fiorentino, Florence, Italy



1.0 Introduction

Modern endoscopy not only revolutionized medical diagnostics, but also paved the way for a new branch of operative technology: minimally invasive surgery. Although laparoscopic procedures are performed with few instruments, technology remains very important, considering the significance of the interaction between the surgeon and the instruments. Knowledge of the instrumentation allows the surgeon to overcome a series of dysfunctions or malfunctions that arise quite frequently in laparoscopic surgery. Recently, computerized designing of laparoscopic instrument has become commonplace and microprocessorcontrolled safety features have been added. Now, rapid growth of minimally invasive surgery is virtually unstoppable and new procedures are added almost daily. Laparoscopy is quite technologically dependent and every surgeon should have a reasonably good knowledge of these instruments before starting surgery.

KARL STORZ has developed an operating room concept which is tailor-made to meet the requirements of this type of surgery. With the design of system workstations, KARL STORZ OR1™ has set a new standard for harmonizing individual surgical procedures, thus reducing stress for surgeons and medical staff. On account of the fact, that the saved time can be spent on coordinating tasks, more time is available for the patient and, as a result, medical treatment of a continually high standard is guaranteed.

The integrated device management offered by the KARL STORZ OR1™ enables specialized or interdisciplinary configuration of operating rooms. Predefined individual device settings allow OR capacities to be used more efficiently and ensure that scheduled operating times are adhered to. The central networking of hard- and software components in the KARL STORZ OR1™ is the modern and efficient approach to device communication, and allows complete control of the entire endoscopic operative procedure from within the sterile area. The simple and coordinated control of the devices via central panel control, touch screen or speech control accelerates the operative procedures and reduces the risk of incorrect equipment usage during the intervention.

The standardized KARL STORZ Communication Bus (SCB) Interface forms the basis for using the entire system. Endoscopic devices, such as video cameras, cold light sources, insufflators, suction and irrigation pumps as well as the operating table, blinds and operating light are controlled via the SCB.

An integrated digital recording system simplifies archiving of image, video and audio data of important surgical steps and results. This information can be used for both patient documentation and scientific evaluations. Connection to the Hospital Information System (HIS) and Picture Archiving and Communication System (PACS) optimizes quick access to patient and image data.

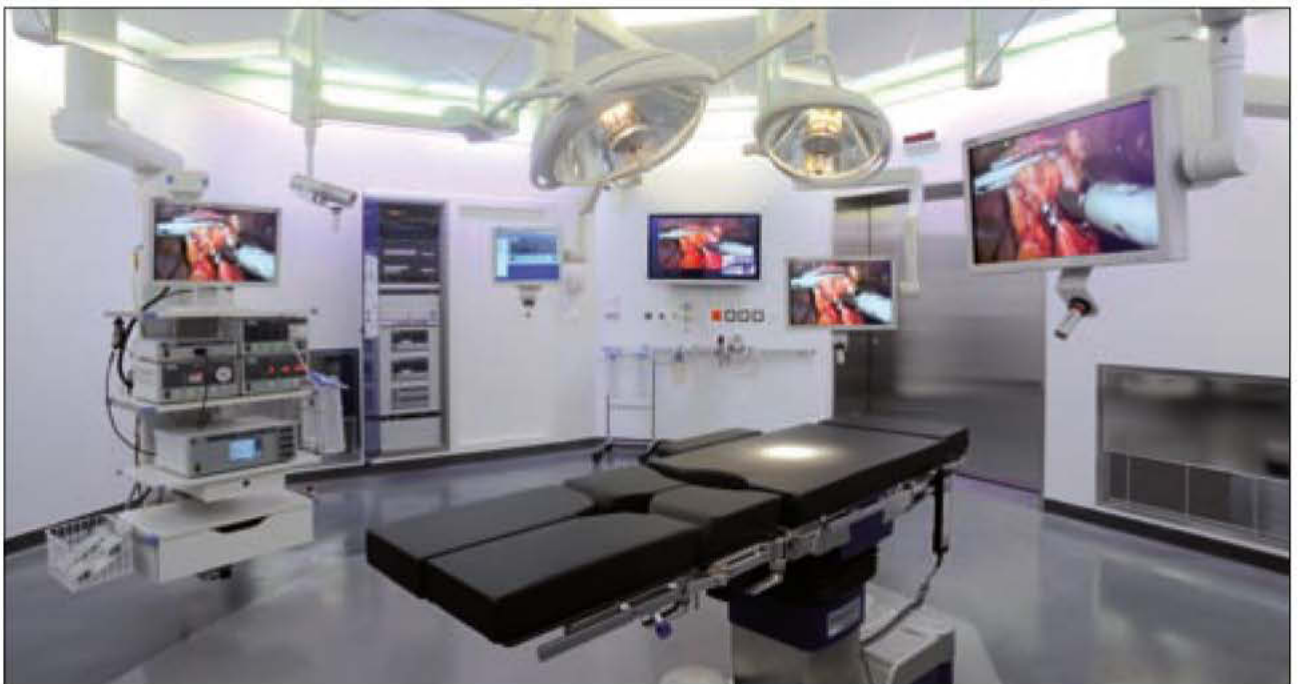

Fig. 1a
The system configuration of the operating room OR1® (KARL STORZ Tuttlingen, Germany).

In addition, telemedicine applications, such as video conferences featuring live operations for teaching and training purposes, can be controlled directly from the sterile area due to the integration of state-of-the-art audio and video technology. This also allows the 'virtual presence' of a remotely placed expert, who would be able to provide a second opinion to an ongoing live operative procedure.

Using a KARL STORZ OR1™ with integrated high-definition (HD) technology is of added benefit to surgeons, clinical staff and patients alike. The HD imaging platform enables visualization via HD widescreen flatpanel monitors with a maximum resolution of 1920 x 1080 pixels at 16:9 aspect ratio offering a more natural, panoramic view, that reflects the anatomy of

human vision. The HD video image can be simultaneously displayed on all cross-linked HD video monitors of the OR or adjoining rooms.

The modular design of the system makes it possible to integrate central panel control, image recording and archiving as well as telemedicine into an existing operating room step by step. Thanks to the open system architecture, KARL STORZ OR1™ also guarantees optimal utilization of the potential offered by new technology, including future medical developments. The integration of additional devices from other manufacturers is made possible by using interface standards.

2.0 Techniques for Creating the Pneumoperitoneum and Abdominal Access

Laparoscopy is a technique that allows viewing and surgical manoeuvres to be performed on abdominal viscera through an incision of less than 1 cm. Pelvic visualization is much better through the laparoscope than in traditional surgery, which requires an access opening of several centimetres.

Creation of the pneumoperitoneum is, with the exception of gasless laparoscopy, a prerequisite for performing laparoscopy correctly. A Veress needle and an insufflator are needed. It is important to note, that this is a blind procedure with the risk of complications arising from the accidental puncture of bowel or vessels.

The positive pressure of the pneumoperitoneum gives the surgeon numerous advantages, such as space, dissection and hemostasis. The trocar accommodating the endoscope

can be placed after successful creation of the pneumoperitoneum with the aid of a Veress needle, either by blind direct insertion of the trocar, or by an open laparoscopy approach. Abdominal access techniques used in laparoscopy are either a closed or open access (also known as open laparoscopy). In the closed access, the pneumoperitoneum is created by using a Veress needle and the primary trocar. This is a blind technique and most commonly practiced as a means of access by surgeons and gynecologists worldwide. Open access is the direct entry without creating a pneumoperitoneum; the insufflator is connected after the trocar has been inserted in the abdominal cavity under direct endoscopic vision.

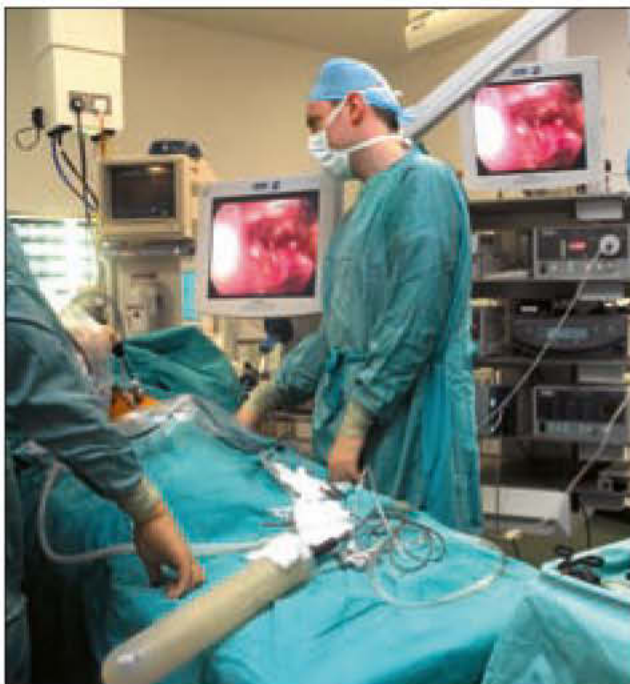

Fig. 1b
Overhead boom system in an operating room. Because the equipment hangs from the ceiling, it does not interfere with surgeon and staff movement.

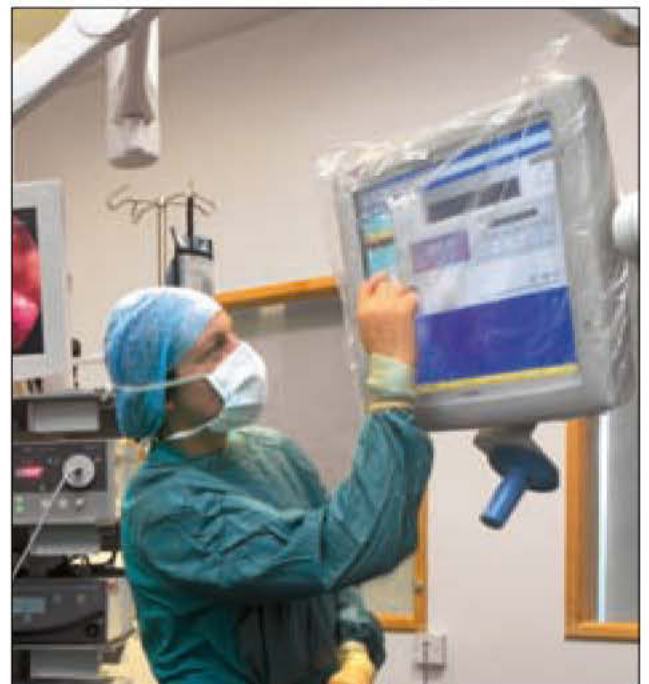


Fig. 1c
The physician or the charge nurse can control all equipment and peripheral systems via touch screen in the sterile area.

3.0 Instrumentation

3.1 Veress Needle

Disposable and reusable Veress needles for creating a pneumoperitoneum are available (**Fig. 2**).

The Veress needle is used for creating the initial pneumoperitoneum. A trocar can be introduced safely because the distance of the abdominal wall from the organs is increased. The Veress needle technique is the most widely practiced method of access to the peritoneal cavity. The Veress needle comprises two components: an outer hollow needle with a sharp beveled edge, and an inner, spring-loaded, retractable blunt obturator with the stop position beyond the tip of the hollow needle. Once the peritoneal cavity is entered, the blunt obturator juts forward by the spring-force and protrudes beyond the tip of the hollow needle, thus preventing from iatrogenic visceral and vascular injuries.

The reusable type should be preferred to reduce the costs of laparoscopic surgery. Veress needles are available in three lengths: 80 mm, 100 mm, and 120 mm. In thin patients, with scaphoid abdomen, a 80 mm-Veress needle should be used. In obese patients, a 120 mm-Veress needle is preferred. Disposable needles do not require cleaning or sterilization procedures. The Veress needle must be kept in perfect condition to ensure that the mandrin slides easily into the protective sleeve. The surgeon must have full knowledge of all safety features of the mandrin. The Veress needle should be held between the thumb and the index finger during insertion. When the needle is inserted through the abdominal wall, passage through the fascia into the peritoneal cavity can be recognized as a tactile “popping” sensation (**Figs. 3, 4**).

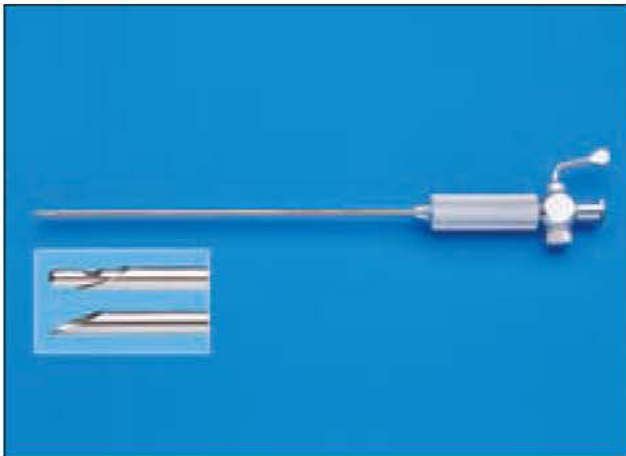

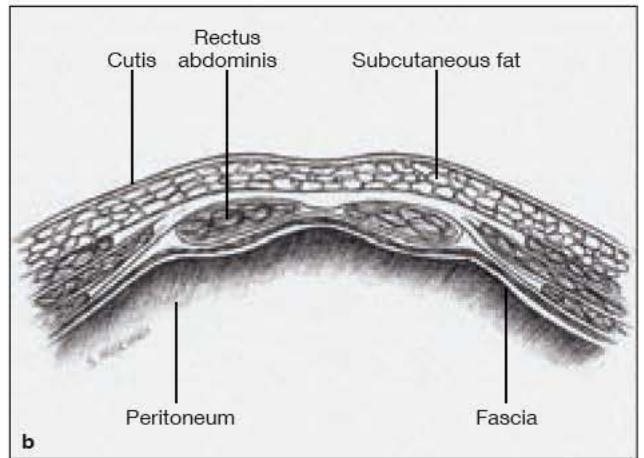
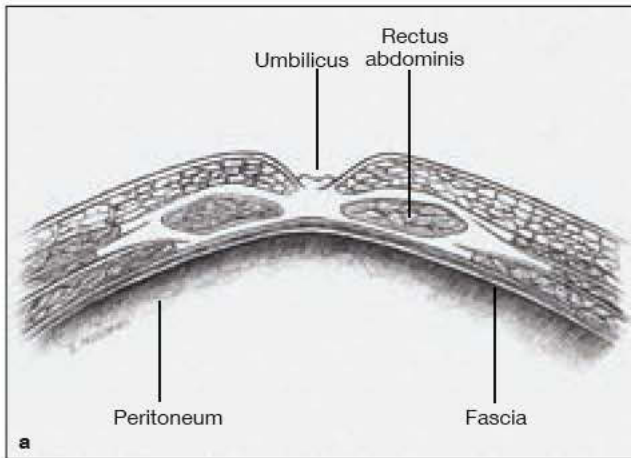
Fig. 2
Veress needle for creation of the pneumoperitoneum.

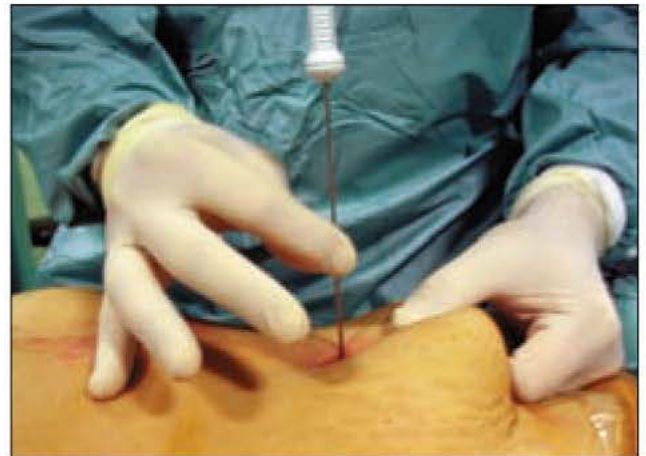

Fig. 3
Insertion of the Veress needle.

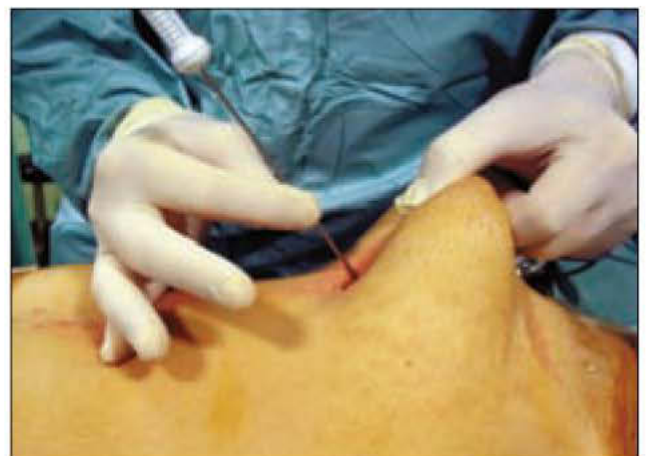

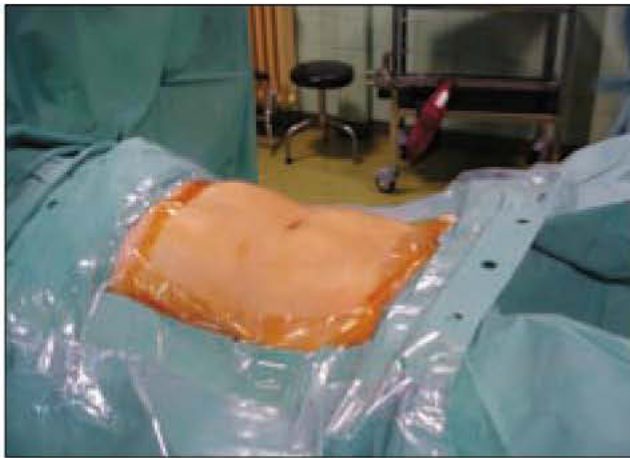Fig. 4
Entry of the Veress needle through the fascia into the peritoneal cavity is usually noticeable by a popping sensation when the resistance of the peritoneum is overcome.

**Figs. 5a, b**

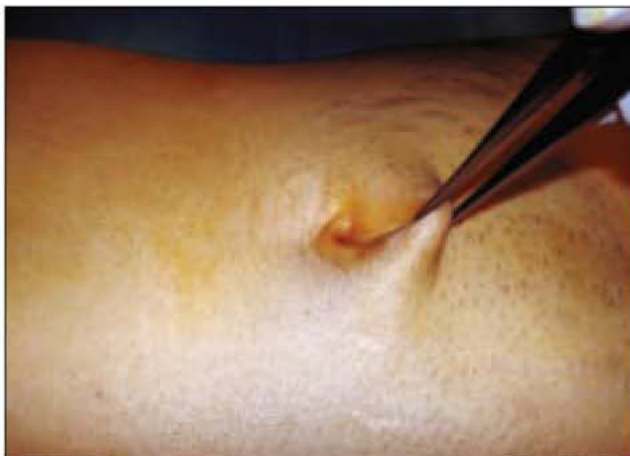The umbilical area is preferred for introducing the Veress needle.

**Fig. 6**

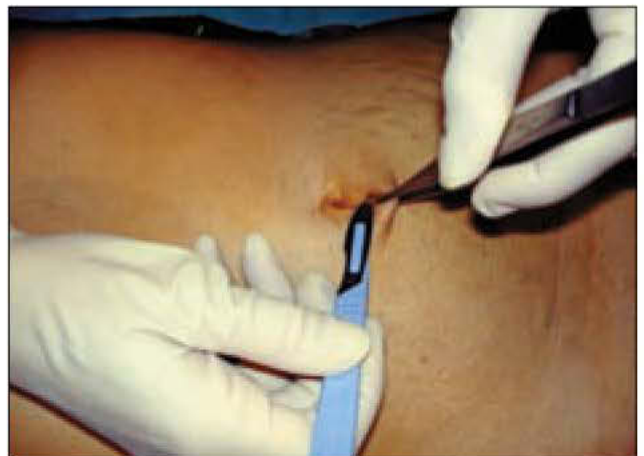Prior to laparoscopy the abdomen is prepared and draped to establish a sterile field.

The umbilical area is preferred for introducing the Veress needle, because the thickness of the subcutaneous and preperitoneal tissue layers in this area is reduced. In terms of cosmetic results, the umbilical fossa is capable of concealing the postoperative port-site scar (**Figs. 5a, b**).

Prior to laparoscopy, the abdomen is prepared and draped to establish a sterile field (**Fig. 6**). Before the Veress needle can be inserted, a transverse or vertical percutaneous incision is made large enough to accommodate the primary trocar. (**Figs. 7, 8**). The base of the umbilicus is the thinnest area of the abdominal wall making it the preferred site for insertion of the needle. To move the large vessels out of the way, it is advisable to elevate the abdominal wall during penetration by the needle. The abdominal wall may be lifted by hand or by grasping it with a forceps. The needle is inserted at an oblique angle toward the uterine fundus.

**Fig. 7**

The umbilicus is grasped with an atraumatic forceps.

**Fig. 8**

A transverse or vertical percutaneous incision is made.

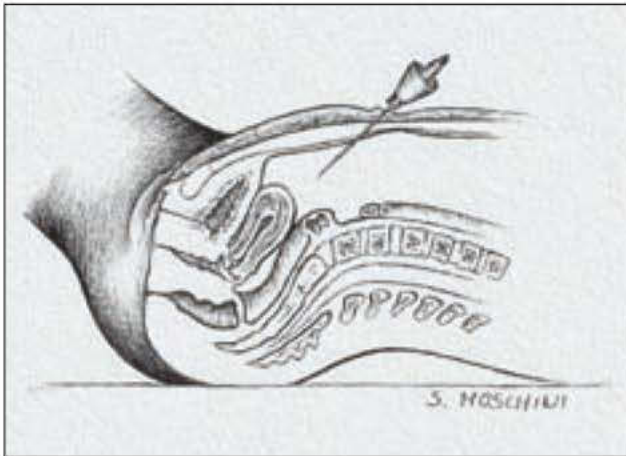


Fig. 9a
Non-obese patient; the needle is inserted with an oblique angle towards the uterine fundus.

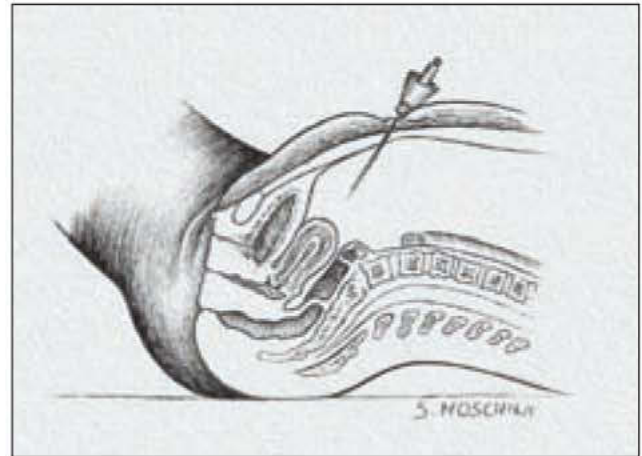


Fig. 9b
Overweight patient.

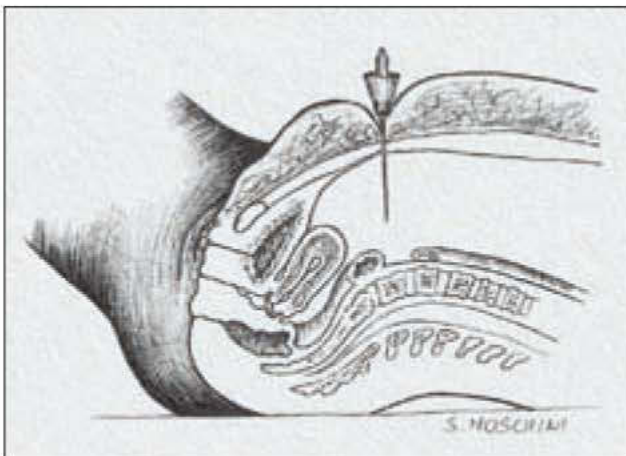


Fig. 9c
Obese patient.

Care must be taken not to angle the Veress needle laterally toward the iliac vessels. The insufflation stopcock of the needle must be opened to allow inflow of air as soon as the peritoneal cavity is entered by the tip of the needle (**Figs. 9a–c**). The negative pressure of the peritoneal cavity allows the underlying structures to fall away. Proper intraperitoneal placement of the Veress needle must always be confirmed.

3.1 Safety Tests

Irrigation and aspiration test: the most widely used safety test is performed with the aid of an empty syringe or one containing physiological saline (**Fig. 10**). It consists of three steps. The first step is aspiration, which must not produce air, liquid or pus, thereby ascertaining the absence of vascular, urinary or intestinal perforation. In the second step, 20 cc of air or fluid is injected. There should be no resistance felt, and fluid should not be able to be aspirated. It is an easy method of confirming that there is no contact with intra-abdominal viscera or adhesions. The third step is an attempt to reaspirate the injected air or liquid. Reaspiration must be impossible, confirming the proper intraperitoneal placement of the Veress needle. However, if the needle is in the pre-peritoneal space or in the muscle fiber above the rectus, the injected solution can be reaspirated. At the time of the aspiration test, if more fluid than previously injected becomes apparent, the surgeon should suspect either ascitis, urinary bladder perforation, or the presence of a cyst. In the presence of fecal material, perforation of the small or large bowel should be suspected. If blood is visible, then iatrogenic vessel injury may have occurred. If any fresh blood or fecal fluid is aspirated in the syringe, the surgeon should not remove the Veress needle, and emergency laparotomy is required. Leaving the Veress needle in position helps to localize the punctured area after laparotomy, and facilitates subsequent hemostasis.

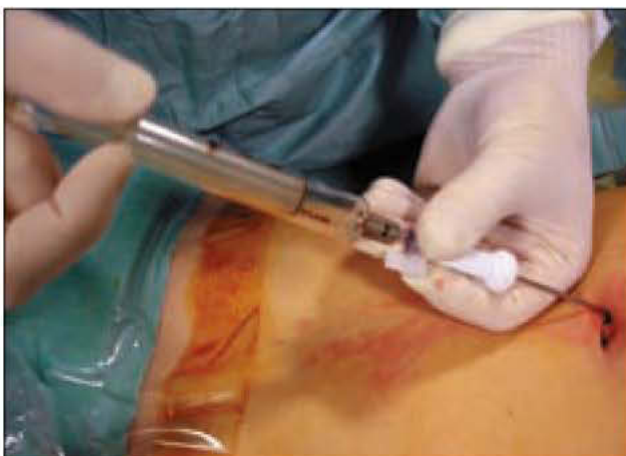

Fig. 10
Safety test to confirm the proper placement of the Veress needle.



Fig. 11
The intraabdominal insufflation pressure shown on the front panel of the ELECTRONIC ENDOFLATOR® is **inappropriate**.



Fig. 12
The front panel depicts the **correct** insufflation parameters allowing CO₂ insufflation to be continued.

Hanging drop test: a few drops of physiological saline should be poured over the Veress needle and the abdominal wall should be lifted slightly. If the tip of the Veress needle is inside the abdominal cavity the hanging drop should be drawn inside because of the abdomen's negative pressure. If needle point is anywhere else, the hanging drop test will be negative.

Gas insufflation test: the functional range of a modern electronic insufflator permits the proper placement of the Veress needle to be checked by use of the unit alone. For this purpose, the flow rate must be set to zero, and the insufflation pressure must be set to the chosen value. The unit is then activated and the actual pressure value is read. This reading must be negative or at least zero, confirming that the needle has been positioned correctly. Once this has been confirmed, the flow rate can be increased to approximately 2.5 liters per minute (**Figs. 11, 12**). Pressure values of less than 8 mmHg are compatible with intraperitoneal positioning of the needle. In the case of higher pressure or reflux of air or fluid, the needle should be repositioned rather than pressed forward. For safe access, the surgeon should meticulously monitor the four insufflation parameters at the time the pneumoperitoneum is established, i.e., **preset insufflation pressure, actual intraabdominal pressure, gas flow rate and total volume of gas inflow**. During insufflation, there should be a proportional rise in actual pressure value. For example, assuming only 400 to 500 ml of gas are administered, if the actual pressure is equal to a preset pressure of 12 mmHg, then the gas is not going into the free abdominal cavity. Rather, it may be located in the pre-peritoneal space,

inside the omentum, or in the bowel. On the other hand, if more than 5 L of gas is administered without any distension of the abdomen, this signals probable leakage. The abdomen needs to be checked for distension during insufflation. With more experience, the surgeon will immediately realize if there is any error by constantly monitoring these four insufflation parameters.

Alternative sites for Veress needle insertion are: the left upper quadrant, left iliac fossa outside the rectus muscle, and the posterior pouch of Douglas. For the left upper quadrant, a line is drawn from the mid-clavicular point to 2 cm below the left costal margin. After vertical insertion of the Veress needle, routine checks are made. Insertion into the left iliac fossa must be performed outside the rectus muscle of the abdomen to avoid injury to the epigastric vessels. Insertion in the pouch of Douglas is relatively simple. After lifting the cervix with a tenaculum forceps, the needle is inserted 1 cm inferior to the cervico-vaginal junction. Because the tissue in this area is very thin (less than 1.5 cm), insertion is usually accomplished easily. A safety test must be performed before establishing the pneumoperitoneum. In some instances, the Veress needle can also be inserted by transfixing the uterine fundus. In this case, after application of a tenaculum forceps and measurement of the uterine cavity by use of a palpation probe, the needle is passed through the cervix, the cervical canal, the endometrial cavity and the uterine fundus into the peritoneal cavity. This approach is contraindicated in cases of infertility, previous myomectomy, and tentative diagnosis of endometriosis of the pouch of Douglas.



Fig. 13
The CO₂ insufflation unit ELECTRONIC ENDOFLATOR®, (KARL STORZ Tuttlingen, Germany).



Fig. 14
The CO₂ insufflation unit THERMOFLATOR® with integrated CO₂ heating, filtering, and humidifying system (KARL STORZ Tuttlingen, Germany).

4.0 Units

4.1 Electronic CO₂ Endoflator

The electronic CO₂ endoflator is an insufflation unit used for delivering carbon dioxide to the peritoneal cavity in laparoscopic operations (**Fig. 13**). The main technical features include the unit's capability to insufflate up to 15–20 L/min. (THERMOFLATOR max. 30 L/min.) and to maintain a constant intra-abdominal pressure without exceeding the safety limit of 12–16 mmHg. Continuous control of intra-abdominal pressure helps prevent complications related to an incorrectly positioned Veress needle (pre-peritoneal emphysema, or puncture of the omentum, bowel and vessels). Patient safety is ensured by optical and acoustic alarms as well as several mutually independent safety circuits. The set-point values for pressure and flow rate can be preadjusted exactly using jog keys and digital displays. For safety reasons it is mandatory that the user have a sound understanding of the functions and quadro-manometric insufflation parameters. These four insufflation parameters are: **preset insufflation pressure, actual intraabdominal pressure, gas flow rate and total volume of gas inflow.**

The *preset insufflation pressure* is adjusted by the surgeon before starting insufflation. It should be approximately 12–14 mmHg without exceeding 18–20 mmHg. Microprocessor-controlled insufflators automatically maintain intra-abdominal pressure at the preset value. Whenever intra-abdominal pressure decreases due to gas leakage to the outside, inflow of gas will be increased to keep the intra-abdominal pressure at the preset level. If intra-abdominal pressure increases due to external pressure, the insufflator removes some gas from the abdominal cavity to again maintain the preset pressure.

Actual pressure is the *actual intra-abdominal pressure* measured by the insufflator. When the Veress needle is attached, there is a degree of error in the actual pressure reading because of resistance of gas flow through the small lumen of the Veress needle. Because the continuous flow of insufflating gas through the Veress needle usually gives an extra 4 to 8 mmHg of measured pressure by the insufflator,

the true intra-abdominal pressure can actually be determined by switching off the insufflator flow for a moment. Many good quality microprocessor-controlled insufflators deliver a pulsatile flow of gas when the Veress needle is connected, in which the low reading of actual pressure measures the true intra-abdominal pressure. Actual pressure should not exceed 25 mmHg because this can result in compression of the inferior vena cava which compromises venous return to the heart and entails an increased risk of deep vein thrombosis and reduced cardiac output. There is an elevated risk of air embolism due to venous intravasation and an increased incidence rate for surgical emphysema.

The flow rate reflects the flow of CO₂ through the insufflator tubing. When the Veress needle is attached, the flow rate should be adjusted to 1–2 liters per minute. The Veress needle may be inadvertently inserted into a vessel. But if the flow rate is low, there is less chance of serious complication. Once the initial pneumoperitoneum has been established and the cannula is inside the abdominal cavity, the flow rate can be set to maximum to compensate for loss of CO₂ caused by intraoperative use of suction-irrigation cannulas. It is important to bear in mind that if the insufflator is set to its maximum flow rate, then it will allow flow only if the actual pressure is less than the preset pressure. Otherwise, it will not pump any gas. Some surgeons limit the initial flow rate with the Veress needle to 1 liter per minute. As soon as it is confirmed, that gas delivery to the abdominal cavity is working appropriately (percussion examination and seeing obliteration of liver dullness), the flow rate can be increased. Normal caliber Veress needles can deliver CO₂ flow at a maximum of 2.5 liters per minute. With a CO₂ flow rate of more than 7 liters per minute delivered through the cannula inside the abdominal cavity, there is always a risk of hypothermia to the patient. The latest generation of insufflators has a gas heating, filtering, and humidifying system offering the following benefits compared to standard insufflation devices: patients maintain a warmer core body temperature; fogging of the distal lens



Fig. 15
Reusable sharp trocar with pyramidal tip.

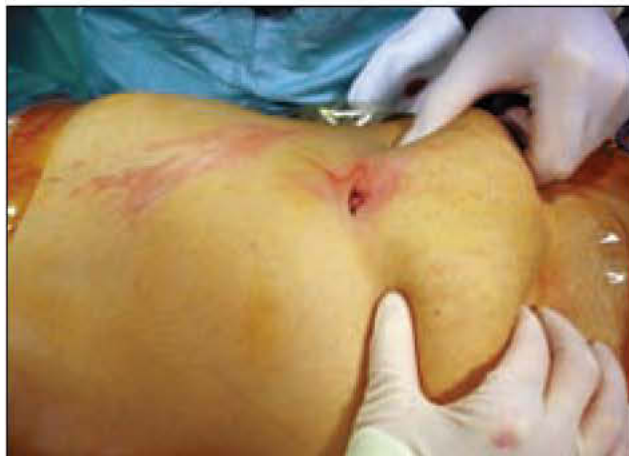

Fig. 16
Before proceeding with the primary trocar placement, the abdominal wall is lifted.

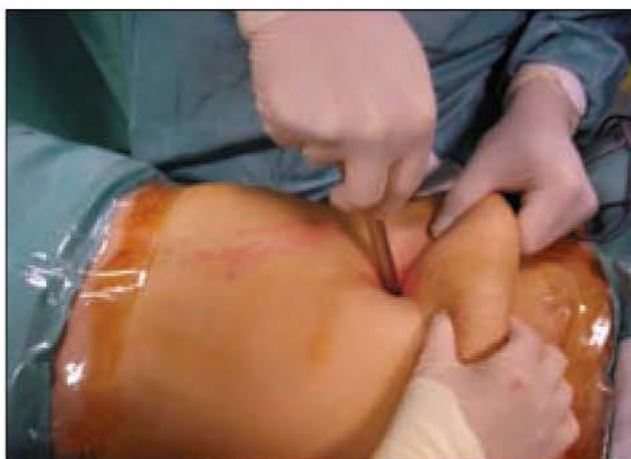

Fig. 17
Insertion of the umbilical trocar.

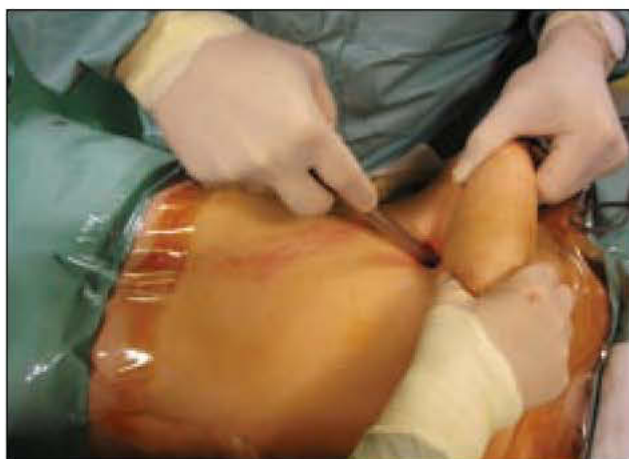

Fig. 18
The tip of the trocar is passed through the fascia.

is reduced; less postoperative pain. Such a system is indispensable if a flow rate of up to 30 liters per minute is used (**Fig. 14**).

The total volume of insufflated gas is the fourth parameter. In a normal-sized human abdominal cavity 4–5 liters of CO₂ are required to create an intra-abdominal actual pressure of 12 mmHg. In some large-sized abdominal cavities and in

multipara patients, delivery of 6–7 liters of CO₂ (rarely 8 to 9 liters) is occasionally required to attain the desired pressure of 12 mmHg. Whenever there is less or more amount of gas used to inflate a normal abdominal cavity, the operating surgeon should suspect some error related to pneumoperitoneum technique, such as creation of a pre-peritoneal space or extravasation of gas.

5.0 Trocars

Trocars permit access to the intraperitoneal cavity (**Figs. 15, 16**). The primary trocar accommodating the laparoscope is usually introduced via the umbilicus. It can be introduced blindly after creating the pneumoperitoneum by use of the Veress needle (closed access). In this case, it is recommended that the peritoneum be created by insufflating up to an intra-abdominal pressure of 15 mmHg. This keeps the vessels out of the way, while avoiding dimpling of the abdominal wall

during trocar insertion. At this point, removal of the Veress needle is followed by primary trocar insertion. When passing through the fascia and protruding into the abdominal cavity, the surgeon should have the typical tactile sensation. Correct trocar insertion depends on correct superficial incision, trocar axis and correct intra-abdominal pressure. In some patients, it can be useful to lift the abdominal wall by hand or with an Allis forceps (**Figs. 17–19**). After insertion, the position of the

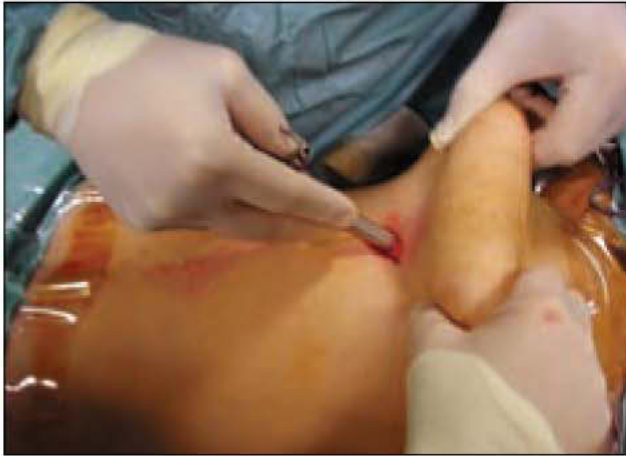

Fig. 19
Passage of the trocar through the peritoneum into the peritoneal cavity.

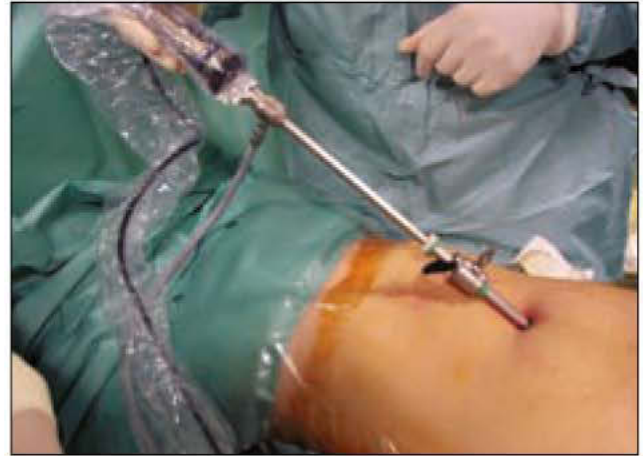

Fig. 20
The operating laparoscope fitted with a video camera is inserted to assess the successful placement of the primary trocar.

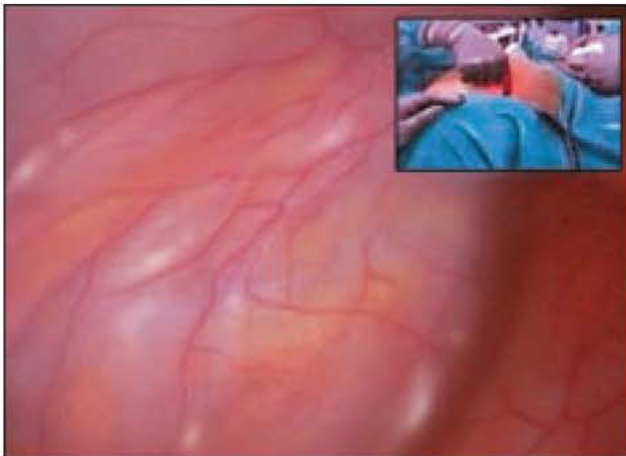


Fig. 21
Placement of an accessory trocar. To avoid injuries to epigastric vessels, the site of trocar entry should be checked by digital palpation and transillumination of the abdominal wall.

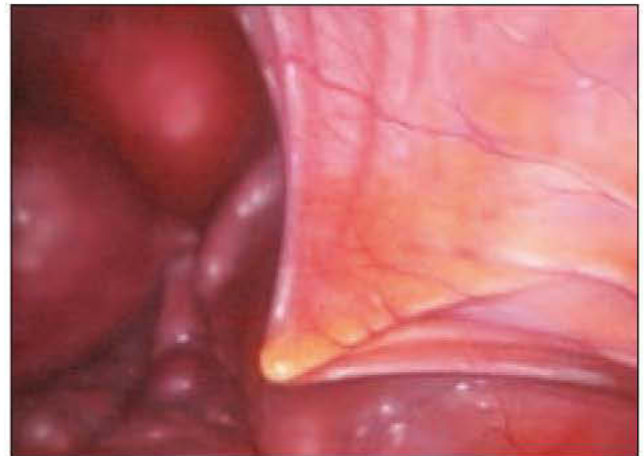


Fig. 22
Placement of an accessory trocar under laparoscopic control.

trocar must be confirmed by introducing the laparoscope and inspecting the pelvic cavity (**Fig. 20**). Direct trocar insertion without pneumoperitoneum is reported to be safe, with no more complications than those associated with the conventional technique. This method for creating the primary laparoscopic port is usually applied by gynecologists in the case of laparoscopic-guided sterilization procedures.

Trocars should be held safely and comfortably in the surgeon's dominant hand so that the proximal end of the trocar should rest on the thenar eminence, the middle finger should rest over the gas inlet with the index finger pointing towards the sharp tip of the trocar. Applying controlled, constant force, the trocar is advanced through the abdominal wall using a slight twisting motion. The main axis of trocar insertion must be in cranio-caudal direction, the angle of inclination relative to the perpendicular ranging between 30° and 45°.

The size of the primary trocar must be adapted to the diameter of the laparoscope to be inserted. The size of

the accessory trocars must also be adapted to the instruments selected. Prior to the insertion of accessory trocars, the patient is placed in the Trendelenburg position and the trocars are introduced under visual control. The number, size and position of accessory trocars are predetermined by the type of surgery. To avoid iatrogenic injuries to epigastric vessels, the site of trocar entry should be checked by digital palpation and transillumination of the abdominal wall (**Figs. 21, 22**). It is very important that trocars be equipped with a retention mechanism to prevent inadvertent slippage or dislocation of cannulas during surgical maneuvers or when changing instruments. Reusable metal cannulas are equipped with leaflet valves that can be opened manually when introducing or removing an instrument. In this way damage to delicate instruments like the distal endoscope tip or blunting of sharp instruments (e.g., scissors) can be prevented. To prevent leakage of CO₂ while operating with a 5 mm-instrument through a 10 mm-trocar, the use of a specific cannula reducer with automatic valve is required.

Trocars are available with various tip designs: the conical tip, pyramidal tip, and blunt tip (**Fig. 23**). These are chosen depending on the surgeons experience and preferences.

Fig. 23
 ① Trocar with pyramidal tip
 ② Trocar with conical tip
 ③ Trocar with blunt tip

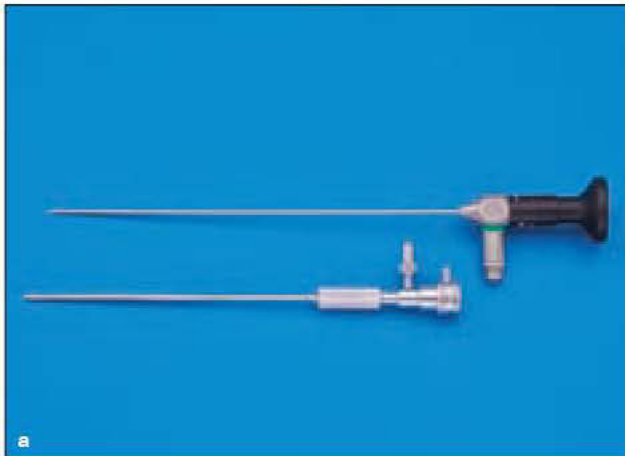

Fig. 24a
 The working channel of an optical Veress needle is large enough to accommodate the shaft of a miniature endoscope.

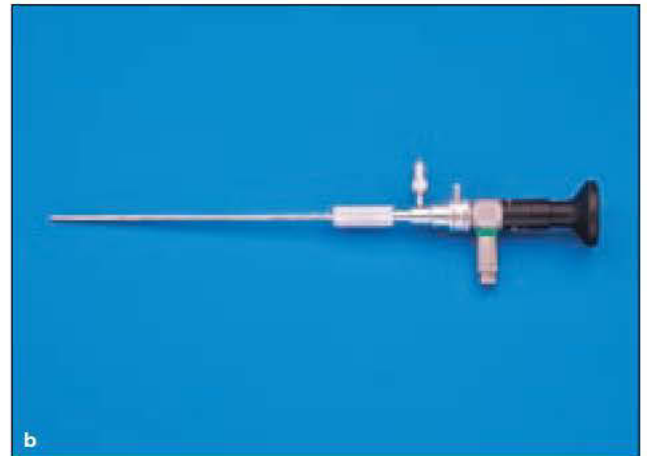

Fig. 24b
 The miniature endoscope inserted in the optical Veress needle.

When extensive intraabdominal or pelvic adhesions are suspected particular attention must be paid to the site of trocar insertion. In these cases, a miniature endoscope can be used through the working channel of an optical Veress needle prior to creating the pneumoperitoneum and inserting the primary trocar. The needle is inserted using the technique described above. Before starting insufflation, correct placement of the needle is confirmed by means of the miniature endoscope. Once the pneumoperitoneum has been induced, the same endoscope will be used for visually controlled insertion of the primary trocar (**Figs. 24a, b**).

An alternative technique is the visually controlled entry. The technique commonly involves the use of a reusable visual 11 mm-cannula system, and a 0°-endoscope that provides direct visualization of the entry tract and may be chosen for creation of the pneumoperitoneum in patients with a previously scarred abdomen. To name only a few of the devices available on the market, such as TERNAMIAN EndoTIP™ trocars (Endoscopic Threaded Imaging Port) and Visiport or Optiview visual trocars.

The EndoTIP™ trocar is inserted under endoscopic guidance via a small incision without prior creation of a pneumoperitoneum. By applying clockwise rotation the EndoTIP™ trocar is slowly inserted through the various tissue layers. The Visiport optical trocar cuts through the tissue planes with a blade at the tip. This can be visually controlled via an endoscope inserted through the trocar. All visual trocars have in common, that they can reduce the risk of injury to intra-abdominal organs given proper application by an experienced surgeon (Figs. 25, 26).



Fig. 25
TERNAMIAN EndoTIP™ Trocar (KARL STORZ Tuttlingen, Germany).

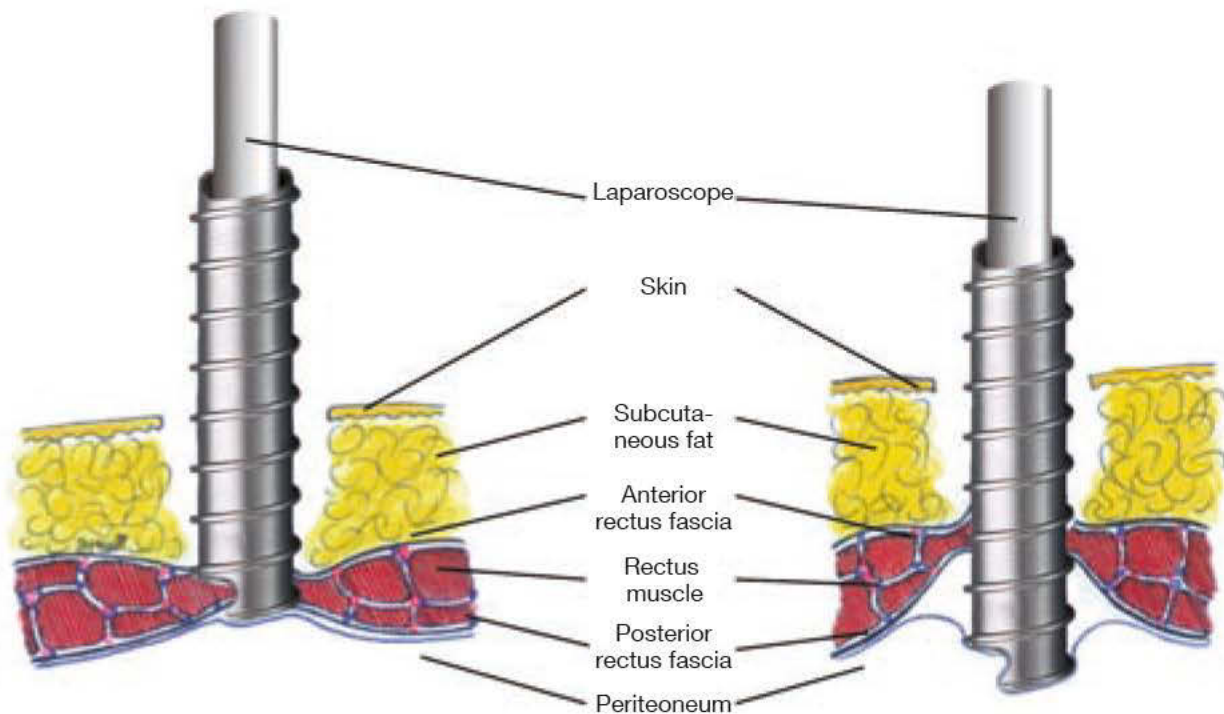
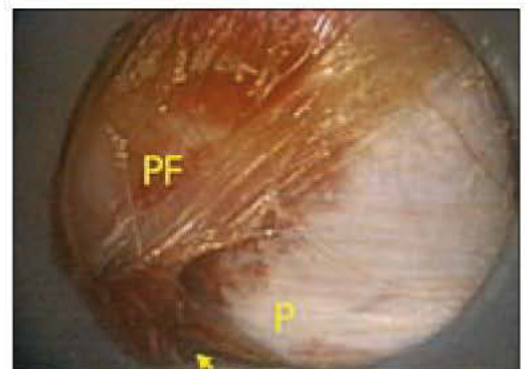

Fig. 26

The schematic drawing illustrates the major benefits of the TERNAMIAN EndoTIP™ Cannula System:

- The tissue is not cut through as it is when punctured with a conventional trocar, but is merely displaced. The integrity of the fasciae is preserved, and therefore, that of the fascial closure mechanism.
- The TERNAMIAN EndoTIP™ System contains neither sharp points nor a cutting trocar which eliminates the risk of inadvertent injuries to the patient.
- Since the TERNAMIAN EndoTIP™ System is not pushed into the peritoneum by applying pressure, but is introduced by controlled rotation, injuries to organs or vessels caused by uncontrolled penetration of the abdominal wall are virtually impossible.



Through rotating movements the posterior rectus fascia (PF) is lifted and advances the cannula to the pre-peritoneal space (P).

6.0 Endoscopes

A state-of-the-art endoscope must produce images of concealed body cavities and meet the highest demands in terms of brightness, depth of focus, magnification, contrast and resolution. The major cornerstone for optimal image transmission in endoscopy was laid by the introduction of the rod-lens system by Professor *Harold H. Hopkins*. Recognizing the significance of Prof. Hopkins invention, the instrument manufacturer KARL STORZ signed a licensing agreement with him in 1965 that founded a long-standing successful collaboration. The combination of rod-shaped biconvex lenses with meniscus lenses delivers, first of all, superior image brightness, and second, a sufficiently good compensation for image errors such as astigmatisms and image field curvature that disturb image transmission systems. The HOPKINS® rod-lens system provides substantial advantages compared to a conventional lens system: improved resolution and contrast, large angle of vision, extremely clear and highly realistic images that permit to identify the smallest details on

the surface of internal organs. It has been subject to continual further improvement and yet remains the undisputed gold standard in the field of medical imaging technology.

Endoscopes are available in various diameters and lengths (**Fig. 27**). Miniaturized telescopes should generally be used for diagnostic laparoscopy, with the intent of being less invasive for the patient. For micro laparoscopy a 1.2 mm-telescope can be introduced directly through the Veress needle. To meet the demands of gynecological endoscopy the basic equipment must comprise a powerful cold light source and endoscopes that are capable of providing high quality close-up views of the organs. An optical Veress needle is recommended in patients with suspected or known adhesions or history or presence of umbilical hernia. 5 mm-telescopes may also be used for simple diagnostic laparoscopy. For operative laparoscopy, 10 mm-laparoscopes are preferred because they offer sharp and highly detailed images both in panoramic and close-up view.



Fig. 27
Various types of laparoscopes.




Fig. 28
HOPKINS® rod-lens laparoscopes are available with different angles of view.

The straight forward laparoscope with 0° angle of view is generally preferred by gynecologists, who always work in the pelvic region (**Fig. 28**). The 30° forward-oblique laparoscope permits far greater latitude for viewing underlying areas in the case of difficult anatomical conditions. Flexible fiberscopes allow the angle of vision to be adjusted by active deflection of the distal tip according to the individual anatomical situation or the needs of the intervention; they are used more frequently in the digestive tract or for tumor surgery. The

major drawbacks of minimally invasive surgery are loss of depth perception, reduced tactile feedback and deficiencies in eye-hand coordination. These days, most of the surgeons work on the basis of virtual 2D-video images via the monitor screen. Undoubtedly, 3D-visualization of the operative field still remains one of the greatest challenges. Specific research and development efforts should be intensified to further improve the technology in terms of depth of perception, quality of stereoscopic vision and ergonomics.

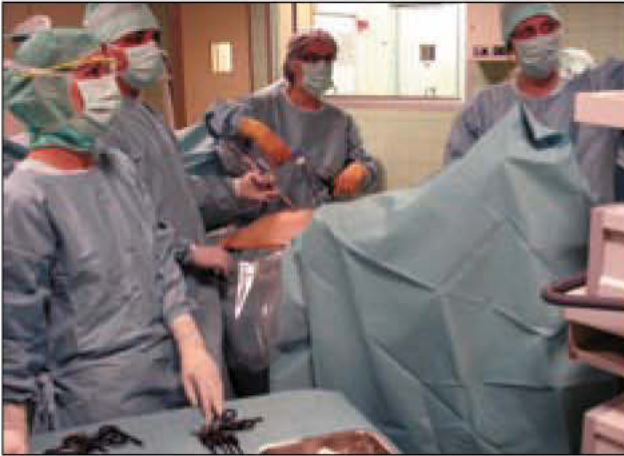

Fig. 29
Correct positioning of the laparoscopic team in the OR.

7.0 Videoendoscopy

In modern laparoscopy, a high quality video camera should always be used. Surgeons must be adequately trained until they are proficient with the techniques of video laparoscopy usually performed in a comfortable standing position while watching the video screen (**Fig. 29**). There are various types of video cameras available on the market. The technical criteria of a good video camera are: resolution (number of lines or pixels), sensitivity (lux), number and quality of video output ports. Finally, a high signal-to-noise ratio (SNR) can be associated with focal interference patterns that adversely affect image quality in extreme situations, i.e., in the case of bleeding and in critical lighting conditions.

The video camera used in laparoscopy usually needs to be focused prior to insertion into the abdominal cavity. At the time of focusing it should be placed at a distance of approximately 5 cm away from the target area. This is the average distance most frequently used during laparoscopic surgery. White balance calibration of the video camera needs to be performed prior to starting the surgical procedure and placing the laparoscope (with mounted video camera) in the primary port. The usual method is to direct the laparoscope tip at a white object and trigger the automatic white balance mode, either via the front panel or the push-button on the camera head. The white object is taken as a source of reference to adjust the camera to the primary colors (Red, Green, Blue; RGB). The additive combination of the three primary colors in equal intensities produces white.

The core component of a video camera is the CCD sensor, a solid-state chip embedded with a series of tiny, light-sensitive photosites capable of producing varying amounts of charge in response to the quantity of incident light. Laparoscopic video cameras are typically available in a one-chip or three-chip configuration. In one-chip video cameras the three primary colours are captured by a single chip (**Fig. 30**). In three-chip cameras a beam splitter separates the light into the three primary colors. In this way, each color is captured by a separate chip. Any color can be produced by a simple additive mixture of the correct proportions of red, green, and blue light. Three-chip video cameras have a very high resolution and provide superior image quality (**Fig. 31**).

In 2002 the first generation of pure digital image camera systems, such as **IMAGE1™** were introduced to the market. Ranking among the first medical-grade video camera systems with digital source sampling technology (DSS), the **IMAGE1™** camera system instantly converts optical images to digital at the CCD sensing chip. Owing to its all-digital circuitry across the entire imaging chain the **IMAGE1™** camera system delivers high-resolution video images of excellent quality, accurate color rendition and contrast. This innovative technology has laid the foundation for further development and integration of HD-compatible components (**Fig. 32**). Additional information on this highly topical issue will be given below. The CCD sensor of the standard **IMAGE1™** 3-chip camera head captures 752 x 582 pixels per chip. Camera functions are programmable via the camera head buttons.

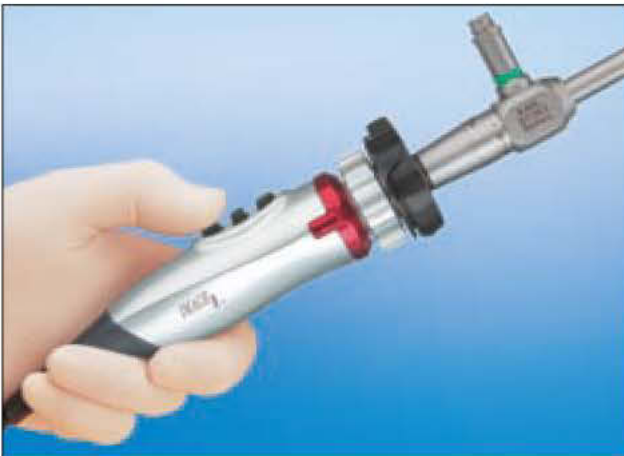

Fig. 30
The autoclavable **IMAGE1™ A1™** one-chip video camera (KARL STORZ Tuttlingen, Germany).

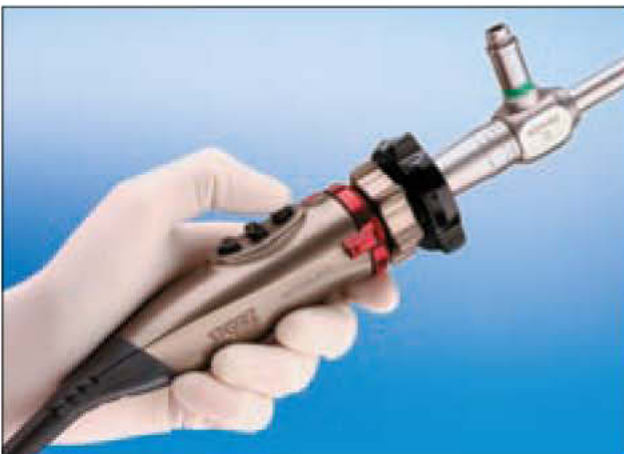

Fig. 31
The autoclavable **IMAGE1™ A1™** three-chip video camera (KARL STORZ Tuttlingen, Germany).

There is an increasing need for recording and storage of digital data generated during videoendoscopic-guided surgery. Digital still images, video and audio files of the major steps of a surgical procedure are used for consultation, review and medicolegal purposes. Besides, they can provide a powerful tool in educating surgeons and students about new and developing procedures. Digital technology has already replaced many classical documentation methods, such as making hardcopy prints with a video color printer (Fig. 33). Telemedicine permits rapid access to remote medical expertise by means of telecommunication and information technologies. With the development of the integrated operating room, digital data archiving and global computer-based communication technologies can be used for various purposes, thus enhancing the real-time multidisciplinary exchange of scientific information including remote diagnosis and therapy as well as remote education and training.

The Advanced Image and Data Archiving System (KARL STORZ AIDA® compact NEO) allows the efficient and convenient digital storage of all patient-related text, audio and image data including video sequences. Intraoperatively acquired data can be efficiently archived on DVD, CD-ROM, USB stick or on the network. Optional connection to the HIS and PACS optimizes fast access to patient and image data. Digitally stored images can be processed and can be integrated into a referring report or scientific documentation (Fig. 34).

High-definition video technology is gaining widespread use in the consumer segment and bears the potential of improving the quality of videoendoscopic imaging and documentation. In response to the major leap forward in high-definition imaging technology, one of the world's leading manufacturers of medical devices has developed a video platform that allows step-by-step integration of HD visualization components and image management systems into the operating room imaging chain: The new HD video platform IMAGE1™ hub (KARL STORZ Tuttlingen, Germany) with its inherent resolution of 1920 x 1080 pixels offers images of superior quality that allow the user to distinguish even the finest tissue structures including the vascular capillary network. As compared to the standard image resolution of the current PAL system, the IMAGE1™ HD platform is capable of delivering five times more image information per second.



Fig. 33
Video color printer.



Fig. 32
The IMAGE1™ H3-Z 3-chip high-definition camera head attached to a laparoscope. In the background, the IMAGE1™ HD hub camera control unit (KARL STORZ Tuttlingen, Germany).

Optimal vision is of paramount importance to the successful outcome of any surgery. The world's largest 23" flat screen LCD video monitor is ideally suited to meet this demand. The 16:9 widescreen display improves anatomical orientation under difficult-situs conditions in that it provides an extended peripheral view compared to the standard 4:3 aspect ratio. In this way, visualization of the more lateral aspects of the image is enhanced, which facilitates instrument handling and precise positioning (Fig. 35a). Images acquired through HD video endoscopy are capable of emulating 3D views because

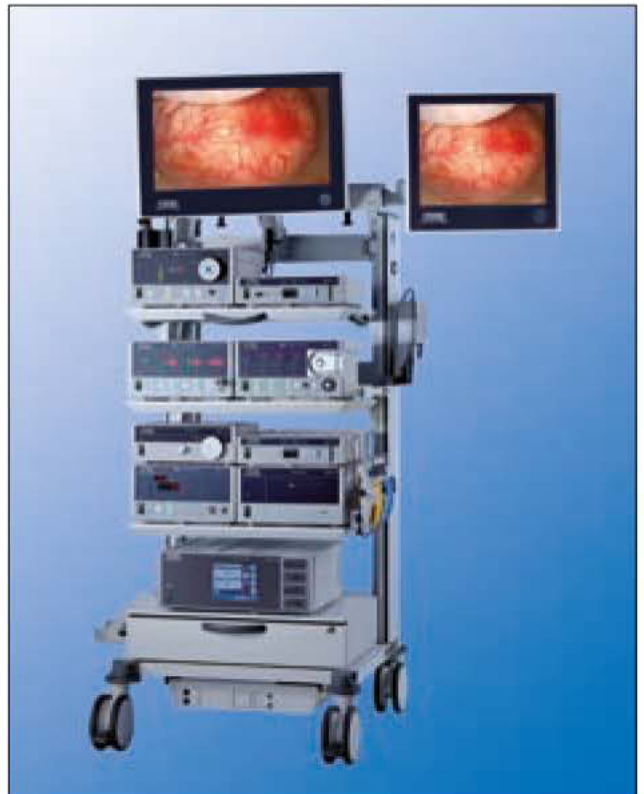

Fig. 34
Fully equipped videocart with the KARL STORZ AIDA® compact NEO system.

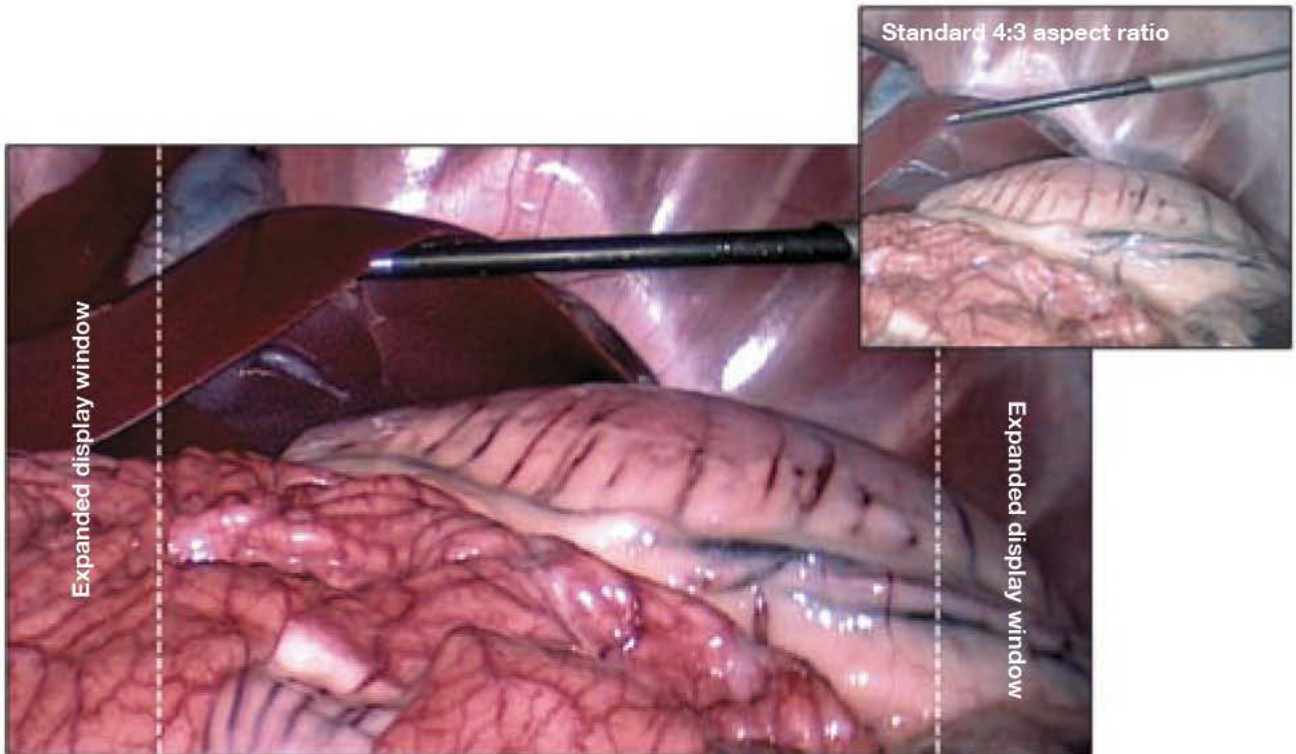


Fig. 35a
The 16:9 aspect ratio improves peripheral vision, image definition and color brilliance.



Fig. 35b
Interlaced scan (half-frame) displays 25/30* frames per second.

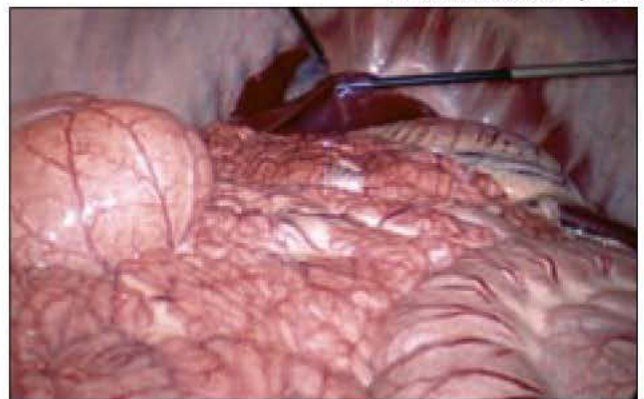


Fig. 35c
Progressive scan (full frame) displays 50/60* full frames per second.

* PAL / NTSC color system

they provide a higher depth perception and color contrast that help surgeons better differentiate anatomical planes. Structures that are normally invisible on standard definition images become more distinguishable and can be recognized more easily. Due to the short response times of the LCD elements used in the newest generation of HD flat screen monitors a steady stream of crisp clear images is delivered so that even fast-moving objects are displayed without motion lag, ghosting or other artefacts, commonly experienced with standard display technologies.

The KARL STORZ IMAGE1™ HD hub platform uses 1080p technology, which is currently the highest-resolution format for broadcasting and distribution of video content. The 1080p (“p” stands for “progressive scan”) video mode of the IMAGE1™ H3 video camera delivers double the amount

of image information at 50 Hz (frame rate) as compared to systems that use the 1080i video mode (“i” stands for “interlaced”) (Figs. 35b, c).

In contrast to the 1920 x 1080 progressive scanning mode, the interlaced mode completes the scan process only for every second line at a frame rate of 50 / 60 Hz, which is why two complete scans are required in the interlaced scanning mode to display the entire image. Progressive scanning technology not only creates images of superior quality but is of added value in terms of data storage.

The image acquisition and display standard of the IMAGE1™ HD hub platform involves the use of the high-definition IMAGE1™ H3 three-chip video camera which offers the major advantage of a more natural color performance for brilliant, high-contrast images of almost three-dimensional appearance.

8.0 Video Monitor

In the past, endoscopic procedures were performed without the aid of video monitors. The operating surgeon visualized the interiors of the patient only by direct observation via the endoscope eyepiece. This method was associated with many drawbacks, such as the use of monocular vision, lack of appropriate real-time assistance, poor magnification properties and a limited range of feasible procedures that produced equally good, or even better results as compared to the standard approach. The introduction of television and the advent of information technology that propelled the development of medical imaging systems have, not at least, had a considerable impact on laparoscopic surgery. These are just a few of the benefits that have boosted the development of laparoscopic instruments and surgical techniques: improved magnification properties, real-time interaction between the operating surgeon and other members of the surgical team, binocular vision that permits highly complex procedures to be performed.

Surgical monitors operate on the principle of electronic horizontal linear scanning (**Fig. 36**). Each picture frame consists of a given number of lines, depending on the type of system used. The world is currently divided into three main analogue television broadcasting standards: **PAL**, **SECAM** and **NTSC**. NTSC (National Television System Committee), with 525 lines of resolution, is the analog television system used in the United States, Canada, Japan and some other countries. In most countries of central Europe except for France, the PAL (**Phase Alternation Line**) system is in use.

The French system is called SECAM (**Séquentiel Couleur à Mémoire**). Both the PAL and SECAM television systems

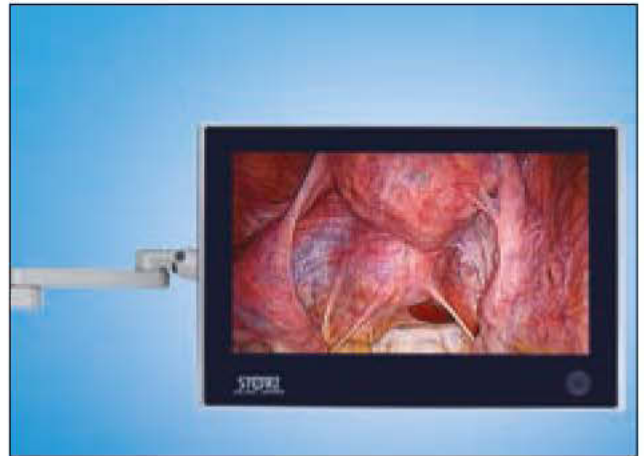

Fig. 36
Flat screen high-definition (HD) video monitor **WideView™ HD**, (KARL STORZ Tuttlingen, Germany).

operate at 625 lines of resolution. The final image depends upon the number of lines of resolution, scanning lines and pixels. How many black and white lines a system can differentiate is expressed by the lines of resolution. These can be horizontal or vertical. Horizontal resolution is defined by the number of horizontal elements that can be reproduced on the monitor, sometimes mixed up with the number of vertical lines. The term “pixel” denotes the number of picture elements that account for image definition. Briefly spoken, the higher the pixel count / resolution, the better the image quality.

9.0 Cold Light Source and Cold Light Cable

Minimally invasive surgery in general, and video laparoscopy in particular, require that an adequate level of illumination be maintained at the operating field throughout the procedure to make sure that the surgical team can clearly visualize anatomical structures and control the delicate movements of instruments. The quality level of a cold light source is determined by the quantity of light available at each step of the electrooptical system. The luminous efficacy of a lamp is the quotient of the total luminous flux emitted (light output) divided by the total lamp power input. However, increasing the power causes a real problem with regard to the generation of heat. At present, the technical improvements made to video cameras means that it is possible to return to reasonable power levels. 175–250 watts are generally sufficient for routine endoscopic procedures. For special applications, or when using miniature telescopes, a cold light source of 300 watts is recommended to maintain a sufficient level of illumination in the abdominal cavities. This applies all the more in view of the fact that even minor bleeding may cause impaired vision due to significant light absorption (**Fig. 37**).

A typical light source comprises a lamp, a heat filter, a condensing lens and manual or automatic intensity control circuit. The type of lamp is the most important component of the light source because it determines the quality of light. The two most frequently used types of lamps are halogen and xenon. The light emitted by a xenon lamp is more natural compared with a halogen lamp. Halogen bulbs are low voltage and have an average life cycle of 50 hours. These lamps are inexpensive and can be used for laparoscopic surgery if a low-budget setup is required. Xenon lamps consist of a spherical or ellipsoidal envelope made of quartz glass, which can withstand high thermal loads and high internal pressure. For ultimate image quality, only the highest-grade of clear fused silica quartz is used. It is typically doped, though not visible to the human eye, to absorb harmful UV radiation generated during use. Xenon light sources yield the best results.

Proper white balance calibration before the start of an operation is a very good practice for obtaining a natural color. White light is composed of equal proportions of red, blue, and green color. At the time of white balance calibration, the camera default setting is defined for the primary colors to equal proportions, assuming that the target is white (**Fig. 38**).

In a cold light source an infrared filter or reflector is used to remove the heat-producing infrared energy from the light beam before it is transmitted through the fiber optic light cable. By reflecting the infrared spectral range of the white light, the emission of thermal energy can be minimized but not reduced to zero. Moreover, a certain degree of thermal energy is dissipated during light transmission along the fiber optic cable and the endoscope to which it is connected. There are reports on accidents caused by fiber optic light cables, that were inadvertently left on the drape or on the patient's skin while the cold light source was still switched on. It is therefore

essential to test the equipment, particularly if assemblies including components from different manufacturers are used.

Medical-grade fiber optic light cables consist of fiber glass bundles, with a diameter between 3.5 mm and 6 mm, and a length ranging from 180 cm to 350 cm (**Fig. 39**). For general laparoscopy, a 5 mm diameter fiber optic light cable with a length of 240 cm should be selected. These cables are made up of optical fiber bundles that are swaged at both ends. The core is surrounded by a cladding layer which allows the propagation of light by total internal reflection. The outer diameter of a glass fiber, not that of the coating, is 125 μm . Fiber optic light cables are commonly used in laparoscopic procedures because of their high-quality optical transmission properties, however the major drawback of glass fibers seems to be their relative fragility. In fact, improper handling of fiber optic light cables can cause the fibers to crack over time.



Fig. 37
Cold light source XENON 300 (KARL STORZ Tuttlingen, Germany).

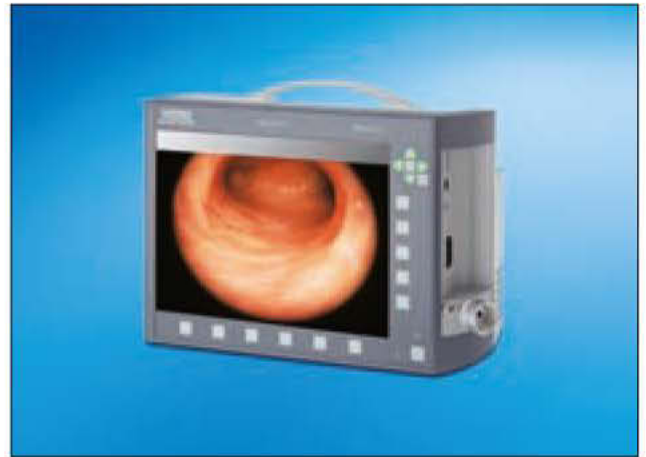

Fig. 38
The mobile compact unit **TELE PACK X** is a multifunctional system with integrated cold light source, camera control unit, documentation module, keyboard, flat screen monitor and camera head (KARL STORZ Tuttlingen, Germany).

Fluid light cables are made up of a sheath filled with a clear fluid (liquid-crystal gel). Theoretically, they are capable of transmitting 30% more light than fiber optic light cables. Owing to increased light efficacy and better color temperature transmission, this type of cable is recommended in those circumstances where special emphasis is placed on documentation. The disadvantages are that the quartz swaging at the ends is extremely fragile, and the fluid cables transmit more heat and are less flexible than the fiberoptic counterparts.

The durability of fiber optic light cables is highly dependent on proper maintenance. They should be handled carefully, and twisting should be avoided. After completion of the operation, the cable preferably should be disconnected from the endoscope and then again connected to the cold light source. Most cold light sources currently available have a special plug for holding the cable until it cools down.



Fig. 39
Fiber optic light cable.

10.0 Forceps and Scissors

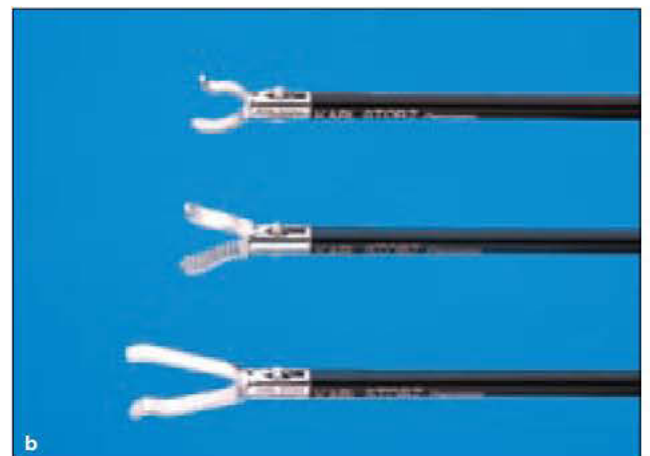A set of ergonomic instruments that meet the anatomical conditions and specific requirements of the procedure is a prerequisite of laparoscopic surgery in gynecology. In most laparoscopic procedures a combination of sharp and blunt dissection techniques is applied, often using the same instrument in various ways. Most hand instruments can easily be dismantled into three components: handle, insulated outer tube and working insert (Fig. 40). The insert of dismantling hand instruments varies only at the distal end. It may be a grasper, scissors, or forceps. Disposable or reusable instruments may be used with diameters ranging from 3 mm to 10 mm. One atraumatic and two grasping forceps are usually sufficient to perform the major steps of surgical operations.

Atraumatic and grasping forceps are available in various sizes and are indispensable for stabilizing tissues during surgery. Grasping forceps are available with single- or double-action jaws. The single-action graspers are preferred when the surgeon wants to work in a single plane in a controlled manner, particularly during adhesiolysis. Some handle types have connector pins for unipolar high frequency cords and many have a mechanism for on-axis rotation of the working insert with the distal tip. Others have connectors that allow for suction and irrigation, and sometimes a pistol grip handle with finger trigger for cutting and coagulation by use of high frequency current (Figs. 41–42).




Fig. 40
CLICKLINE® instruments feature a completely autoclavable, userfriendly design incorporating all the essentials of ergonomics. At the push of a button, the proximal outer sheath with insert separates from the handle. Reassembly is just as quick and easy.

- ① Connector pin for unipolar coagulation
- ② Insulated metal outer sheath
- ③ Forceps insert
- ④ Handle



Figs. 41a, b
Dissecting and grasping forceps. The specific design of the distal tip may be traumatic or atraumatic.



Fig. 42a
Various single-action grasping forceps.




Fig. 42b
Various double-action grasping forceps.

The protective insulation coating of the outer sheath of laparoscopic instruments must be of good quality to prevent accidental electric burns to the bowel or other viscera. The insulation may be of nylon or heat-shrinkable plastic (e.g., fluropolymer or polyester). At the time of cleaning and sterilization, suitable precautions must be taken to prevent that the insulation coating of reusable laparoscopic instruments is damaged due to improper handling or accidental contact with any kind of sharp-edged material. Integrity of the insulation must be closely inspected prior to surgery to make sure that even pinhole-sized defects in the insulation of a laparoscopic instruments are detected. To make sure that a laparoscopic instrument with faulty insulation cannot go unrecognized despite close visual inspection under a microscope, the preoperative use of an insulation testing device as part of the routine workflow is highly recommended.

Scissors and electro-surgical electrodes are the major instruments used for sharp dissection in laparoscopy. The proper use of scissors and electro-surgical instruments requires that inexperienced surgeons-in-training have already acquired an adequate level of technical proficiency before performing sharp dissection on actual patients by means of laparoscopy. There are various types of laparoscopic scissors. Scissors with straight blades are commonly used for mechanical dissection in laparoscopic surgery and may also be used to cut sutures. The most widely used scissors in laparoscopic surgery have a curved design. Slightly curved blades offer the advantage of improved ergonomic handling by eliminating the need for a realignment of the working angle of laparoscopic instruments. In addition, they allow for an improved endoscopic vision of the operating field (Fig. 43).

The main advantage of scissors with serrated cutting edges is that they prevent the tissue from slipping out of the blades. Serrated scissors are particularly useful for cutting slippery tissue and they may also be employed for cutting sutures. The blades of hook scissors can be partially closed holding the tissue in the hollow-ground area without transecting it, thus allowing the tissue to be slightly retracted before completing the cut. Moreover, this technical feature permits the surgeon to double-check and readjust the position of the



Fig. 43

- ① CLICKLINE® scissors, straight
- ② CLICKLINE® scissors, curved (Metzenbaum)
- ③ CLICKLINE® scissors with serrated blades
- ④ CLICKLINE® hook scissors

blades before they are closed. Hook scissors are particularly useful for transection of ducts, arteries or ligaments.

Insulated scissors may also be used in unipolar electro-surgery. Closed blades may be used for blunt dissection and electro-cautery. When using nondisposable instruments, however, electrocoagulation with open blades can lead to blunting of the blade edges. Adequate tension is usually applied to the tissues to be dissected with the aid of a grasper in the non-dominant hand while the other hand is performing the cut. Given the proper use of insulated instruments, any vessel encountered can be easily coagulated with the grasper. The pitfall of this method is, that it requires particular attention to be paid to the non-insulated distal part of the scissors which accommodates the metal blades and the hinge mechanism, an area which is prone to the potential risk of arc formation to non-target tissue. For safe practice, this area must be kept in view, however, at the cost of a reduced magnification range available to the surgeon.

11.0 High-Frequency Electrosurgery Techniques

There are various techniques of high-frequency electro-surgery, i.e., the way the electrical current is applied to the tissue. Traditionally, high-frequency electrical current can be applied in two ways: unipolar or bipolar.

11.1 Unipolar Electrosurgery

The unipolar technique is the most commonly applied method due to its versatility and clinical effectiveness.

In unipolar electrosurgery, the active electrode is at the surgical site. The patient return electrode (grounding pad) is elsewhere on the patient's body. The current passes through the patient as it completes the circuit from the active electrode to the patient return electrode. Unipolar electricity is potentially dangerous because part of the path traveled by the electrons is unknown. As a result, there is a potential risk of electrical burns at a distance from the active electrode.

While cleavage of tissue layers is obtained mostly with the unipolar technique, coagulation can be accomplished by using both techniques.

However, the new generators greatly reduce the risk of electrical injury. Unipolar electrosurgery may be applied for coagulation, for pure section, and coagulation-section by use of the blended (mixed) current. The coagulative current is characterized by intermittent periods of electrical activity during which cellular dehydration and protein coagulation are evoked which finally induces hemostasis. The non-modulated cutting current is a continuous flow of electrons that causes a rapid rise in intracellular temperature resulting in an explosion of the cell. We suggest always to use the continuous current




Fig. 44a
Unipolar needle electrode.




Fig. 44b
Spatula- and hook-shaped unipolar electrodes.

for coagulation because the voltage is lower. This application mode is less dangerous and can be as effective as pure coagulation or blended coagulation-section current.

The surgeon can choose among various shapes of unipolar electrodes according to the indication and individual preferences (**Figs. 44a, b**). The spatula- and hook-shaped electrodes are mainly used for unipolar cutting and coagulation. The spatula either comes as W-shaped or

blunt-tipped electrode. Unipolar hooks are also available in various shapes with L-, J- or U-configuration. In addition, ball-shaped, barrel-shaped or straight coagulation electrodes may also be used to achieve proper hemostasis. Blunt-tipped electrodes are particularly useful in the event of diffusely oozing hemorrhage if the point of bleeding cannot be clearly localized. Besides, the blunt-tipped electrode may also be used for blunt dissection during endometrial ablation.

11.2 Bipolar Electrosurgery

In the bipolar system, the current flows from one jaw of the bipolar forceps (the first electrode) through the tissue to the other jaw (the second electrode). The flow of the electro-surgical current in the patient is restricted to a small volume of tissue in the immediate area of application. This affords improved control over the area to be treated. Iatrogenic injury to vulnerable structures in close proximity to the electrodes can be avoided. The risk of current arcing, direct coupling, and capacitive coupling is very low, which is why patient burns are virtually eliminated. Both jaws of the bipolar forceps are insulated, accordingly there is no need for attaching a patient return electrode. Since coagulation is effected by a steep increase of the temperature in the tissues, however,

there is an obvious risk of patient burns if the thermal effect spreads further than desired. For this reason, the energy should always be applied with short exposure times and at an adequate distance from vulnerable structures. This basic rule not only applies to the proper coagulation of vessels but must be followed in all laparoscopic procedures. Disposable and reusable bipolar forceps of various sizes and shapes are available (**Fig. 45**). In gynecological surgery, bipolar forceps with electrodes of 3 mm in width are preferred. When surgery requires precise and limited coagulation, or when the surgeon wishes to reduce the extent of the thermal effect, 1.5 mm-jaws should be used. In this case, the power density will be elevated, however, exposure time is limited.

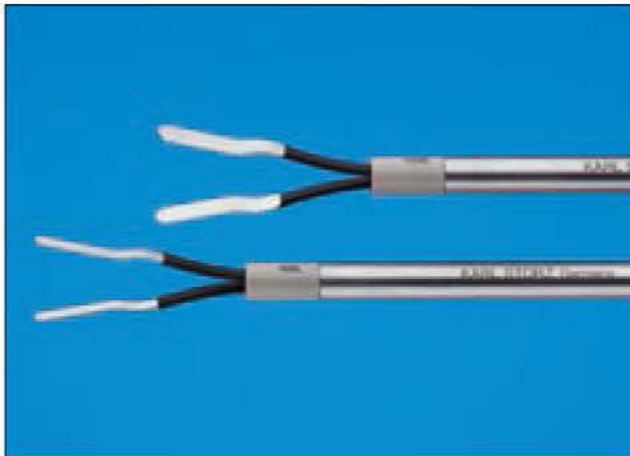

Fig. 45
Close-up view of the tips of bipolar forceps.



Fig. 46
RoBi® Bipolar Grasping Forceps and Scissors –
Clermont-Ferrand type (KARL STORZ Tuttlingen, Germany).

The efforts of current research and development have shown an increasing tendency toward the use of bipolar forceps with added functionality such as grasping, dissection and cutting. The main objective is to reduce the number of instrument changes required during surgery. The new rotational bipolar instruments (**RoBi®** bipolar grasping forceps and scissors – Clermont Ferrand type) meet the requirements of four basic actions of surgery: dissection, cutting, grasping and hemostasis (**Fig. 46**). The working inserts can be swiftly exchanged during the operation according to the needs of the surgeon.

This new series of sophisticated bipolar instruments with rotational and exchangeable working inserts significantly contributes to ergonomic efficiency and workflow in the operating room. For maintenance and sterilization the instrument can be easily disassembled. In summary, the authors prefer to use the **RoBi®** bipolar grasping forceps and scissors as first-choice option, in all other cases conventional bipolar instrument or a Kepplinger spatula may be used, the latter creating a large zone of coagulation.



Fig. 47
The high frequency electro-surgical unit AUTOCON® II 400, (KARL STORZ Tuttlingen, Germany).

12.0 High Frequency Electro-surgical Units

The AUTOCON® II 400 is a versatile, state-of-the-art high frequency electro-surgical unit designed for both unipolar and bipolar electro-surgical applications. The operational parameters of various cutting and coagulation settings can be preselected on the frontpanel display, thus providing the user with a highly accurate and reproducible method to obtain good results. Exact fine-tuning in 1 W-steps is enabled for procedures that require maximum precision at very low power. Up to 8 hemostatic effects for unipolar and bipolar cutting, each with up to 370 W output, permit optimal control of coagulation and the intended surgical effect. In the bipolar coagulation mode, the autostart function automatically activates the coagulation current as soon as the electrode has touched the tissue with both branches. The various safety circuits of the unit provide a very high level of safety for both the patient and staff. Software-supported test programs ensure easy and rapid servicing. The color touch-screen with its modern and user-friendly design allows for easy operability, maintenance and cleaning (**Fig. 47**).

13.0 Laser Systems

The most commonly used type of laser is the CO₂ laser, which is also considered to be the most precise which causes the least thermal injury. Even though the CO₂ laser is considered to be highly efficient in terms of tissue vaporization, cutting or excision, but has only minimal coagulating properties. Lasers with a short wavelength such as Argon, Neodymium:Yttrium-Aluminum Garnet (Nd:YAG) and KTP 532 lasers (Potassium Titanyl Phosphate; KTiOPO₄, KTP) have good coagulating properties but are less efficient in terms of vaporization. The degree and extent of thermal damage produced by laser irradiation depends on the structure, water content, pigmentation and the state of tissue perfusion. In addition, user-determined operational parameters can have a considerable

impact on the outcome of the laser treatment, such as the inherent absorption characteristics / wavelength of the laser system specifically selected for the intended application, spot size, power density, mode of delivery (contact/ no contact) and exposure time (intermittent or continuous).

In summary, each of the various laser systems available on the market has a specific clinical application. Laser generators are much more expensive than electro-surgical systems, and there are many safety aspects, such as the potential risk of cumulative thermal effects, burns due to inappropriate exposure and retinal damage, that speak against the widespread use of laser technology.

14.0 Ultrasonic Dissection and Coagulation Systems

The use of ultrasonic energy for cutting and coagulation is an alternative to electro-surgery. Ultrasound is the unique energy form that allows both cutting and coagulation of tissues without exposing the patient to the risks associated with the application of high frequency current. The major benefit of this alternative technique is that only a minor degree of lateral heat-induced tissue damage occurs. Ultrasonic systems that are operated at low power settings cleave water-containing tissues through cavitation sparing organized structures of low water content without coagulating vessels (frequently applied

in liver surgery). High power settings can be applied to cleave the loose surrounding tissues by frictional heat while simultaneously coagulating the wound margins (frequently applied in colon surgery). High-power ultrasonic dissection can cause collateral damage by excessive generation of heat. However, in view of the high level of operational reliability and safety feasible with this alternative technology, the anticipated advances in the further development will certainly make it a valuable tool in the future.

15.0 Suction and Irrigation Systems

Controlled suction and irrigation is of great importance because it provides the surgeon with a clear field of vision during laparoscopic surgery. For that reason, we suggest to have a suction-irrigation system on stand-by even in cases of diagnostic laparoscopy (**Fig. 48**). The system may also be used for lavage of the abdominal cavity, control of bleeding and aspiration of clots, as required by the individual situation. The electromotor-driven pressure/suction pump is protected against entry of body secretions. Hydrodissection with a high-pressure water stream (hydro-jet) of up to 1200 mmHg may also be applied for cleavage of tissue layers and spaces. Most surgeons use physiological saline or Ringer's lactate solution for irrigation purposes. At times, heparinized saline is used to dissolve blood clots and facilitate adequate aspiration in cases of profuse intra-abdominal bleeding. A 10 mm-suction cannula should be used in the presence of more than 1500 ml of hemoperitoneum or if there are blood clots inside the abdominal cavity. Suction-irrigation cannulas are available in various sizes and must be selected according to the trocar size of the laparoscopic approach.

Aspiration needles or suction cannulas have a standard size of 5 mm (**Fig. 49**) fitted for being inserted through an accessory 6 mm-trocar (**Fig. 50**).



Fig. 48
The HAMOU ENDOMAT® suction/irrigation system, (KARL STORZ Tuttlingen, Germany).

During laparoscopic surgery, suction-irrigation cannulas may be used for aspiration of fluid contents of ovarian cysts, bile or for injection of vasoconstrictive agents. Careful attention must be paid during insertion of the suction cannula to prevent inadvertent perforation of viscera.



Fig. 49
Distal tips of suction cannula (top) and puncture needle (bottom).



Fig. 50
5 mm-suction cannula (top); 10 mm-suction cannula with ergonomic pistol handle (bottom).

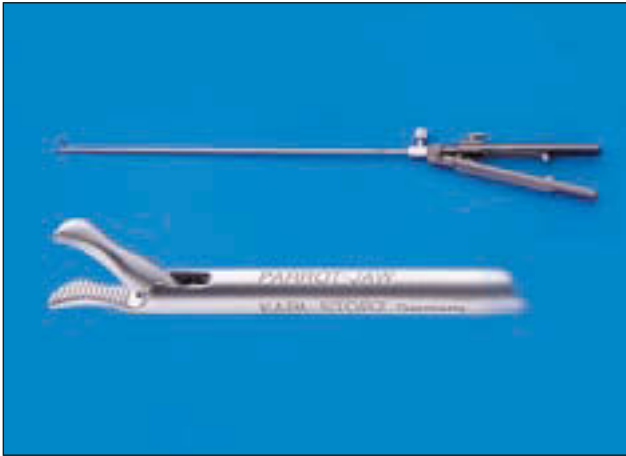

Fig. 51
The SZABO-BERCI Needle Holder PARROT-JAW® with straight handle and adjustable ratchet.

16.0 Suture Techniques

Advanced laparoscopic procedures can be performed safely and effectively only if the surgeon or gynecologist has gone through the initial stages of surgical training and has gained an adequate level of proficiency in intracorporeal suturing and knot tying techniques. Laparoscopic suturing and knot tying should be practiced on a good quality endotrainer with an experienced tutor. There are two suturing methods: the intracorporeal and the extracorporeal technique. The major steps of the intracorporeal technique are: introduction of the needle and intraabdominal suturing, placement of suture ligatures, knot tying, either extracorporeal or intracorporeal.

Intracorporeal suturing techniques involve that each knot is formed and tied inside the cavity with the aid of needle holders. There are many different types of needle holders that essentially vary in handle design and tip configuration (**Figs. 51–52**). In our opinion, intracorporeal knots should be reserved to experienced surgeons, because advanced procedures require a good command of microsurgical suture techniques. Once an adequate level of proficiency in intracorporeal suture and ligature has been achieved, the surgeon's conversion rate will certainly decrease.



Fig. 52a
Various needle holders with curved jaws.



Fig. 52b
The KOH Macro Needle Holder with curved jaws, ergonomic pistol handle and disengageable ratchet.

As the term denotes, extracorporeal suturing and knot tying is performed outside the body cavity. Once the tissue is sutured, the needle is removed through the trocar cannula and the suture is completed extracorporeally. In this case, a knot tier is required. Even though pre-tied loops are available in the market, surgeons-in-training should learn the basic skills of extracorporeal knot tying. For extracorporeal knotting various types of knot pushers can be used. Knot pushers are of either closed-jaw or of open-jaw type (**Fig. 53**). For a trainee who has strong convictions to pursue a surgical career it is essential to make every effort to perfect his/her skills to achieve an adequate level of proficiency in suturing techniques. The correct extracorporeal Roeder knot is very useful. For major or safety sutures, e.g., for ligature of a uterine vascular pedicle in hysterectomy, the extracorporeal Roeder knot is necessary. To push the knot, a specific open-jaw knot pusher is used. The endoloop is the oldest device used for laparoscopic-guided ligature; it is a loop with a pre-formed slipknot that can be positioned around the structure that needs to be removed.

In some cases, a laparoscopic clip applicator may be necessary. In minimally invasive surgery, surgical clips are used for tissue approximation. Most of them are made of pure titanium or of titanium alloys. Surgical clips are easy to apply and can be left inside the abdominal cavity. After a few weeks, the clip is covered by fibrous tissue. The jaw of the clip applicator should be located perpendicular to the wound site before deploying the clip, the surgeon should take care that both jaws are in view. Two clips are usually deployed over the structure that needs to be secured. One clip is deployed over the tissue which the surgeon wants to remove to prevent spillage of fluid. The clips should not be applied very close to each other.

17.0 Extraction Bag

Disposable extraction bags are very important to prevent contamination of the abdominal wall during extraction of specimens from the abdominal cavity (**Fig. 54**). Extraction protected by an endoscopic bag is mandatory to obviate the risk of benign dissemination (e.g., in the case of endometriosis, ectopic pregnancy, and benign ovarian cysts), spillage during removal of a benign teratoma, risks of infection (pyosalpinx), and risks of malignant dissemination (suspected cysts). The extraction bag must be very strong so that it can resist the force that is exerted by the surgeon while pulling it through a small opening.

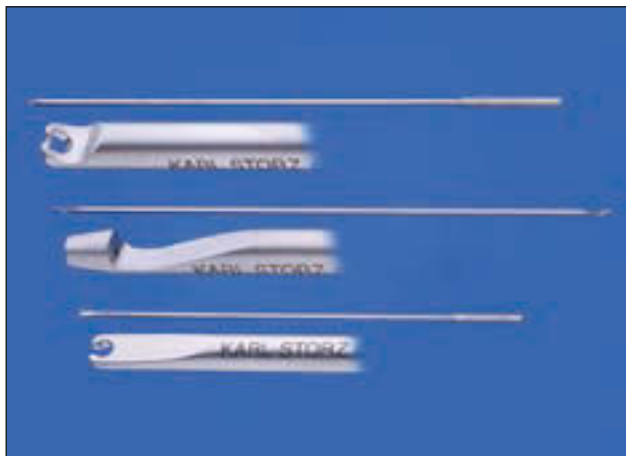


Fig. 53
Knot tier for extracorporeal knotting. The close-up views show the various types of open-end, and closed-end tip design.

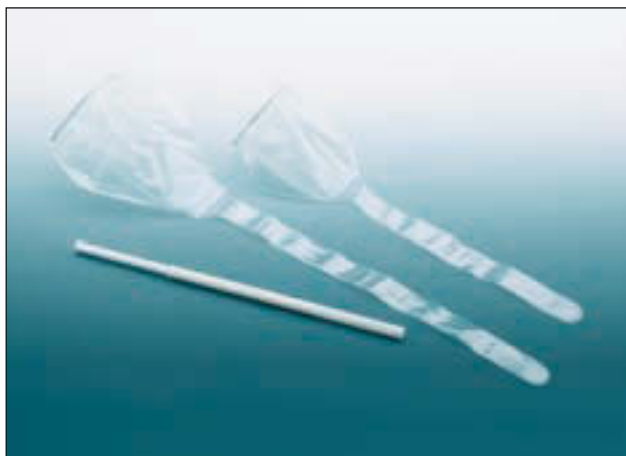

Fig. 54
Disposable extraction bag.

18.0 Morcellator Systems

An electronic or manual morcellator can be used for piecemeal removal of large specimens, such as fibroids or the uterus during laparoscopic hysterectomy, and particularly, supracervical hysterectomy (**Figs. 55a, b**). The fully autoclavable **ROTOCUT G1** morcellator is an efficient and time-saving alternative to previous systems. Rapid removal of large tissue segments is facilitated by the highly efficient cutting performance of the disposable cutting blades, which can be changed intraoperatively. The blades are available in sizes of 12-mm or 15-mm. Optimal weight distribution and direct activation ensure a straight-forward and smooth operation. A specially designed trocar sleeve protects tissue from inadvertent blade contact. The powerful **ROTOCUT G1** has a direct drive motor that produces a maximum speed of 1200 rpm, minimizing the amount of effort required of surgeons and reducing procedure times. The control unit that optimizes Rotocut's performance is the UNIDRIVE® S III, which is compatible with all previous generations of KARL STORZ morcellators.

The removal of large portions of tissue may also be accomplished with the aid of endoscopic cold knives introduced through a minimal abdominal incision or vaginal puncture. These shielded blade carriers permit endoscopic insertion and application of cold knives in the abdominal cavity. There is a great variety of extraction devices on the market. One, that should be mentioned is the vaginal extractor. It allows intra-abdominal specimens to be retrieved via the vagina, while maintaining the integrity of the pneumoperitoneum and, therefore, endoscopic-assisted retrieval under optimal viewing conditions. During laparoscopic myomectomy, it is essential to have a screw- or spiral-tipped instrument that allows for proper fixation and removal of subserous or intramural fibroids (**Fig. 56**).



Fig. 55 a
The morcellator system ROTO CUT G1, laparoscopy set.



Fig. 55 b
The hollow shaft motor of the ROTO CUT G1 morcellator is used in conjunction with the control unit UNIDRIVE® S III.



Fig. 56
Myoma fixation instrument with screw-shaped tip.

19.0 Uterine Manipulators

Various instruments and auxiliary devices may be used for mobilizing or stabilizing the uterus and adnexae during both diagnostic and operative laparoscopic surgery.

A uterine manipulator is used in the majority of advanced laparoscopic-assisted gynecological procedures, be it for

diagnostic assessment or surgical interventions. The uterine manipulator is of crucial importance because it facilitates visualization of the pelvic organs and permits endoscopically-controlled injection of methylene blue in the case of chromo-pertubation for assessment of tubal patency (Figs. 57–59).

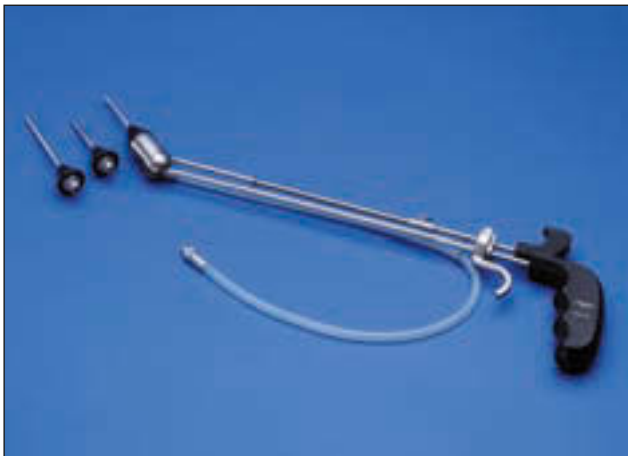

Fig. 57
The TINTARA uterine manipulator (KARL STORZ Tuttlingen, Germany).

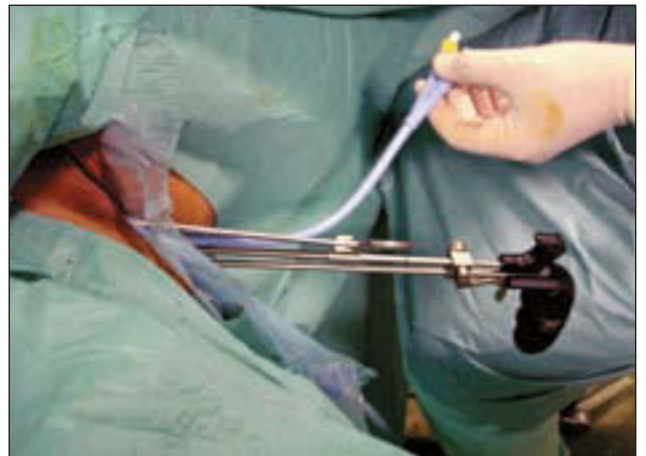

Fig. 58
Proper placement of the uterine manipulator.



Fig. 59
The CLERMONT-FERRAND uterine manipulator (KARL STORZ Tuttlingen, Germany).

20.0 Operating Room Setup and Preparation of the Patient

Endoscopic surgery requires a perfect technological environment. Knowledge of the instruments and operating room setup is essential for optimizing the workflow of endoscopic procedures and the facilitating the interaction between surgeons, medical personnel, and all areas inside and outside of the hospital. A well organized operating room is not only an essential prerequisite for the successful outcome of laparoscopy, but also reduces costs. The operating room should be large enough to accommodate the necessary equipment. Before starting surgery, it is necessary to check the instrumentation, particularly the insufflation unit, as well as the high frequency surgery unit and the suction-irrigation system. The number of persons forming the surgical team depends on the surgical indication. As a rule, one assistant and one surgical nurse are sufficient. Certain procedures require an additional assistant (**Fig. 60**). It is essential that all members of the surgical team (including the surgeon) be trained and capable of solving all technical problems which could occur before and during the intervention.

Patients must be informed of the therapeutic benefits and all potential risks (informed consent). The possibility that a laparotomy may be required must always be mentioned. Intestinal preparation is often useful. Bowel preparation can minimize the need for an accessory port to retract the bowel. Its purpose is to empty the small intestine and facilitate vision by flattening the intestinal loops and pushing them out of the way. In all cases associated with an increased inherent risk of intestinal injury is (endometriosis of the rectovaginal septum or major adhesiolysis), preoperative bowel preparation is more complete and resembles the preparatory measures applied prior to bowel surgery. Before being admitted to the operating room, the patient should always void. The full urinary bladder may be inadvertently perforated during insertion of the Veress needle or trocar. If gynecological surgery or any general lower abdominal surgery is planned (such as hernia repair or adhesiolysis) it is advisable to insert a Foley catheter. If any upper abdominal procedure has been scheduled, it is good practice to have a nasogastric tube in place.

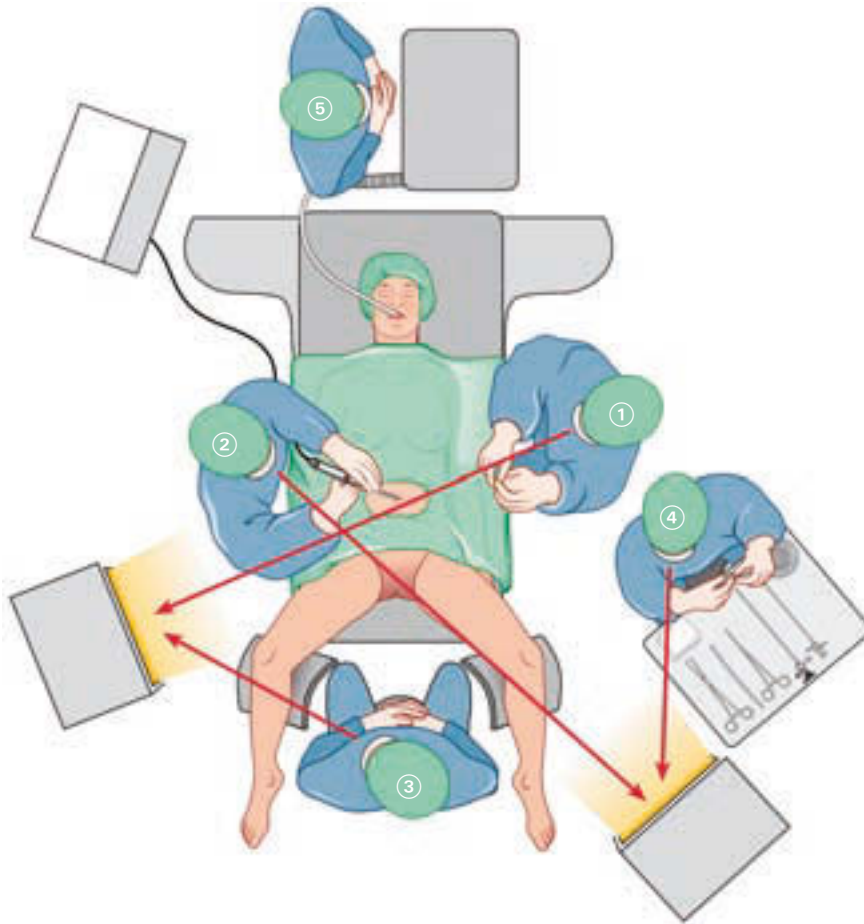


Fig. 60

Schematic drawing of the room setup illustrating the optimal arrangement of the surgical team and equipment during gynecological laparoscopic procedures. ① – operating surgeon; ② – first assistant; ③ – second assistant; ④ – scrub nurse; ⑤ – anaesthesiologist.

21.0 Patient Positioning

Positioning of the patient is also important for the successful outcome of surgery. The patient is placed in a low dorsolithotomic position (gynecological position) with her legs positioned to provide vaginal access (Fig. 61). The patient's legs should be comfortably supported by padded obstetric knee braces or Allen stirrups to minimize the risk of deep vein thrombosis (Fig. 62). The Trendelenburg position should be used only after the main trocar has been inserted, because the Trendelenburg position brings the sacral promontory, and therefore the major vessels (bifurcation of the aorta and left common iliac vein) into the axis of trocar insertion. In gynecological laparoscopic procedures or if laparoscopy is to be performed together with hysteroscopy, the patient should be positioned in the lithotomy position which enables an assistant to stand between the patient's legs allowing for free access to the lower abdomen (Fig. 63). In these procedures, the surgeon needs to use a uterine manipulator for proper visualization of the female reproductive organs.

The assistant seated between the legs of the patient watches the hand movements of the surgeon on the monitor and should maintain traction in the appropriate direction with the handle of the uterine manipulator.

Proper make-up assignment of the surgical team is also a basic prerequisite for the successful outcome of any laparoscopic operation. In the majority of cases, the surgeon stands on the left side of the patient. A surgeon who is left handed, should stand to the right of the patient during creation of the primary port. This facilitates inserting the Veress needle or primary trocar towards the pelvis with the dominant hand. The camera assistant should be positioned opposite to the surgeon, but it is always recommended to have two video monitors, one for the surgeon, and one for the camera assistant and other members of the surgical team. If only one monitor is available, it should be located between the legs of the patient.

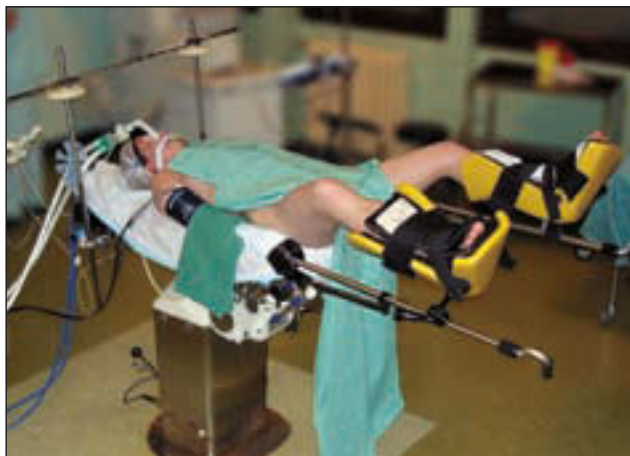

Fig. 61
Correct preoperative placement of the patient on the operating table in low dorsolithotomic position.

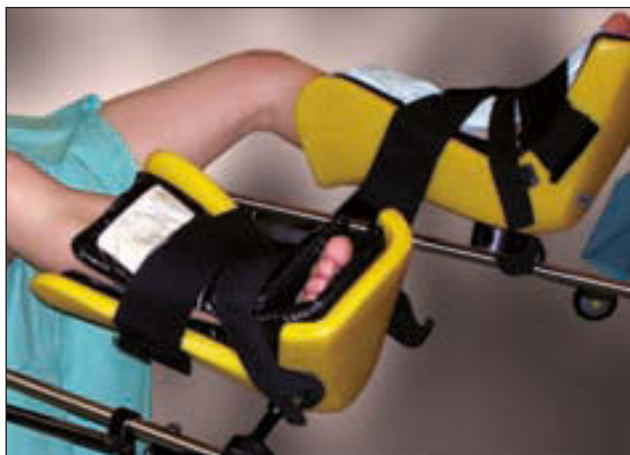

Fig. 62
The legs are gently placed in well-padded boot-type stirrups for routine deep vein thrombosis prophylaxis.

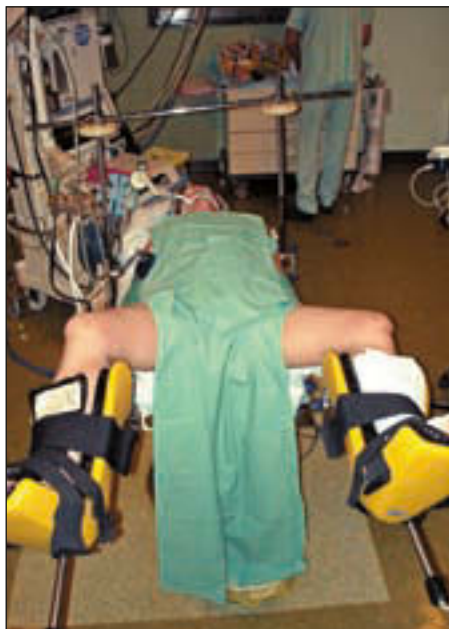

Fig. 63
Placement of the patient in low dorsolithotomic position enables proper manipulation of the laparoscopic instruments via the accessory ports.

22.0 Maintenance and Sterilization

Professionals in charge of cleaning, decontamination, sterilization, and inspection of surgical instruments, devices, and implants should be adequately trained so that they are fully aware of the delicacy and cost of endoscopic equipment. Setting up the operating room prior to surgery includes testing the camera equipment, the light source, the insufflation unit and CO₂ tanks, the suction-irrigation system and – taking great care – the bipolar and unipolar electrocoagulation system.

Because of the importance of having optimized instrument management quality and economy, KARL STORZ has developed the **EndoProtect1™** service, consisting of modular services that ensure the optimal deployment of instruments sets in the hospital, the replacement of instruments and their proper and careful handling by personnel. Also a database-supported management and monitoring system is offered for the entire range of instruments in offices and hospitals. This new system is the KARL STORZ instrument management platform, which enables each individual instrument to be accurately registered using a special data matrix code and rapid, error-free identification with a scan camera.

Disposable instruments shall not be resterilized for reuse in laparoscopic surgery because such practice is associated with an elevated risk of pathogen transmission compared to the effectiveness of cleaning and sterilization procedures applied to reusable instruments.

Recommended Literature:

MENCAGLIA L, WATTIEZ A: Manual of Gynaecological Laparoscopic Surgery. (2000); Endo-Press® Tuttlingen, Germany

HULKA J, REICH H: Textbook of laparoscopy, Third edition (USA). (2002); 53–56, 69–81, 276–283

Disposable instruments are not designed to be cleaned in a similar way as their reusable counterparts, e.g., the **CLICKline®** series of dismantling instruments. Reusable surgical instruments must be safely cleaned and sterilized immediately after surgery. Instruments must be dismantled prior to cleaning. After decontamination, every small piece and recess must be cleaned and dried with water and compressed air. For lenses and telescopes, alcohol or special soap should be used. The majority of up-to-date instruments are designed for steam heat sterilization (autoclaving). Other validated sterilization procedures currently in use:

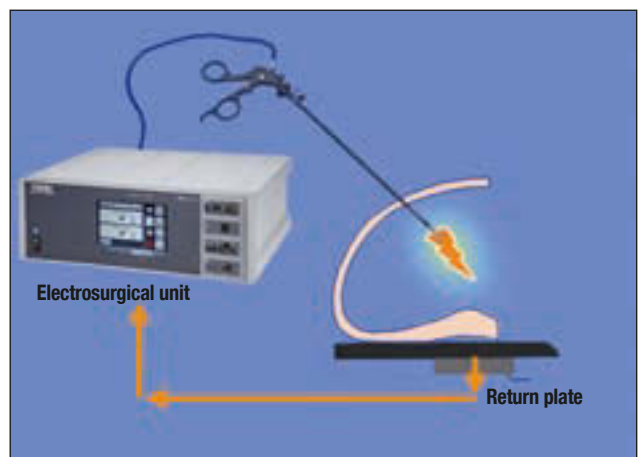
- Sterilization via autoclave is the most widely used and inexpensive method. In the case of endoscopes and instruments expressly manufactured and sold as autoclavable, sterilization cycles of 121°C for 20 minutes, or 134°C for 7 minutes are used.
- Gas sterilization with ethylene oxide is generally considered to be the ideal method of sterilization, because it acts at a relatively low temperature and is not detrimental to endoscopic instrumentation. Unfortunately, the technique is relatively expensive and time-consuming (72 hours prior to reuse of instruments). Therefore, only a few centers use gas sterilization, because multiple sets of laparoscopic instruments should always be held available.

Chapter II

Use of Electricity in Laparoscopy

Paulo Ayroza and Elizabet Abdalla

Department of Gynecology and Obstetrics,
Medical School of the Santa Casa University of São Paulo, Brazil



1.0 History

The therapeutic use of heat in the treatment of human beings has been known for a very long time. The Egyptians used cauterization to treat tumors three thousand years B.C. Four hundred years before the Christian era, *Hippocrates* discussed the use of heat to treat diseases. In this context, he described the use of cauterization to treat joint problems and haemorrhoids. He also recommended applying seven or eight little pieces of heated iron to the hemorrhoid to arrest bleeding. However, it was only at the start of the 20th century that *Koch* described cauterization using electricity. In this technique, an electric current heated the tip of a forceps and the hot metal was applied to the tissue to cauterize it. In 1878, *Koch* also described the first tubal sterilization by means of cauterization with a wire heated by an electric current.

In fact, there is a great difference between electrocautery and electrosurgery. In the former, electricity heats a metal instrument, which is then applied to the tissue. In electrosurgery, the opposite occurs, with the current producing heat as it passes through the tissue.

Electrosurgery developed in the 20th century. It causes the electric current to pass through the body, producing heat due to tissue impedance. Unlike cauterization, during electrosurgery the forceps does not heat to the point of burning but is limited to transmitting the electric current to the tissues. The development of electrosurgery passed through various periods and various discoveries were made. It is worth recalling how a few concepts that are today regarded as very simple were established.

- Experiments with static electricity, which began in 1786, used direct current, also known as galvanic current, which produced muscle contractions.
- The specific current induction developed by *Faraday* and *Henry* was integrated in 1891 by *D'Arsonval*, who described the use of high frequency current to counteract muscle contractions.

2.0 Principles of Electrosurgery

Several properties of electricity must be understood in order to understand electrosurgery. Electrons orbit the nucleus of an atom. When the electrons flow from one atom to the orbit of an adjacent atom, there is a flow of current. Voltage is the "force" or "push" that provides electrons with the ability to travel from atom to atom. If the electrons encounter resistance, heat is produced. The resistance to the flow of electrons is called impedance. A complete (or closed) electrical circuit is required to make electrons to flow through. In other words, only an uninterrupted pathway allows electrons to circulate.

The common terms used to describe the principles of electrosurgery include:

- **Current:** flow of electrons in a certain period of time, measured in amperes.

- An electrosurgical generator was used for the first time in the operating room by *Cushing* in 1926. Although he was not the first to try it, *William Bovie* was the one responsible for developing the modern concept of electrosurgery.
- In 1934, *Werner* described tissue coagulation using high frequency electrical energy. This concept represented an important step forward in surgery and is still used widely today.

The use of electrosurgical energy in laparoscopy dates from the 1960s when gynecologists were the first to use laparoscopy for minor surgical procedures such as tubal sterilization. At the start, there were some mishaps, which discouraged the use of the monopolar modality of electrosurgery for the next two decades. Technical developments led to the production of new electrosurgical generators and laparoscopic instruments specially designed for this modality. Thus, at the end of the 1980s, electrosurgery came back to fill an indispensable space in gynecological endoscopy.

Electrosurgery is the most frequently used form of energy in all branches of surgery. In 1995, *Odell* demonstrated how the use of electrosurgery in laparoscopy optimizes the procedures, reducing operation time and blood loss.

Over the years, some doubts have emerged regarding possible injuries caused by heat in healthy tissue. In 1982, *Riedel* and *Semm* described the risks of inappropriate use of electrosurgery and they emphasized the need for appropriate monitoring of this technique.

Various studies have analyzed injuries caused to the tissues by monopolar and bipolar electrocoagulation. In 1995, with different devices, *Baggish* and *Tucker* evaluated histologically the extent of necrosis caused by monopolar and bipolar electrocoagulation.

- **Voltage:** the force that drives the current or flow of electrons, measured in volts.
- **Resistance:** obstacle to the flow of current, measured in ohms (resistance = impedance).

The following principles apply specifically in electrosurgery:

- The electrosurgical generator (ESG) is the source of the electron flow and voltage.
- A monopolar circuit consists of the generator, an active electrode, the patient and the patient return electrode.
- There are numerous pathways to ground for leakage current and these may include the OR table, stirrups, staff members and equipment.
- The patient's tissues provide the impedance, producing heat when the electrons overcome the impedance.

2.1 Various Forms of Electric Current

Various forms of electric current are associated with surgical applications.

- **Direct current (DC):** the electron exchange occurs continuously in a single direction. This type of current can be used in medicine for therapeutic purposes (for example, acupuncture and pain electrotherapy).
- **Pulsed current:** a relatively high amount of energy is discharged at short intervals. This is useful for nerve stimulation, for example, in electromyography.
- **Alternating current (AC):** the electron exchange between the two electrodes is bidirectional. This is the electric current used in electrosurgery.

When an electric current flows through biological tissue, the following effects can be observed:

- **Thermal effect:** as electricity passes through the tissue it generates heat, which is the only effect desired in electrosurgery. The amount of heat generated depends on the intensity of the electric current, the resistance of the tissue and the duration of current flow.
- **Electrolytic effect:** when a direct electric current passes through a tissue with a high electrolyte concentration, it can cause polarization of the electrolytic compounds. The

ions can flow in the direction corresponding to their polarity and in this way the concentration of ions can increase in direct relation with the intensity and duration of the electric current. To avoid the electrolytic effect, electrosurgery uses alternating current, where the constant reversal of polarity reduces the potential damage caused by polarization.

- **Faradic effect:** when passing through the tissue, the electric current can stimulate the nerve endings, inducing reactions such as muscle contraction and pain. This is caused by the frequency of the electrical current; low frequencies in particular stimulate nerve endings.

The modern concept of electrosurgery involves using a high frequency electric current to avoid the negative effects of neuromuscular stimulation. Since nerve and muscle stimulation ceases at 10,000 cycles/second (10 kHz), electrosurgery can be performed safely at “radio” frequencies above 100 kHz. An electrosurgical generator produces a 60-cycle current and increases the frequency to over 300,000 cycles per second. At this frequency, electrosurgical energy can pass through the patient with minimal neuromuscular stimulation and no risk of electrocution.

Monopolar electric current reaches the human body through an active electrode and leaves it through a neutral electrode.

2.2 Waveform

An electrical wave has a sine form that can be modified, resulting in waves with different forms and different effects. Two types of electrical wave are normally used in electrosurgery:

- Non-modulated (**Fig. 1**), also called pure wave, obtained using a free alternating current of continuous form, which is responsible for the cutting effect. It can also be used for coagulation.
- Modulated (**Fig. 2**), so called because this waveform produces some modifications in frequency and amplitude. This waveform is used especially for coagulation.
- A third waveform, the so-called “blended current”, can be used. This is not a mixture of cutting and coagulation

currents but rather a variation of the duty cycle. Moving from *blend 1* to *blend 3*, the duty cycle is reduced progressively. A lower duty cycle produces less heat. Consequently, *blend 1* is able to vaporize tissue with minimal hemostasis whereas *blend 3* is less effective at cutting but provides maximum hemostasis.

The only variable that determines whether a waveform vaporizes tissue or causes coagulation is the rate at which heat is produced. A high amount of thermal energy released rapidly induces vaporization, whereas a low amount released more slowly induces coagulation. Any one of the five waveforms (non-modulated, modulated and the 3 blends) can accomplish both tasks by modifying the variables that influence the tissue effect.

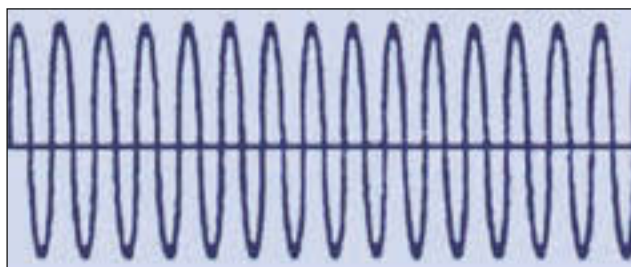


Fig. 1
Pure or unmodulated wave form.

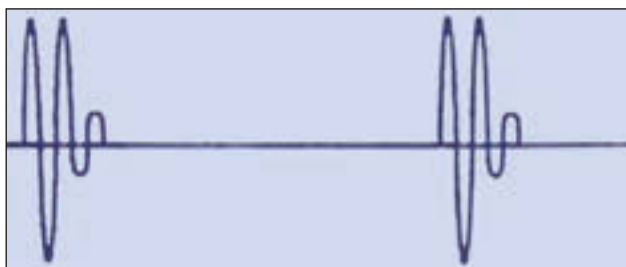


Fig. 2
Modulated electrical wave.

2.3 Use of the thermal effect in electrosurgery

High frequency surgery uses the thermal effect caused by the passage of an electric current through the tissue. There are two basic methods of thermal tissue destruction: cutting and coagulation.

Cutting

When a high current density is applied to a tissue, the heating of the intracellular fluid from 37° to 100° C is so fast that there is no time for the water to evaporate. The resulting vapor pressure leads to explosion of the cellular membranes. This phenomenon is called vaporization. The separation of tissues by means of heat can be used to cut and has many advantages compared to mechanical cutting (for example, minor bleeding and minimal coagulation effect at the incision). This modality is more powerful and generally less penetrating. When used with fine electrodes, it allows precise cutting with minimal coagulation. It can also reduce operating times. With thicker or wider electrodes the contact area and also the potential for thermal injury are increased.

To obtain a suitable cutting effect, the generator must be activated before the electrode touches the tissue. A layer of vapor and carbon particles is created between the electrode and the tissue to create a current pathway. The electrosurgical cutting effect is similar to dissection without touching the tissue. If the electrode is used slowly or is held stationary, the risk of thermal damage to the tissue is increased.

The electrosurgical cutting effect is used on vascular tissue such as in adhesiolysis and also for peritoneal endometriosis resection.

Coagulation

For coagulation a low current density is usually applied so that the tissue temperature increases slowly giving the water enough time to evaporate. Meanwhile, the tissue undergoes thermal coagulation. In this process, the heat first causes coagulation of the connective tissue, denaturing proteins but preserving cellular architecture. After that an amorphous coagulum is formed when disintegration is complete. This is indicated by the visual effect of carbonization. The gradual cellular retraction that occurs during thermal hemostasis allows the closure of small vessels. The result is creation of a coagulum rather than cellular vaporization. In order to overcome the high impedance of air, the coagulation waveform has significantly higher voltage than the cutting current. Use of a high voltage coagulation current has implications during minimally invasive surgery.

Electrosurgical desiccation occurs when the electrode is in direct contact with the tissue. Desiccation is achieved most efficiently with the cutting current. By touching the tissue with the electrode, the current density is reduced. Less heat is generated and no cutting action occurs. The cells dry out and form a coagulum rather than vaporize and explode.

Some surgeons cut with the coagulation current. Likewise, it is possible to coagulate with the cutting current by holding the electrode in direct contact with the tissue. It may be necessary to adjust power settings and electrode size to achieve the desired surgical effect. The advantage of coagulating with the cutting current is that a much lower voltage is used.

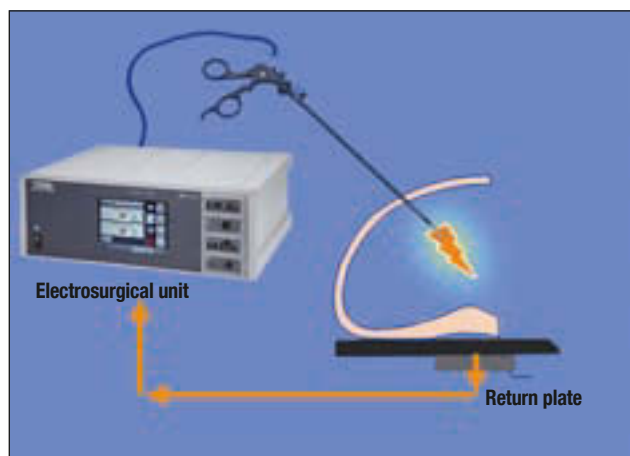


Fig. 3
Monopolar modality.

2.4 Different Electrosurgery Modalities

By modalities of electrosurgery is meant the way the electrical current is applied to the tissue. High frequency electrical current can traditionally be applied with two different modalities: monopolar or bipolar. While tissue separation is obtained mostly with the monopolar technique, coagulation can be obtained with both modalities.

Monopolar: monopolar is the most commonly used electrosurgical modality due to its versatility and clinical effectiveness. In monopolar electrosurgery, the active electrode is at the surgical site. The patient return electrode is elsewhere on the patient's body. The current passes through the patient as it completes the circuit from the active electrode to the patient return electrode (**Fig. 3**).

Bipolar: in bipolar electrosurgery, the two tines of the forceps perform the functions of both the active electrode and the return electrode at the site of surgery. Only the tissue grasped by the forceps is included in the electrical circuit. Because the return function is performed by one tip of the forceps, a patient return electrode is not needed. The current passes through the tissue held by the forceps and returns directly to the electrosurgical unit without getting into contact with other tissues. In this case, the damage produced in the tissues is limited and the risk of thermal injury in distant tissues is infinitely lower (**Fig. 4**).

The bipolar modality presents some advantages compared to the monopolar:

- The current flow through tissue is restricted to the area between the two jaws of the electrode, which is under the direct vision of the surgeon. In the monopolar technique, the current passes through many tissues outside the surgeon's visual control before it can return to the electrosurgical generator.
- The risk of thermal injuries in distant tissues due to direct contact of instruments, faulty insulation or diffusion of the electrical current is reduced in the bipolar technique.
- The risk of interference with other electronic equipment, (ECG, pacemakers and others) connected to the patient at the same time, is lower.

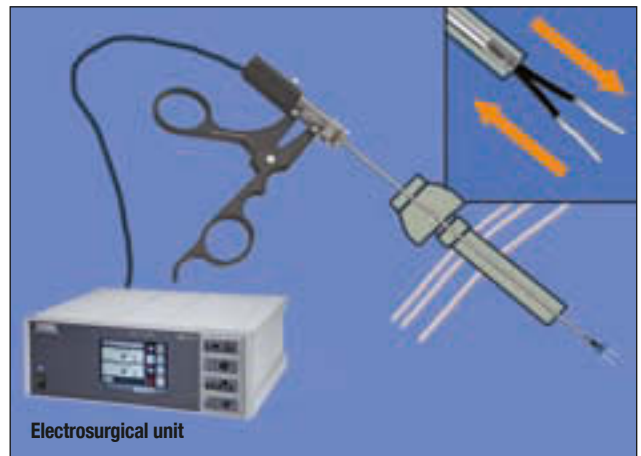


Fig. 4
Bipolar modality.

3.0 Electrosurgery: General Safety Aspects

3.1 Grounded Electrosurgical Systems

When it is understood that the electrical current is essentially a continuous flow of electrons with an entry and exit site, it is easy to understand that the current must return to some place along some pathway. The place is the unit and the pathway is the return plate. Through the phenomenon known as current division, the current can split and follow more than one path to ground. The circuit to ground is completed whether it travels the intended electrosurgical circuit to the patient return electrode or to an alternative ground.

This would put patients at risk of burns at an alternative site because:

- the current follows the easiest and most conductive path,
- any grounded object can complete the circuit, not just the electrosurgical generator,
- the surgical environment offers many alternative routes to ground,
- if the resistance of the alternative path is sufficiently low and the current flowing to ground in that path is sufficiently concentrated, an accidental burn may occur at the alternative grounding site.

3.2 Isolated Electrosurgical Systems

If the circuit to the patient return electrode is interrupted, an isolated generator will deactivate the system because the current cannot return to its source. Generators with insulated circuits reduce the risk of burns at alternative sites but do not protect the patient from burns caused by the return electrode.

Historically, patient return electrode burns have accounted for 70% of the injuries reported during the use of electrosurgery.

Patient return electrodes are not “inactive” or “passive”. The only differences between the “active” electrode and the patient return electrode are their size and relative conductivity. The quality of the conductivity and contact area at the plate/patient interface must be maintained to prevent injury at the return electrode site.

3.3 Patient Return Electrodes

- **Function of the patient return electrode.**

The function of the patient return electrode is to collect and remove current from the patient safely. A return electrode burn occurs when the heat produced over time is not safely dissipated by the size or conductivity of the patient return electrode.

- **Ideal return electrode contact with current dispersion.**

The ideal patient return electrode safely collects current delivered to the patient during electrosurgery and carries that current away. To eliminate the risk of current density, the plate should present a large contact area to the patient associated with low impedance (**Fig. 5**). It should be placed on conductive tissue as close as possible to the operative site.

It should be recalled that the only difference between the “active” electrode and the patient return electrode is their relative size and conductivity. If the electrons are concentrated at the active electrode, a lot of heat is produced. If this current is dispersed over a comparatively large patient return electrode, little heat is produced.

If the surface contact area between the patient and the return electrode is reduced or if the impedance of that contact is increased, a dangerous condition can develop. In the case of a reduced contact area, the current flow is concentrated in a smaller area (**Fig. 6**). This causes an increase in the temperature of the return electrode. If the temperature of the return electrode increases sufficiently, the patient may sustain a burn. Many factors can cause an increase in impedance, including excessive hair on the contact surface, adipose tissue, bony prominences, the presence of liquid, poor adhesion and scar tissue.

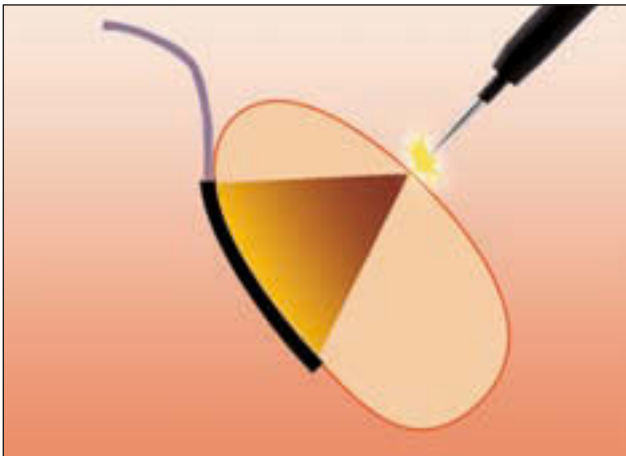


Fig. 5
The return electrode plate provides an adequate contact area.

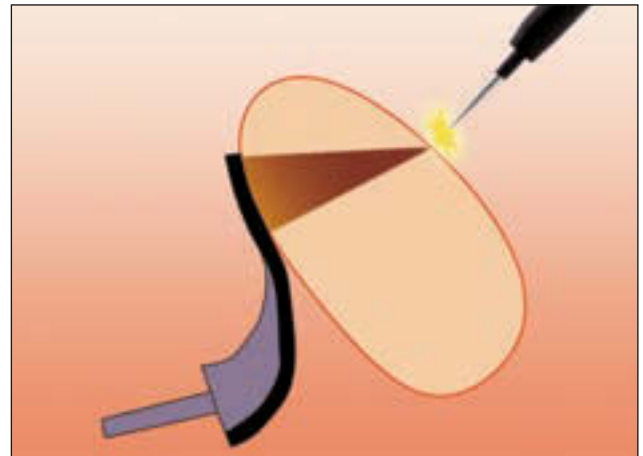


Fig. 6
If the plate contact is faulty, the density of the return current increases dangerously and with it the risk of local burns.

- Check the plate site, which should be a well vascularized muscle mass. Avoid irregular bony contours and bony prominences. The incision site, patient positioning and any other equipment connected to the patient should also be considered.

- **Patient electrode plate monitoring.**

Contact quality monitoring was developed to protect patients from burns due to inadequate contact of the return electrode. Plate site burns are caused by a decreased contact area at the return electrode site. New generators

are equipped with patient plate monitoring, which actively monitors the amount of impedance at the patient/plate interface because there is a direct relationship between this impedance and the contact area. The system is designed to deactivate the generator before an injury can occur if it detects a dangerously high level of impedance at the patient/plate interface.

In order to work properly, such generators must use a patient return electrode that is compatible. This type of electrode is divided into two separate areas.

3.4 Direct Coupling

Direct coupling occurs when the user accidentally activates the generator while the active electrode is near another metal instrument. The secondary instrument will become energized. This energy will seek a pathway to complete the circuit to the

patient return electrode. There is a potential risk of significant patient injury. The generator should not be activated while the active electrode is touching or in close proximity to another metal object.

3.5 Insulation Failure

Many surgeons routinely use the coagulation current. This waveform has a relatively high voltage. This voltage or “push” can spark across an area of compromised insulation. Moreover, high voltage can “blow holes” in weak insulation. Breaks in insulation can create an alternative route for the current to flow. If this current is concentrated, it can cause significant injury.

The surgeon can obtain the desired coagulation effect without high voltage, simply by using the “cutting” current while holding the electrode in direct contact with tissue. This technique will reduce the likelihood of insulation failure. Recall that coagulation can be obtained with the cutting current by holding the electrode in direct contact with tissue, thereby lowering the current density. By lowering current density the rate at which heat is produced is reduced, allowing effective coagulation with the cutting current.

3.6 Capacitive Coupling during Laparoscopy

Metal trocar system

A capacitor is not a part labeled “capacitor” in an electrical device. It occurs whenever a nonconductor separates two conductors. During laparoscopy an “inadvertent capacitor” may be created by the surgical instruments. The conductive active electrode is surrounded by nonconductive insulation. This, in turn, is surrounded by a conductive metal trocar. A capacitor creates an electrostatic field between the two conductors and, as a result, a current in one conductor can, through the electrostatic field, induce a current in the second conductor. In laparoscopy a capacitor may be created by the composition and placement of the surgical instruments.

Plastic trocar system

Capacitance cannot be entirely eliminated with an all-plastic cannula. The patient’s conductive tissue completes the definition of a capacitor. Capacitance is reduced, but is not eliminated.

Hybrid trocar system

The worst case occurs when a metal cannula is held in place by a plastic anchor (hybrid cannula system). The metal cannula still creates a capacitor with the active electrode. However, the plastic abdominal wall anchor prevents the current from dissipating through the abdominal wall. The capacitive coupled current may exit from adjacent tissue on its way to the patient return electrode. This can cause significant injury.

4.0 Recommendations for Avoiding Electrosurgical Complications in the Patient During Operations

The majority of potential problems can be avoided by following these simple guidelines:

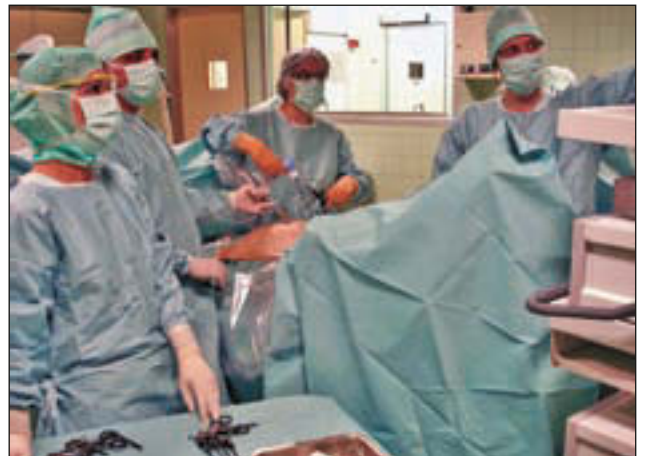- Inspect all the insulation carefully
- Use the lowest possible power setting
- Use a low voltage waveform (cutting)
- Use brief intermittent activation rather than prolonged activation
- Do not activate in an open circuit
- Do not activate in close proximity to or direct contact with another instrument
- Use bipolar electrosurgery where possible
- Select an all-metal trocar system as the safest option and do not use hybrid trocar systems that combine metal with plastic.

Recommended Reading

1. BAGGISH MS: Is it necessary to repeat history? *J Gynecol Surg* 1989; 5: 323
2. BAGGISH MS, TUCKER RD: Tissue actions of bipolar scissors compared with monopolar devices. *Fertil Steril* 1995; 63: 422–6
3. BERGDAHL B, VÄLLFORS B: Studies on coagulation and the development of an automatic computerized bipolar coagulation. *J Neurosurg* 1991; 75: 148–51
4. BÜHLER K, KATO K, KLESSEN C, KOCH R, et al.: Die temperatur-geregelte bipolare Elektrokoagulation *Zent bl Gynäkol*, 1991; 113: 713–22
5. CORSON SL: Electrosurgical hazards in laparoscopy. *JAMA* 1974; 227: 1261–3
6. CUSHING H: Electrosurgery as an aid to the removal of intracranial tumors. *Surg Gynecol Obstet* 1928; 47: 751–84
7. CURCIE DJ, CRAELIUS W: The role of thermal feedback in electrosurgical tissue heating. *Tech Health Care* 1995; 3: 111–6
8. Di GIOVANNI M, VASILENKO P, BELSKY D: Laparoscopic tubal sterilization. The potential for thermal bowel injury. *J Reprod Med* 1990; 35: 951–4
9. FARNWORTH TK, BEALS SP, MANWARING KH, TREPETA RW: Comparison of skin necrosis in rats by using a new microneedle electrocautery, standard-size needle electrocautery and the shaw hemostatic scalpel. *Ann Plast Surg* 1993; 31: 164–7
10. GIORDANO BP: Don't be a victim of surgical smoke. *AORN J* 1996; 63: 520–22
11. GOLDWYN RM: Bovie. The man and the machine. *Annals Plast Surg* 1979; 2: 135–53
12. GROSSKINSKY CM, RYDER RM, PENDERGRASS HM, HULKA JF: Laparoscopic capacitance: A mystery measured. *Am J Obstet Gynecol* 1993; 169: 1632–5
13. HOGLAN M: Potential Hazards from electrosurgery plume. Recommendations for surgical smoke evacuation. *Can Oper Room Nurs J* 1995; 13: 10–6
14. HUKKI J, LIPASTI J, CASTREN M, PUOLAKKAINEN P, et al: Lactate dehydrogenase in laser incisions. *Laser Surg Med* 1989; 9: 589–94
15. KAPLUN A, ARONSON M, HALPERIN B, GRIFFEL B: Cellular events in adhesion formation due to Thermal Trauma. *Eur Surg Res* 1984a; 16: 136–40
16. KAPLUN A, GRIFFEL B, HALPERIN B, ARONSON M: A model for adhesion formation by thermal injury in the abdominal cavity of the mouse. *Eur Surg Res* 1984b; 16: 131–5
17. KOCKS J: Eine neue Methode der Sterilisation der Frau. *ZBL Gynäk* 1878; 2: 617
18. LEVY BS, SODERSTROM RM, DAIL DH: Bowel injuries during laparoscopy. Gross anatomy and histology. *J Reprod Med* 1985; 30: 168–72
19. LUCIANO AA, WHITMAN G, MAIER DB, RANDOLPH J, et al: A comparison of thermal injury, healing patterns, and postoperative adhesion formation following CO₂ laser and electromicrosurgery. *Fert Steril* 1987 48: 1025–9 1987
20. LUCIANO AA: Power sources. *Obstet Gynecol Clin N Am* 1995; 22: 423–43
21. MECKE H, SCHÜNKE M, SCHULZ S, SEMM K: Incidence of adhesions following thermal tissue damage. *Res Exp Med* 1991; 191: 405–11
22. NIELSEN PH, NYLAND MH, ISTRE O, MAIGAARD S, et al: Acute tissue effects during transcervical endometrial resection. *Gynecol Obstet Invest* 1993; 36: 119–23
23. O'CONNOR JL, BLOOM DA: William T. Bovie and electrosurgery. *Surgery* 1996; 119: 390–6
24. ODELL RC: Electrosurgery: principles and safety issues. *Clin Obstet Gynecol* 1995; 38: 610–2
25. PEREIRA FEL: Degenerações. Morte celular. Alterações do interstício. In: BRASILEIRO FILHO, G.; PITTELLA, J.E.H.; PEREIRA, F.E.L.; BAMBIRRA, E.A.; BARBOSA, A.J.A – *Bogliolo Patologia*. 5ª ed. Rio de Janeiro, Guanabara Koogan 1996., p.46–81.
26. RAPPAPORT WD, HUNTER GC, ALLEN R, LICK S, et al.: Effect of electrocautery on wound healing in midline laparotomy incisions. *Am J Surg* 1990; 160: 618–20
27. RIEDEL HH, SEMM K: An initial comparison of coagulation techniques of sterilization. *J Reprod Med* 1982; 27: 26 1–7
28. RIEDEL HH, LEHMANN-WILLENBROCK E, MECKE H, AHMELS E: Histologische und enzymhistochemische Untersuchungen am Kaninchenuterushorn nach anwendung unterschiedlicher Koagulationsmethoden. *Zent bl Gynäkol* 1990; 112: 189–205
29. RYDER RM, HULKA JF: Bladder and Bowel injury after electrodesiccation with Kleppinger Bipolar forceps. *J Reprod Med* 1993; 38: 595–8
30. SODERSTROM RM: Principles of Eletrosurgery During Endoscopy. In: Sammarco MJ, Stovall TG, Steege JF. *Gynecologic Endoscopy*. Baltimore, 1996, Williams & Wilkins, p. 179–92.
31. SEMM K: Endocoagulation: A new and completely safe medical current for sterilization. *Int J Fertil* 1977; 22: 238
32. SIGEL B, DUNN MR: The mechanism of blood vessel closure by high frequency electrocoagulation. *Surg Gynecol Obstet* 1965; October: 823–31
33. TUCKER RD, STASZ PS, KRAMOLOWSKY EV: A simple and inexpensive method for measuring electrosurgical variables. *Biomed Instrum Tech* 1989; 23: 54–7
34. TUCKER RD, KRAMOLOWSKY EV, PLATZ CE: In vivo effect of 5 french bipolar and monopolar electrosurgical probes on the porcine bladder. *Urol Res* 1990; 18: 29 1–4
35. TUCKER RD, BENDA JA, MARDAN A, ENGEL T: The interaction of electrosurgical bipolar forceps and generators on an animal model of fallopian tube sterilization. *Am J Obstet Gynecol* 1991; 165: 443–9
36. VECK S: An introduction to the principles and safety of electrosurgery. *Br J Hosp Med* 1996; 55: 27–30
37. VOYLES CR, TUCKER RD: Education and engineering solutions for potencial problem with laparoscopic monopolar electrosurgery *Am J Surg* 1992; 164: 57–62
38. WERNER R: Sterilisierung der Frau durch Tubenverkochung. *Chirurg* 1934; 6: 843–5

Chapter III
Ergonomics in Laparoscopy

Arnaud Wattiez
Strasbourg University Hospital
Strasbourg, France



1.0 Introduction

The late 1980's were revolutionary years for laparoscopy. In 1989 we believed that we were on the verge of major development. Despite the undisputable enthusiasm at the beginning, laparoscopic surgery did not develop as expected.

Two studies, one in France by the SFEG and one in the USA, reveal that less than 10% of surgeons perform less than 10% of complicated operations by laparoscopy. The major arguments against laparoscopic surgery are its difficulty and its duration, in other words its technicality and low productivity. In order to solve these problems, laparoscopy must be regarded not just as a surgical access but as a surgical technique with its own anatomy, ergonomics and methodology. We need to analyze and understand the specific features of laparoscopy in order to simplify and speed up surgery.

We have shown that operating times and complication rates can be significantly reduced. In a comparative study of 695 laparoscopic hysterectomies performed by experts during the years 1989–1995 versus 952 more performed by experts and junior surgeons between 1996 and 1999, the mean operating time was reduced from 115 minutes (40–270 min) to 90 minutes (40–180 min), while complications were also reduced.

Productivity is influenced by the conditions imposed. For example, while laparotomy scissors can cut a few centimeters in one stroke, in laparoscopy ten strokes would be needed to cut the same distance.

In order to overcome the inherent low productivity of laparoscopy, we must study its specific features in order to emphasize its advantages and minimize its inconveniences. Simply working faster will not be sufficient.

We have studied our surgical methods both in terms of quantity and quality to improve the working conditions and thus increase productivity. This has led to an improved interaction between function, equipment and the user.

Laparoscopy is different from other modes of surgery because what the surgeon sees on the screen during laparoscopy is just a representation of reality: the size, the colors and dimensions are not the real ones. This quality, which we call "virtuality", has many benefits and drawbacks. The major inconvenience is that decisions and actions taken by the surgeon are not based on real data, and so misrepresentation of the data, e.g., because of a technical problem, can lead to incorrect decisions. The major advantage is that it provides a unique opportunity to "virtualize the difficulties" for time-sequenced reconstruction and post-simulation analysis.

Understanding the concept of the virtuality of laparoscopy will allow the surgeon to improve productivity and thus speed up his surgery.

The characteristics of the virtuality of laparoscopy have advantages and disadvantages. These are listed in **Table 1**.

The basic rules for obtaining the best results are as follows (**Table 2**):

Specific Feature	Advantages	Disadvantages
The surgeon's "eye" is situated at the tip of the optic trocar	Constant relation between eye/instrument/tissue	Blind spot behind the lens: danger (?) Vision can be impaired in various ways
Optic/videoendoscopic vision depends on local conditions (bleeding, distance, color of organs, etc.)	Increase in magnification, illumination	Lack of third dimension, precise but small operative area
Small ports – do not confuse small incisions with small dissections	Faster healing and recovery	Slow reaction to acute situations

Table 1

The surgeon's eye is situated at the tip of the primary trocar. Never take your eyes off the screen when the situation is not stable.		
Organization of the operating field <ul style="list-style-type: none"> • Position of the primary trocar • Accessory trocars • Type of trocar and insertion • Trocar size 	Instrumentation Surgical strategy <ul style="list-style-type: none"> • Strict hemostasis • Do not irrigate (only use suction) • Correct position of the laparoscope • Optimal use of accessory trocars. 	<ul style="list-style-type: none"> • Selecting information • Surgeon's ergonomics and convenience • Quality of image • Staff training • Preoperative preparation

Table 2

2.0 The Surgeon's Eye is Situated at the Tip of the Primary Trocar. Never Take your Eyes off the Screen When the Situation is Not Stable!

Vision in laparoscopy is not direct but virtual. Working on structures situated deep in the pelvis is often difficult in laparotomy because they appear small and distant. As the laparoscopic surgeon can virtually move "his eyes" forward into the abdominal cavity, he is able to maintain a constant size ratio between the tissue, the instruments and the eye. Thus, simply by use of the laparoscope, he can reach and work on the muscles of the pelvic floor as easily as on the adnexa.

By using the constant relationship between eye/instrument/tissue and peritoneum, the laparoscopic surgeon can gain entry to and operate in small cavities that are not accessible by other surgical routes. For instance, by advancing the laparoscope and operating instruments down to the pouch of Douglas, the surgeon can work in the pararectal region.

Taking one's eyes off the screen, especially when the surgical situation is not stable, means losing time. Unfortunately, this is often the case. For example, in the case of bleeding, many surgeons reach for the suction probe before completing hemostasis. The assistant tries to help and loses hold of the video camera. This brings the camera directly in contact with the abdominal wall, it gets soiled, and as a result, endoscopic vision is impaired. Precious time is lost and in some situations conversion to laparotomy is required. The bleeding

must first be controlled by coagulation and/or direct pressure on the vessel, using the instrument in hand. All members of the surgical team must keep their eyes on the screen (**Fig. 1**). Only after the bleeding is controlled should the suction cannula be introduced into the peritoneal cavity and the camera be cleaned.

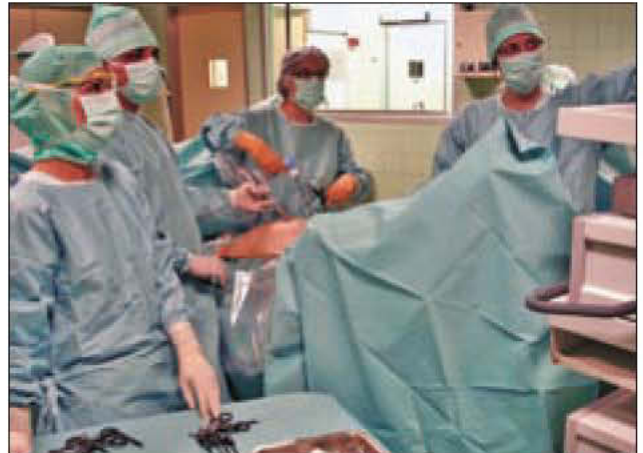

Fig. 1
Surgical team.

3.0 Organization of the Operating Field

To avoid taking one's eyes off the screen, the surgeon must be able to see everything he/she needs. This means that all the necessary information, the instruments and the screen must be in the surgeon's line of vision. Equipment should be arranged in relation to its use and all the important instruments should be on the operating field and always in the same place. Sterile pockets hanging at the side of the operating table next to the operating field can be used for

storage of instruments employed most often while all other instruments can be placed on the standard instrument tray (**Figs. 2-3**). This allows the surgeon to reach for an instrument without taking his eyes off the screen and without having to change the position of the instruments. It is a bit like knowing where the light switch is in your room and turning on the light automatically when the room is in complete darkness.

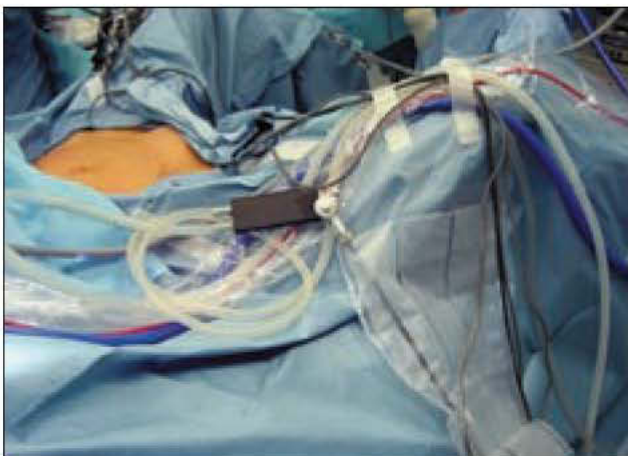

Fig. 2
Sterile pockets hanging at the sides of the operating table next to the operating field allows frequently used instruments to be readily kept available during surgery.

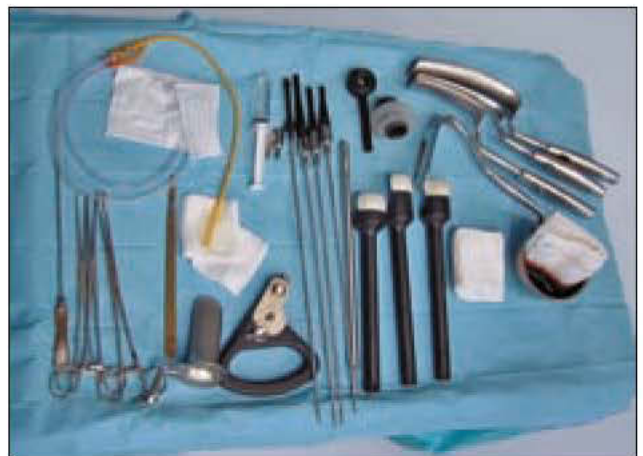

Fig. 3
Instrument tray for the vaginal approach.

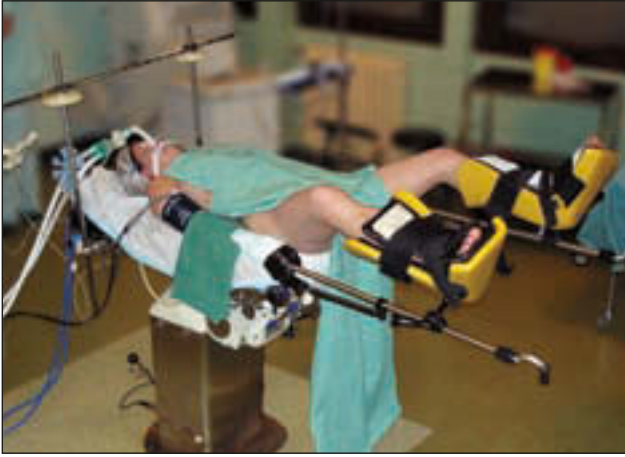

Fig. 4
Position of the patient on the operating table.

The operating column should be arranged in such a way that the surgeon can see the insufflator and electro-surgical generator while the suction/irrigation unit, video equipment etc. do not have to be in sight.

The operating room must be well-illuminated for safety reasons. This will help in finding the instruments faster or performing unusual tasks. A good video system is of crucial importance.

Once the patient is positioned, the movability of all members of the operating team should be assessed. The patient should be placed relatively far down on the operating table to allow the full range of movements for the manipulator. The legs should be flexed and abducted enough to give the second assistant enough room but not so much as to interfere with the other surgeons (**Fig. 4**). The arms should be alongside the body. For obvious reasons, this is often disputed by the anaesthetists, who prefer to have easy intravenous access, continuous blood pressure and oxygen saturation monitoring etc. We believe, that there should be no compromise such as having the arm on the surgeon's side alongside the patient and the other at a right angle to the body because the ergonomics and comfort of the assistant are fundamental.

Great attention must be paid to make sure that cables and tubes are not intertwined behind the surgeons in order to avoid wasting time in disconnecting them every time the surgeons change places. Letting the assistant perform some of the operating steps is an alternative to changing places, which can be used in small operating rooms.

The number, position and quality of the screens are extremely important. A clear view will enhance the precision and speed of surgery. A clear image of appropriate size reduces eyestrain if the screen is placed at a distance of 0.6 to 6 times the screen's diameter. The screens should not be situated so high as to necessitate acrobatic neck movements, but not so low that the view of the screen is impeded. Ideally, laparoscopic pelvic surgery requires that there be two screens close to the patient's legs (**Fig. 5**).

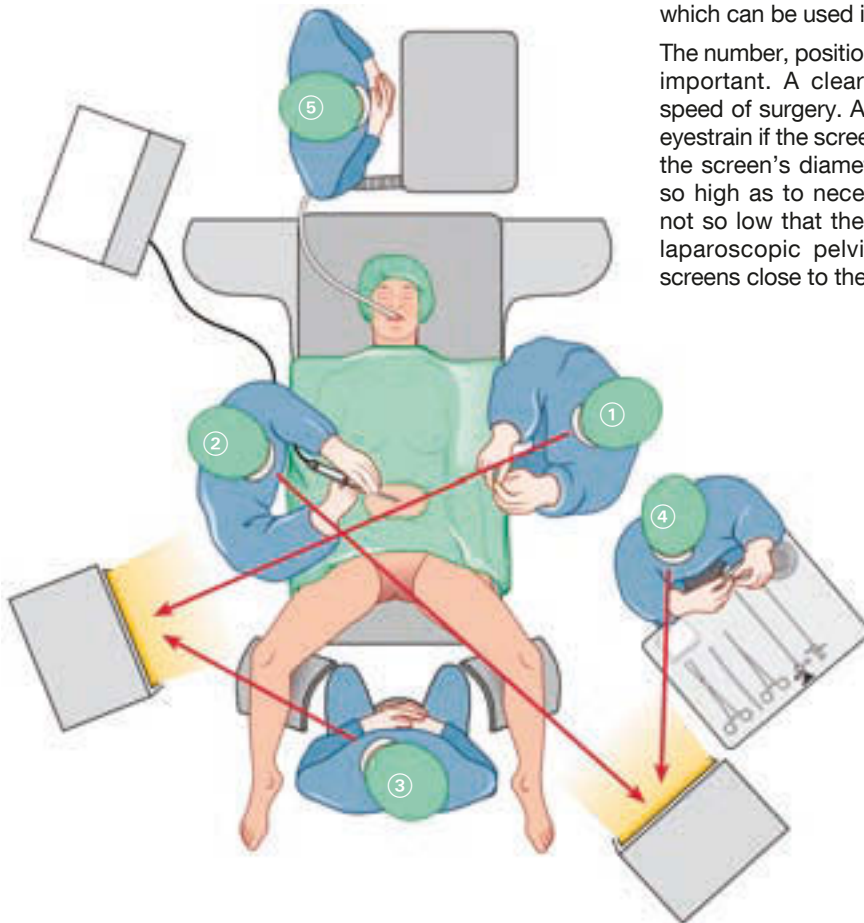
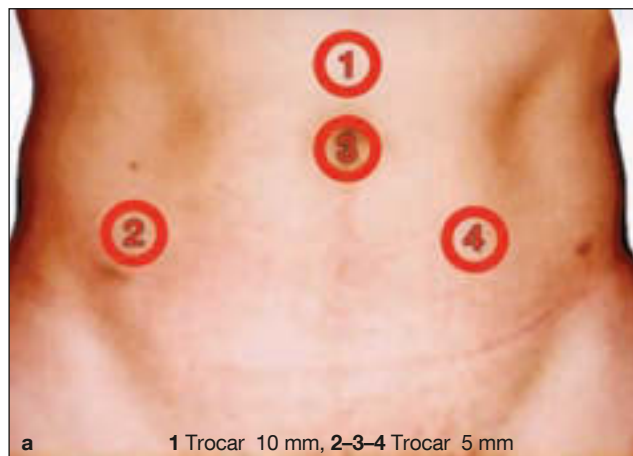


Fig. 5
The position of the two monitors allows the surgical team and the nurse to see the screen.
① – operating surgeon; ② – first assistant; ③ – second assistant; ④ – scrub nurse; ⑤ – anaesthesiologist.

Hysterectomy



Myomectomy

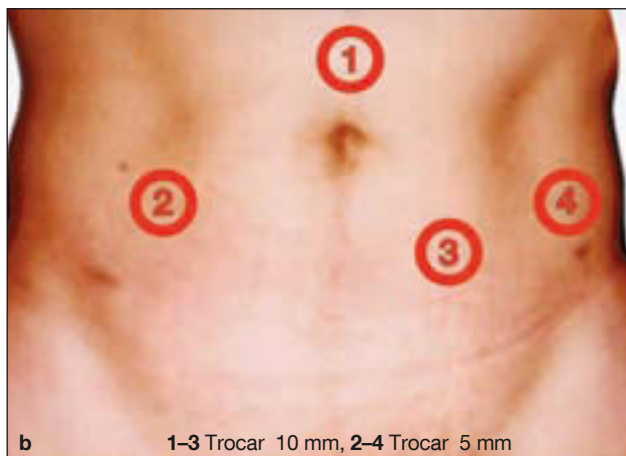


Fig. 6a, b

Trocar ports in the case of a bulky uterus.

3.1 Position of the Primary Trocar

Virtuality has the great advantage that the image can be assessed and changed, if the visual field is inadequate. For example, during hysterectomy, after inserting the primary trocar, a mass blocking the view from side to side may be found in the case of a bulky uterus. There are three solutions to this situation. The first is to give a GnRH analogue for 3 months and then re-operate. The second is to convert to laparotomy. The third solution is to change the position of the

trocar. If the trocar is in sub-xyphoid position, the uterus will look smaller and vital structures (such as the uterine arteries) will appear in a better position to allow vision (**Fig. 6**). Another option is to change from a 0°-straight forward laparoscope to a 30°-forward-oblique scope to enable surgery on the uterine arteries or the utero-sacral ligaments. By virtualizing the difficulties, operating times can be reduced.

3.2 Accessory Trocars

The number of trocars: four hands are usually available for surgery (if optic robots are not used) so the time dedicated to placing more than four trocars is wasted time. The surgeon involved in the pre-operative planning must carefully consider and set up the points of trocar insertion. We normally use four trocars for all laparoscopic procedures including adnexal surgery (**Fig. 7**). Using this method systematically is helpful in anticipating the procedure and reducing operating times. On the other hand, adding a fifth trocar can be justified if this facilitates or shortens the operation.

The position of the trocars: did you ever stop to think why laparoscopic instruments are 43 cm in length? The abdominal wall acts as a lever for the trocar. The balance between force (= fatigue) and precision depends on the ratio between the intra-abdominal and the extra abdominal part of the instrument: the more the ratio is shifted in favor of the extraabdominal part, the more precision will be gained, but the greater length means larger movements of the hands, which brings on fatigue more rapidly. Unfortunately, many consider this ratio to be constant although it is not.

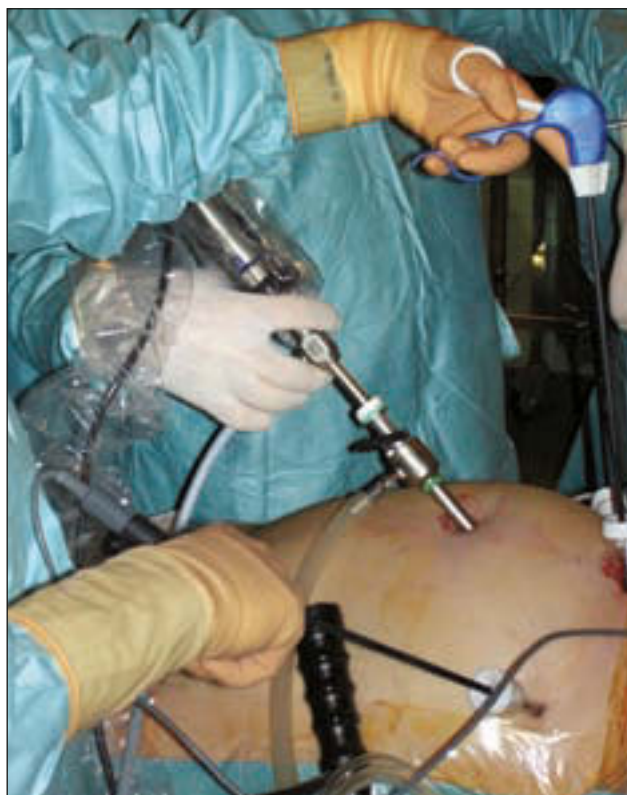

Fig. 7

Positioning the trocars for 4 hands.

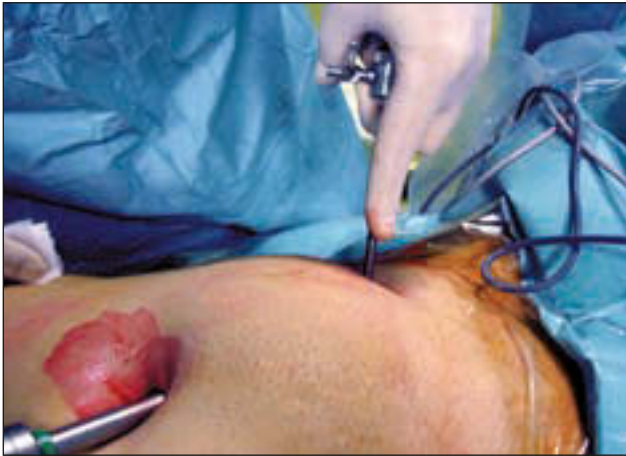

Fig. 8
Introduction of the accessory trocar.

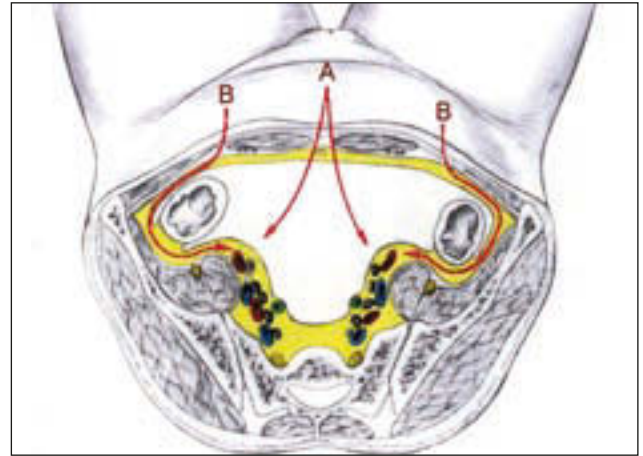


Fig. 9
Topographical anatomy of vessels and organs relative to the trocar's angle of insertion.

The afore-mentioned ratio can be altered easily by shifting the point of trocar insertion away from the operating field (e.g. cranially in the midline during pelvic operations).

Consequently, the trocar site must be different for delicate procedures such as tubal surgery and for those requiring force such as myomectomy or Burch's operation. The most efficient balance is achieved when the ratio is 1:1, because the hand can feel the pressure of the tissue and the force exerted. With any other ratio, this feeling is lost. This is why it is important to take your time to plan each point of trocar insertion; this time is not wasted. Symmetrical insertion is not important.

3.3 Type of Trocar and Mode of Insertion

There are many trocar types available today; each surgeon must be familiar with those that best answer his needs. A very important property that is often forgotten is being able to introduce instruments into the trocar without looking away from the screen. For this to happen, the trocar must be at a right angle to the skin when there is no instrument inside it and it must have a wide opening. This means that trocars

Other ergonomic rules, which may shorten operating times, are: placing two lateral trocars in a triangle with the primary trocar, never introducing more than one trocar parallel to the primary trocar, taking into account the axis of work and angles of approach (especially while suturing), etc. Remember, that the right lower quadrant trocar is usually controlled by the assistant, so the assistant's parameters as well as the anticipated function and level of the port must be considered during pre-operative planning. Letting the assistant perform some tasks that are better performed from his side (e.g. right uterine artery coagulation during hysterectomy) eliminates the need for the surgeon to change sides.

should be inserted not in the direction of the pelvis but at a right angle to the skin, the muscles and the aponeurosis, as shown in **Figs. 8** and **9**. We use disposable trocars with valves that permit suturing without CO₂ leakage. Other surgeons, who frequently apply monopolar electrosurgery during which a lot of smoke is generated, prefer a trocar with a valve that allows to connect a smoke evacuation system.

3.4 Trocar Size

Using 5 mm-instruments in a 11-mm trocar with a reducer will impair precision of handling. When an instrument of appropriate size is used, the contact point between the trocar and the abdominal wall corresponds with the pivot point, whereas the use of an instrument of smaller diameter involves that there are two contact points with the trocar (in the reducer and at the trocar tip). A third contact point is located between the trocar and the abdominal wall, and between the trocar and the reducer. As a result, there are two pivot points, one between the trocar and abdominal wall, and the other

between the trocar and the reducer. This condition inherently entails imprecision. It is better to begin the operation with 5 mm-trocars and change to 11 mm-trocars when a 10 mm-instrument is needed. Changing the trocar to 11 mm for suturing is not done automatically and depends on the number of sutures. If the need arises to make four or less sutures, it is preferable to maintain the small incisions for faster suturing although it is essential to change the trocar if a greater number of sutures is required.

4.0 Instrumentation

4.1 Multifunctional Instruments

The three basic actions are dissection, hemostasis and cutting. All of these actions can be performed easily when multifunctional instruments are used (such as bipolar forceps or monopolar scissors) in the following order:

The surgeon holds the bipolar forceps in one hand and curved scissors, connected to the monopolar electro-surgical generator, in the other. In this way, the dominant hand is able to dissect, grasp, apply traction and coagulate while

the non-dominant hand can cut (mechanically or electrically), coagulate by use of monopolar technique, lateralize and dissect. Thus, the surgeon is able to perform nine different actions and rarely needs to change instruments so as to enable performing a specific action. There are other acceptable ways of holding laparoscopic instruments provided this is done logically.

4.2 Maintenance of Instruments

Appropriate, fully functioning instruments shorten operating times and prevent complications. Scissors must always cut properly and bipolar forceps must always be kept clean. Having a second bipolar forceps readily available allows the

clean instrument to be used at all times without delay. Every surgeon must be responsible for checking the condition of the instruments in use to ensure their effective function.

5.0 Surgical Strategy

Surgical strategy must be logical and strict but always modifiable. It should be decided upon during the first few minutes of the operation immediately after examining the operating field. It is not rare to see surgeons start on one side and then change sides when faced with an obstacle that frequently

needs to be overcome, and probably could have been anticipated through careful strategy planning. An operation with a lot of stops, changes and pauses is much slower than a planned operation. Because of its special nature, laparoscopy requires that a few basic rules be observed.

5.1 Strict Hemostasis

Bleeding interferes with surgical maneuvers. In laparotomy and vaginal surgery the management of minor bleedings without hemodynamic significance may be delayed with the temporary placement of a suction tube nearby. This is not the case in laparoscopy, because the technique depends completely on boundary conditions such as video camera and lighting system, confined working space, the few operating ports and the inherent difficulty associated with the need for changing instruments.

This is why strict and meticulous hemostasis is essential in laparoscopy. Meticulous dissection and coagulation, anatomical cleavage planes, perfect knowledge of anatomy and good proficiency in bipolar coagulation are the basic competences needed to translate the appropriate laparoscopic strategy into practice.

5.2 Do not Irrigate (Apply Only Suction) !

This statement may sound strange to many laparoscopic surgeons because lavage has been used extensively for over 20 years. It is clear, that there are situations which require lavage, such as in the event of extensive hemorrhage or at the end of the surgery, but lavage also has disadvantages:

- loss of exposure: the operating space is reduced when it is filled with liquid and pneumoperitoneum pressure decreases when it is suctioned out. Light is absorbed and reflected by the liquid
- loss of anatomical planes due to tissue edema

- loss of electrical efficiency when an electrolyte solution is used
- spread of the liquid throughout the abdominal cavity, which is particularly hazardous in the presence of malignancy, infection and dermoid cysts.

Finally, suction and lavage are time-consuming procedures.

To avoid lavage, the surgeon must follow a surgical strategy that allows to avoid situations where the use of irrigation is indispensable.

5.3 Correct Position of the Laparoscope

The lack of a third dimension becomes more obvious when the image is distant and at the periphery of the screen. The tip of the instrument must be kept as close as possible to the center of the screen. When suturing distant structures such as the levator ani, one should try to keep the needle holder

close to the distal lens of the laparoscope in order to align the needle correctly.

Since red absorbs colors, blood should be aspirated as soon as possible as it reduces brightness.

5.4 Optimal Use of Accessory Trocars

Trocars should never be used to mobilize an organ that obscures vision. This can be the case with the sigmoid during prolapse surgery, with the adnexa during excision of a rectovaginal nodule and may also occur during uterovaginal prolapse surgery after subtotal hysterectomy. If a trocar is used to mobilize these organs, it is lost for surgery along with the aid of the assistant who assumes a static role and may lose his/her concentration. It also constitutes a source of risk and harm when it is outside the operating field.

Alternative strategies include:

- tilting the operating table,
- suspension to the abdominal wall
- the use of an uterine manipulator.

These measures, applied at the beginning of the operation, take a few seconds and can save precious time during surgery.

6.0 Selecting Information

During laparoscopy the surgeon should select the essential information required for the work and ignore what is not useful as it may interfere with the concentration. By doing so the surgeon is able to anticipate difficulties, as will be explained below.

For methodological reasons, information is divided into on-screen and off-screen information.

7.0 Surgeon's Ergonomics and Convenience

During lengthy operations the surgeon suffers from muscular strain and fatigue. This can cause errors and slowness. Research has shown that muscles can work for hours if they employ 15% of their maximum strength but they will fatigue if they use more power. In a recent study, we demonstrated that highly proficient surgeons, aware of surgical ergonomics, use about 15% of the muscle strength of their arms and shoulders while less experienced surgeons use a higher percentage of their muscular strength. Application of ergonomic principles reduces the amount of muscle power applied during surgery, which will reduce fatigue and enhance safety and operating times.

The operating table position and height are of great importance in laparoscopic surgery. The table should be low enough for the surgeon and allow a proper working position to reduce fatigue. The correct arm position should be with the arm lying alongside the chest with the elbow at an angle of 90 degrees or more. The height of the abdomen should also be considered. Since most operating tables are manufactured for laparotomy, it is often necessary to use a foot support, which must be wide enough for the surgeon's feet and the pedals.

In laparoscopy as in laparotomy, the hands must be in the middle of the operating field. In other words, the screen must be aligned in the same visual direction as the operating field. If this is not the case, the surgeon will be operating at a different angle from the one shown on the screen. This will impair orientation and can result in protracted, clumsy movements, and prolonged duration of surgery.

The axis between the screen, the surgeon's hands and the surgeon's eyes should be kept as straight as possible. The greater the shift, the greater is the distortion of the movements. We can draw two lines, one between the surgeon's eyes and the screen, and one between his eyes and hands. The greater the angle between those lines, the more distorted are the directions. The distortion is very noticeable at angles greater than 60 degrees. In case of a right angle (90°), e.g., from the patient's right, the instrument must be pushed in order to achieve a movement to the left. This lack of orientation makes the surgeon's movements slow and imprecise.

To sum up, two screens positioned nearby the patient's legs should be used during pelvic operations, as shown in **Figs. 10 and 11**.

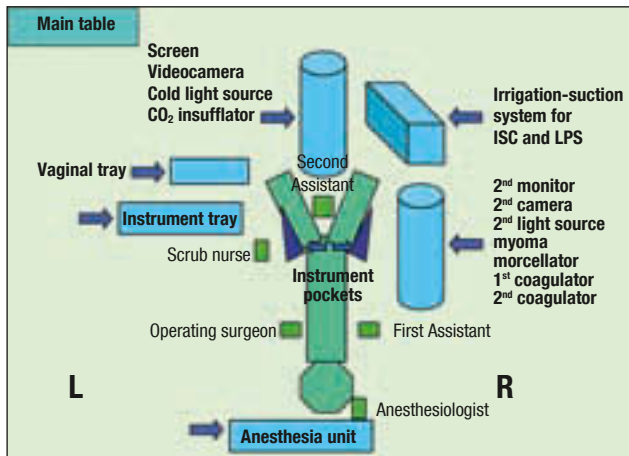


Fig. 10
Operating room set up.

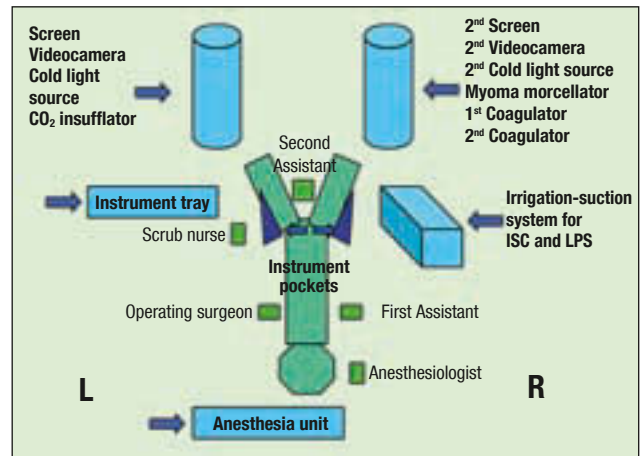


Fig. 11
Alternative operating room setup.

8.0 Quality of the Image

To obtain good quality information from the video screen, the best possible video technology should be used. In short, we use IMAGE1™ (KARL STORZ Tuttlingen, Germany) or a 3-CCD video camera connected to a xenon cold light source

and a 21-inch flatscreen monitor. The screen must be coupled directly to the video camera via the best available connection (RGB, YC or PAL/NTSC). If RGB is not available, the cables should be as short as possible.

9.0 Staff Training

Staff training and regular equipment checks are obvious though often overlooked measures for speeding up surgery.

To reduce operating times, it is very important to have an active and well-trained theater nurse who holds the trocar straight while instruments are changed, who puts the right

instrument in the right trocar opening at the right time, who is always ready for the next step and who has the needle holders loaded inside a trocar before suturing begins, allowing the surgeon to keep his eyes on the screen.

10.0 Preoperative Preparation

- **Bowel preparation:** a low fiber diet for 7 days prior to surgery will assist good exposure of the operative field. Properly prepared bowels take up less space, are easier to retract and slide into the pelvis less. On the other hand, preparation with liquids the evening before surgery fills the bowel with liquid and has the opposite effect. For this reason, we do not recommend this type of preparation if opening the intestine is unlikely, as in the case of simple hysterectomy.
- All of the equipment used for laparoscopic surgery, including more rarely used instruments such as cystoscopes, ureter catheters and instruments for intestinal surgery, should be readily available within a short time. Special procedures and personnel, such as needed, e.g., for the frozen section technique, must be available on standby.

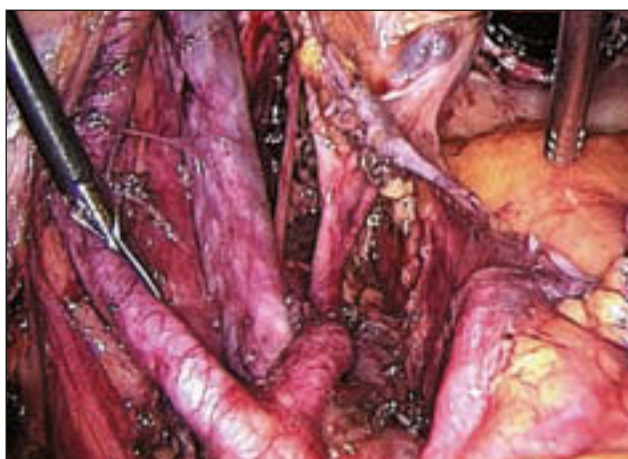
Chapter IV

Gynecologic Laparoscopic Surgical Anatomy

**Cristiana Barbosa¹, Arnaud Wattiez²
and Luca Mencaglia¹**

¹Centro Oncologico Fiorentino, Florence, Italy

²Strasbourg University Hospital
Strasbourg, France



1.0 Introduction

Laparoscopy allows a highly magnified and close-up view of the abdominal and pelvic cavity, making it possible to visualize and study the anatomical structures and pelvic spaces that in the past were difficult to visualize at laparotomy.

2.0 Anterior Abdominal Wall

The anterior abdominal wall is the entrance to the abdominal cavity. The anterior abdominal wall is usually traversed blindly so knowledge of the anatomy is crucial to avoid any complications while doing so.

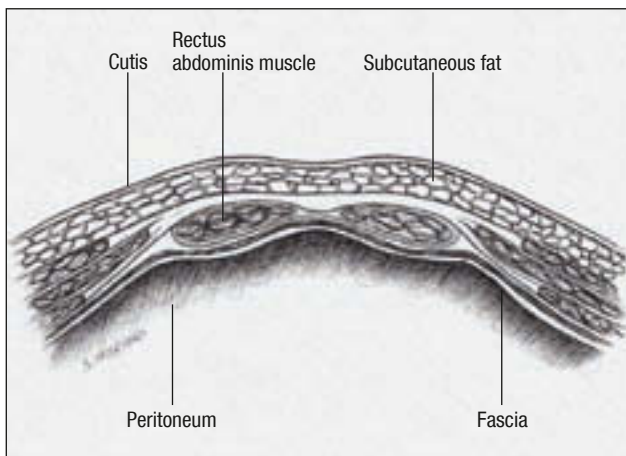


Fig. 1
Drawing of the various anatomical layers of the anterior abdominal wall.

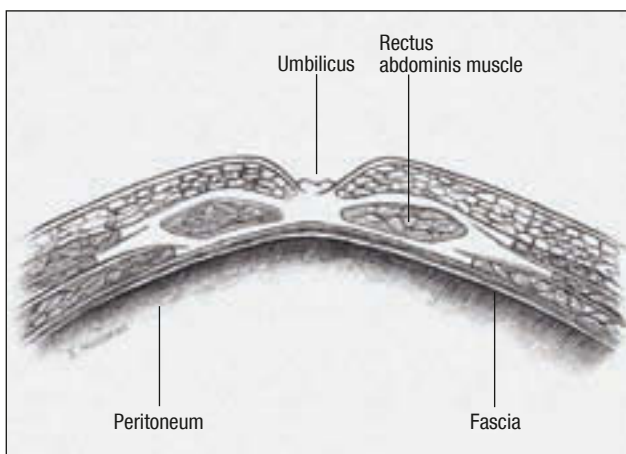


Fig. 2
Drawing of the abdominal wall at the level of the umbilicus.

2.1 Anatomical Area

The anterior abdominal wall is bounded superiorly by the xiphoid process medially and by the inferior margin of the intercostal cartilages of the 7th to 10th ribs. Inferiorly, it is limited by the pubic symphysis and laterally by the inguinal ligament and the anterior superior iliac spine.

2.2 Layers of the Anterior Abdominal Wall

The anterolateral abdominal wall consists of muscle and fascia. From the skin to the peritoneal cavity, there are various layers: the skin, subcutaneous fat, the anterior layer of fascia covering the rectus abdominis muscles medially, the external oblique muscles laterally and the internal oblique and transversus abdominis laterally.

The external oblique is the most superficial of the muscles and the transversus is the deepest in the anterolateral abdominal wall.

Transversalis fascia: covers the posterior layer of the rectus sheath and the transversus abdominis muscle.

The preperitoneal space: contains connective tissue and fat.

Peritoneum: The internal part of the parietal peritoneum is in contact with the internal organs thanks to the negative pressure inside the abdominal cavity.

2.3 The Umbilicus

The umbilicus is located in the midline, usually 2 to 2.5 cm below the level of the tubercles of the iliac crests. The umbilicus is at the level of the intervertebral discs of L3 and L4.

The bifurcation of the abdominal aorta into the right and left common iliac arteries is located a few centimetres below the umbilicus. The left common iliac vein crosses in front of the body of the fifth lumbar vertebra and behind the aortic bifurcation.

In slim patients, the distance between the anterior abdominal wall and the large vessels is short so attention must be redoubled when the principal trocar is being introduced.

It is also necessary to pay attention to the superficial blood supply of the umbilicus, which is usually in the form of a circle to the right of the umbilicus. Because of this, **the umbilical incision is preferably made on the left.**

The difference between the fascia above and below the umbilicus must be recalled. In the upper part, the posterior layer of the internal oblique fascia and the aponeurosis of the transversus abdominis muscle pass behind the rectus abdominis muscles, while the anterior layer of the internal oblique fascia passes in front. Below the umbilicus, all the fasciae pass together anterior to the rectus abdominis muscles (**Figs. 1, 2**). These anatomical relations are important when the Veress needle is introduced during laparoscopy. In fact, if it is introduced **in or below the umbilicus, a distinct tactile sensation is felt when the fascia and peritoneum is crossed.** If it is introduced above the umbilicus, lateral to the midline, **passage through the anterior fascia, posterior fascia and peritoneum can be felt distinctly.**

2.4 Muscle Wall

The rectus abdominis muscles can be identified in the muscle wall. They are located lateral to the midline from the xiphoid process to the border of the pubic symphysis. They are divided centrally by the linea alba, which is a tendinous raphe forming a central groove between the rectus muscles. **The lateral angle of the rectus abdominis muscle is called the semilunar line.** The rectus abdominis muscles have tendinous

The umbilicus is the most suitable site for introducing the primary trocar and the Veress needle because the anterior abdominal wall here contains less subcutaneous tissue and does not contain any muscle, and **the distance between the skin and peritoneum is shortest.**

However, **the umbilicus, entered through its upper part, is the location of choice for "open laparoscopy",** a technique preferred by some and favoured by general surgeons.

The peritoneal layer is adherent with the layers above so once the fascia has been identified, clamped and incised, it is easy to open the serosa bluntly and enter the abdominal cavity using a round-tipped Hasson trocar.

This technique is indicated in patients who have previously undergone pelvic and/or abdominal surgery or where post-inflammatory adhesions are suspected because it allows direct inspection of the structures beneath the trocar's entry site.

intersections, which divide the rectus muscles into segments at the level of the xiphoid process, the umbilicus and between these two points.

The external oblique muscle is located lateral to the rectus abdominis muscle between the lateral part of the lower ribs and the iliac crest. The inferior margin of its fascia forms the inguinal ligament.

2.5 Blood Supply of the Anterior Abdominal Wall

The anterior abdominal wall has a deep and superficial blood supply. **The superficial vascular network is formed by the superficial epigastric artery, the superficial circumflex iliac artery and the corresponding veins.** These vessels are branches of the femoral artery, which emerge caudal to the inguinal ligament. **The epigastric artery runs medial to the rectus abdominis muscles, while the circumflex artery is lateral.** These vessels can be seen by transillumination, especially in thin patients (**Figs. 3–4**).

The deep vascular system is formed by the superior epigastric artery, the inferior epigastric artery and by the deep circumflex iliac arteries and their corresponding veins. The superior epigastric artery is a branch of the internal thoracic artery while the inferior epigastric artery is a branch of the external iliac. They are found beneath the rectus abdominis muscles.

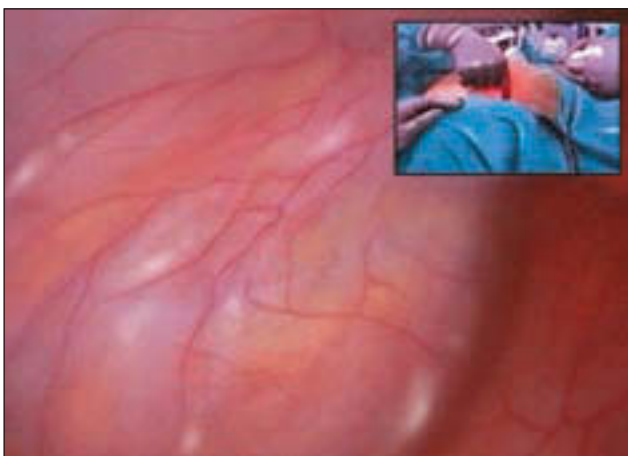

Fig. 3
View of the superficial blood supply of the abdominal wall by transillumination (insert picture showing the external view).

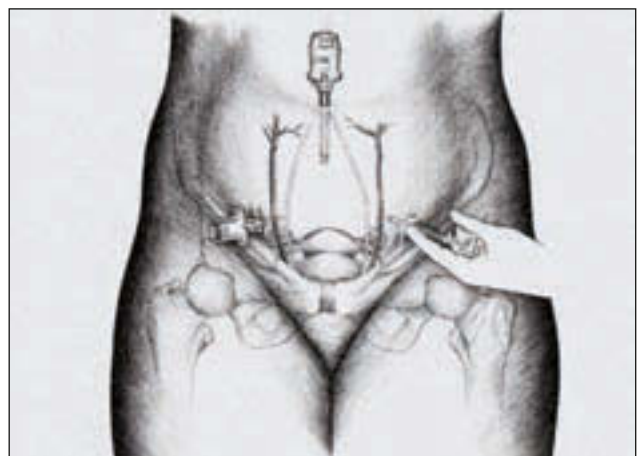


Fig. 4
Drawing of the superficial blood supply of the abdominal wall which can be visualized by transillumination.

3.0 The Uterus

The uterus is located deep in the pelvic cavity. It is pear-shaped and divided into two parts: the upper part, the body, is bulkier and the lower part consists of the cervix (**Fig. 5**). Between these two parts, a transitional zone known as the uterine isthmus is identified; this corresponds to the internal os of the cervix.

The long axis of the uterus corresponds to the axis of the pelvic wall. Since the organ is mobile, its position varies with the possible alterations in the distension of contiguous organs such as the bladder and rectum. There is usually an angle of 100° to 120° between the body and cervix. If this is anterior, it is defined as uterine anteversion, while it is described as retroversion when it is posterior.

The uterus is about 7.5 cm in length, 5 cm in its transverse diameter and about 2.5 cm thick. It weighs about 30–40 gr in nulliparous and 70 gr in multiparous women. It is located between the bladder anteriorly and the rectosigmoid posteriorly. Its upper part is suspended from the round ligaments, while the inferior part is held by the vesicouterine ligaments, the parametria and the uterosacral ligaments bilaterally, which form the “retinaculum uteri” or paracervical ring.

The shape, size, weight and position of the uterus vary according to the different periods of the woman’s life.

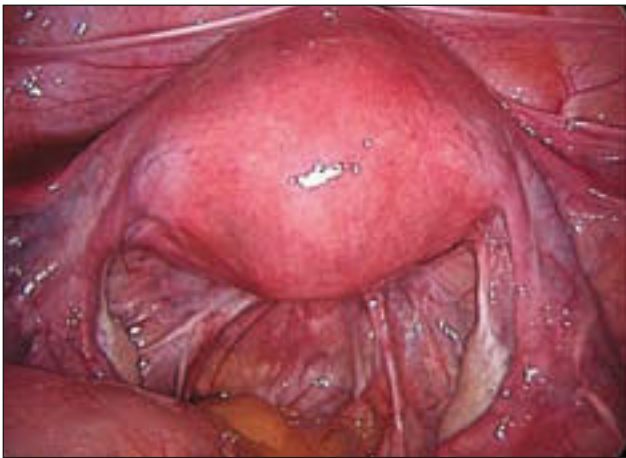

Fig. 5
Uterus, view of the fundus.

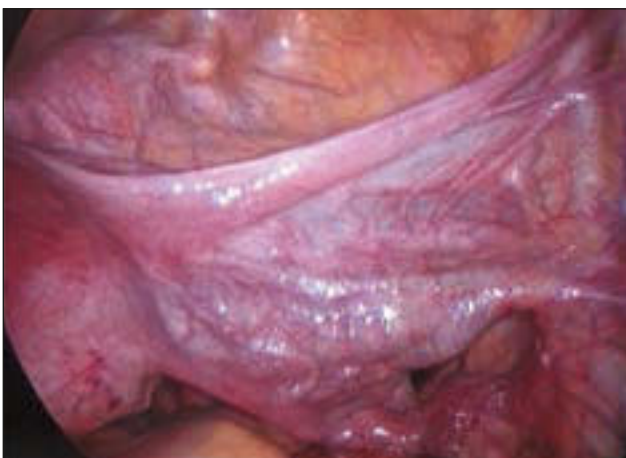

Fig. 6
Broad ligament of the uterus.

3.1 The Uterine Corpus

The body of the uterus becomes gradually smaller from the fundus toward the isthmus. The anterior wall is covered by the visceral peritoneum, which is continuous with the vesical peritoneum anteriorly, forming the vesicouterine space.

The posterior wall is convex and covered by the visceral peritoneum which continues inferiorly to cover the cervix and upper vagina. The tubes and round ligaments, which fix the uterus to the wall of the pelvis, emerge bilaterally from the upper and lateral ends of the uterine body. The utero-ovarian ligaments emerge posteriorly. These three structures are covered by a layer of peritoneum, which passes from the lateral margin of the uterine wall to the wall of the pelvis and is called the broad ligament (**Fig. 6**).

3.2 The Cervix

The cervix is the distal extremity of the uterus. It is conical in shape and faces toward the fundus and the inside of the vagina. It is divided into a superior, supravaginal part and an inferior vaginal part. Since the vaginal fornices are wrapped closely around the cervix, it is the least mobile part of the uterus.

The supravaginal part is separated anteriorly from the bladder by fibrous tissue, called the parametrium, which is continued laterally in the broad ligaments (**Fig. 7**). The uterine artery, which enters the uterus at this level, in fact crosses the parametrium. Posteriorly, the supravaginal part is covered by peritoneum, which subsequently covers the posterior wall of the vagina and is reflected over the rectum, forming the rectouterine space.

At its distal end, there is a small circular opening, called the external cervical os, which opens into the vagina.

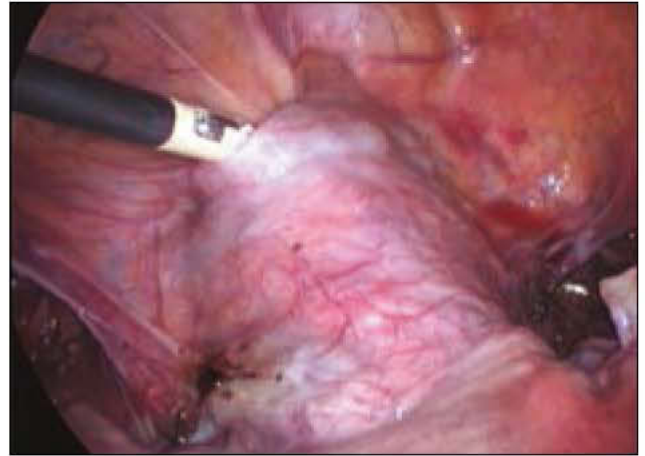


Fig. 7
Bladder and uterine cervix.

3.3 The Uterine Cavity

The uterine cavity is relatively small compared to the size of the organ. The cavity is virtual and triangular in shape, with the base formed by the fundus between the two orifices of the uterine tubes and the apex at the internal os where the uterine cavity communicates with the cervical canal. The

cervical canal is narrow at the end and wider in the middle and links the uterine cavity with the vagina. The length of the uterine cavity from the fundus to the external os, measured by hysteroscopy, is about 6 cm.

3.4 The Uterine Ligaments

The pericervical ring or “retinaculum uteri” consists of three pairs of ligaments at the level of the isthmus, which support the uterus. The two anterior ligaments are called the vesico-uterine ligaments and the posterior ones are the uterosacral ligaments. Laterally, there are two fibrous bands called the cardinal or Mackenrodt’s ligaments. These originate at the cervix and lateral vaginal fornices and are continuous with the parametrium, which surrounds the cervical and uterine vessels (**Fig. 8**).

The uterosacral ligaments consist of two leaves of visceral peritoneum, which arise from the posterior part of the isthmus, cervix and posterior fornix and pass lateral to the rectum to reach the cervix. They form the boundaries of a posterior space known as pouch of Douglas. This is bounded anteriorly by the posterior wall of the uterus, cervix and vagina, posteriorly by the rectum and laterally by the uterosacral ligaments.

The two round ligaments and the broad ligaments arise from the lateral wall of the uterus bilaterally and are inserted into the lateral pelvic wall. Together with the uterus, they form a

septum in the female pelvis, dividing it into two parts. The anterior part contains the bladder and the posterior part contains the rectosigmoid and some of the small intestine.

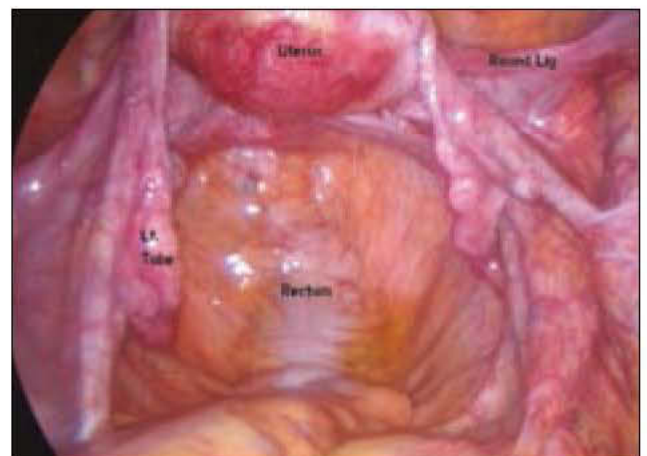


Fig. 8
Uterus, tubes, rectum and round ligaments.

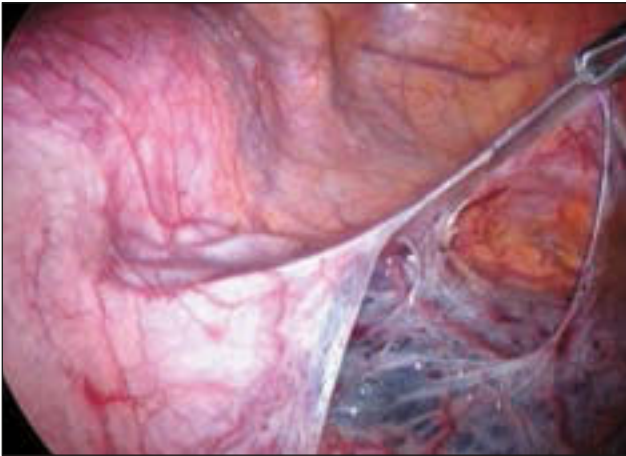


Fig. 9
Right anterior broad ligament.

The tubes, the round ligaments, the utero-ovarian ligaments, vessels and nerves are located between the anterior and posterior leaves of peritoneum of the broad ligament (**Fig. 9**). The portion of the broad ligament below the tube is called the mesosalpinx. The insertion of the broad ligament on the lateral wall of the pelvis has a concave border, known as the pelvic infundibulum, traversed by the ovarian vessels and nerves.

The round ligaments arise from the lateral part of the uterus and pass through the broad ligaments below and anterior to the tubes above the iliac vessels, then course through the internal inguinal ring to traverse the inguinal canal and terminate in the labia majora. They are about 10–12 cm in length and are formed by muscle fibers mixed with fibrous tissue arising from the uterus. Vessels and nerves run in the round ligaments.

4.0 Vessels and Nerves

4.1 The Uterine Artery

The **uterine artery arises from the anterior trunk of the internal iliac** (or hypogastric) artery. It crosses the medial part of the levator ani muscle and enters the uterus at the level of the cervix. It provides the blood supply to all of the uterus. It has a wavy course. In the cervix, it is located 2 cm above and anterior to the ureter to which it supplies a small branch (**Fig. 10**).

From its cervical insertion, it ascends tortuously along the lateral wall of the uterus between the two layers of the broad ligament as far as the tubes. It then extends as far as the ovarian hilum where it terminates in an anastomosis with the ovarian artery. It gives descending branches to the cervix and vagina, which anastomose with branches of the vaginal artery.

Anatomical variations of the uterine artery are uncommon.

Just 1% of patients have two uterine arteries on one side while the presence of two uterine veins for each artery is a constant finding. *Pelage et al.* in 1999 demonstrated that the blood supply to the uterus could originate from the ovarian artery or from the artery of the round ligament. On the other hand, it is more common for the blood supply to the ovary to originate from the uterine artery in about 2–4% of woman. The uterine artery usually arises from the hypogastric artery, but it may also arise from the vaginal artery or middle rectal artery.

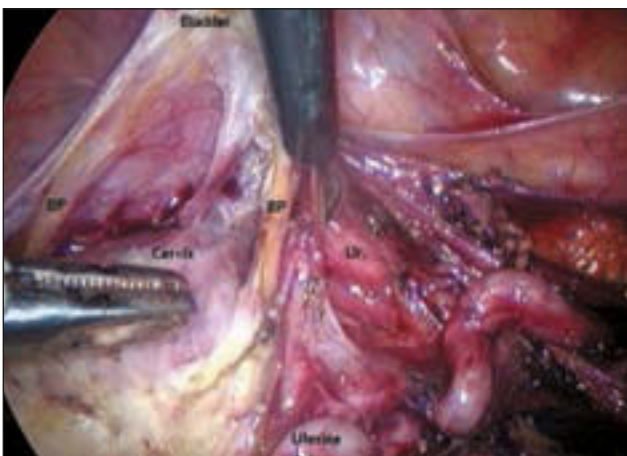


Fig. 10
Uterine artery.

4.2 Relationship Between the Uterine Artery and the Ureter

Ureter injuries during pelvic surgery are reported especially during dissection or hemostasis of the uterine artery. The caudal part of the ureter passes medial to the obturator forosa and is traversed by the uterine artery.

At this point, the ureter is located between the uterine artery (anterior to the ureter) and the vaginal artery (posterior to the ureter) (Fig. 11). The origin of the uterine artery is caudal and lateral, whereas the ureter comes from the cranio-lateral direction (Fig. 12). The uterine artery crosses the ureter anteriorly, close to the lateral vaginal fornix, about 1.5 – 2 cm lateral to the cervix. After crossing, the two structures continue in the same direction. Their course is often almost parallel so differential diagnosis is extremely difficult. For safety reasons it is necessary to perform wide anatomical dissection so as to isolate the structures completely before dividing them (Fig. 13). Another option is to use transillumination after cannulation of the ureters via cystoscopy.

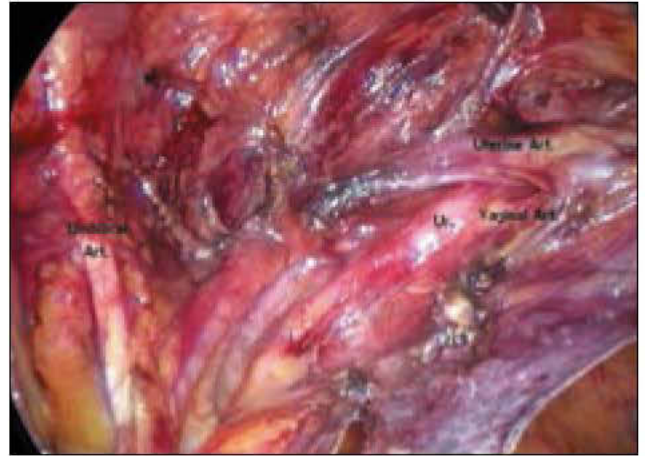

Fig. 11
Uterine artery (anterior) and vaginal artery (posterior) traversing the ureter.

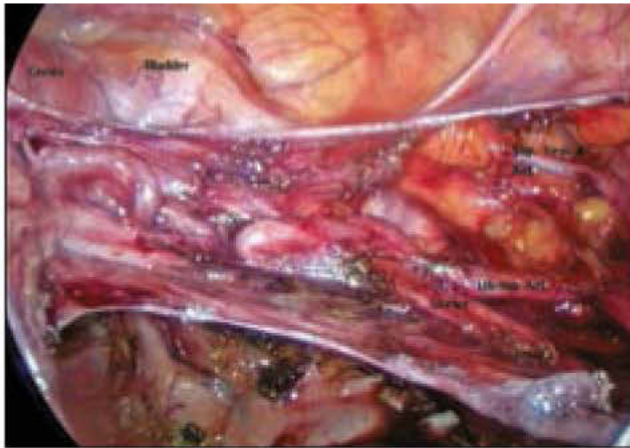


Fig. 12
Anatomical topographical relation between the uterine artery and the ureter.

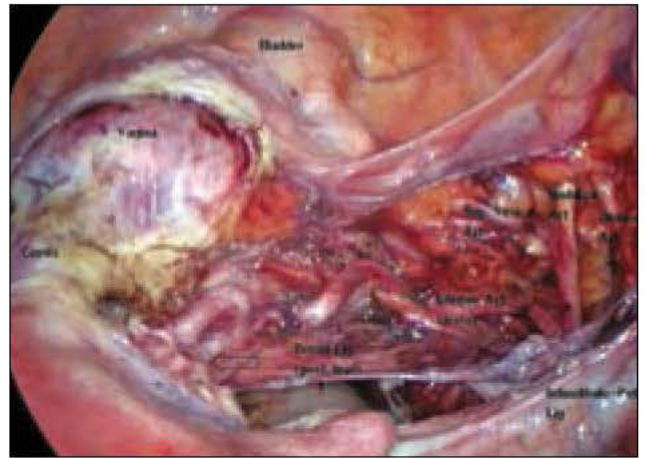


Fig. 13
Wide anatomical dissection to localize the structures correctly.

5.0 The Ureter

The ureter enters the pelvis from the pelvic rim, where it crosses the external iliac artery distal to its origin (bifurcation of the common iliac artery into internal and external), proximal to the pelvic infundibulum (Fig. 14).

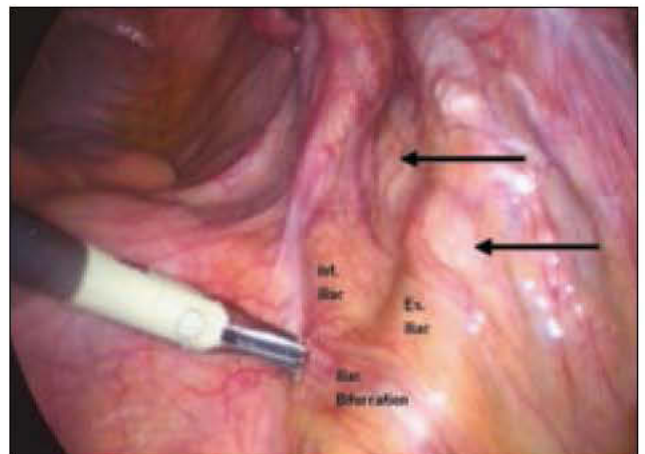


Fig. 14
The ureter and the bifurcation of the common iliac artery.

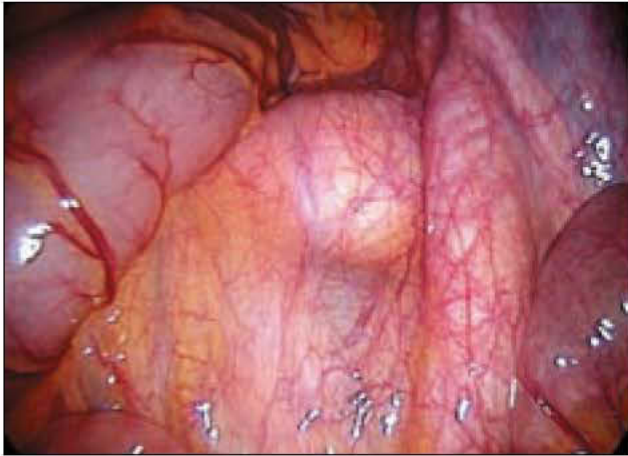


Fig. 15
The course of the ureter.

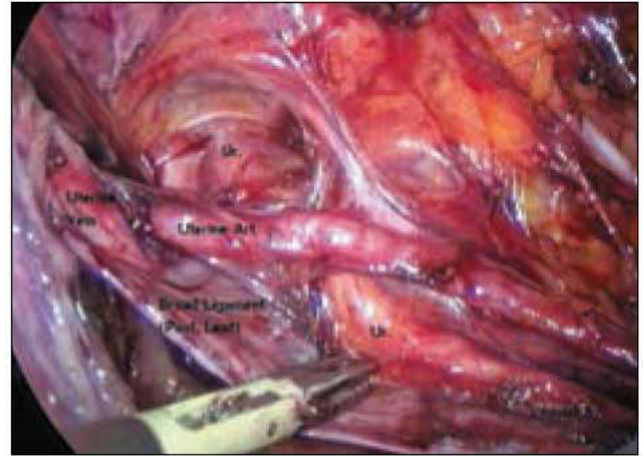

Fig. 16
Anatomical-topographical relationship between the uterine artery and the ureter.

The ureter is visible through the transparent peritoneum and also because of its peristaltic movements, which can be stimulated by touching it gently with forceps. Its caudal course is parallel and lateral to the internal iliac artery, close to the uterosacral ligament (**Fig. 15**).

From this point, it descends parallel and medial to the obturator artery, which it follows in the obturator fossa. In the caudal part of the obturator fossa, the ureter turns medially and is crossed by the uterine artery (**Fig. 16**).

5.1 Surgical Exposure of the Ureter

The anatomical relations between the ureters and pelvic vessels are extremely important for pelvic surgery. Knowledge of them is essential when performing oncological surgery such as radical Wertheim hysterectomy. Wide ureter dissection is recommended in this type of surgery.

Injury to the ureter is one of the most feared and most frequent complications in gynaecological surgery. The anatomical

At this point, the ureter is between the uterine artery (anterior to the ureter) and the vaginal artery (posterior to the ureter) and is then crossed by the vesical vessels.

The ureter enters the superior part of the cardinal ligament, passes below the pillars of the bladder to enter the base of the bladder at the level of the bladder trigone.

predilection sites of ureter injuries are the pelvic rim because of the proximity of the pelvic infundibulum, lateral to the uterus where it is crossed by the uterine artery, close to the bladder pillars or close to the uterosacral ligaments.

The surgical technique for exposure of the ureter has various steps:

- Fenestration of the broad ligament with the aim of moving the ureter laterally. This is an important step in any adnexectomy and is essential in hysterectomy (**Fig. 17**).
- Localization and identification of the ureter and uterine artery. The position of uterine artery ligature must be determined with awareness and knowledge of the location of the ureter.
- Complete dissection of the uterine artery and ureter especially in the case of radical surgery.
- In the event of intraligamentary myomas, which can alter the position and course of the ureter, this must be dissected widely.
- Dissection of the ureter at the level of the cardinal ligaments must not transgress the lateral part of the bladder pillars.

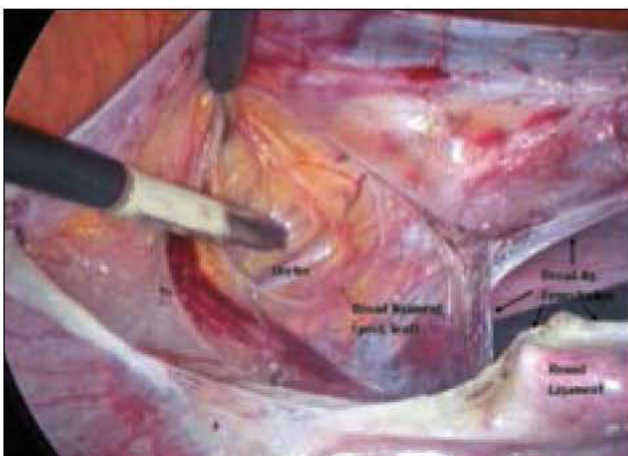


Fig. 17
Fenestration of the broad ligament.

To prevent injury to the ureter during hysterectomy, the following is advisable:

- Use of a uterine manipulator sturdy enough to elevate and lateralize the uterus with the aim of exposing the angle where it meets the uterine artery. Incorrect exposure of the uterine artery can easily lead to injuries to the ureter when the artery is divided, ligated or coagulated by use of bipolar electrocautery.
- Fenestration of the broad ligament, which allows the ureter to be moved, which is located very close to the posterior leaf of the peritoneum.
- Adequate dissection of the posterior leaf of the broad ligament is essential to better visualize and localize the uterine artery and vein.
- The uterine artery is coagulated at the level of the isthmus and at the point where it passes between the cervix and the body of the uterus.
- Knowledge of the principles of electrocautery is essential for preventing the potential risk of ureter injuries. In particular, the use of bipolar electrocautery with suitable instruments is recommended.
- The anatomical proximity of the ureter to the pelvic infundibulum requires great care during adnexectomy when ligating or coagulating this ligament, especially in the case of adhesions or pelvic endometriosis.
- Where possible, always visualize the ureter by transillumination, as described above.

6.0 The Pelvic Vessels

For the pelvic surgeon, knowledge about the anatomy of the pelvic vessels is crucial regarding the proportions of pelvic organs and the caliber of these vessels. Surgical complications involving these vessels inevitably produce major hemorrhage.

6.1 Aorta, Inferior Vena cava and Bifurcation

The aorta descends in the retroperitoneal space to the left of the midline. At the level of the fourth lumbar vertebra, it divides into three branches: two large lateral ones, the common iliac arteries, and medially a smaller terminal branch, the middle sacral artery.

The ovarian artery arises directly from the anterolateral part of the aorta at the level of the vertebral bodies of L2 and L3, caudal to the origin of the renal arteries. The ovarian artery has an oblique and lateral retroperitoneal course. On the left it traverses the psoas muscle and on the right the inferior vena cava. The ovarian artery crosses the external iliac vessels 2 cm inferior to the ureter. The smaller branches supply the ureter and uterine tubes and finally anastomose with the uterine artery at the level of the uterine body.

The ovarian vessels, lymphatics and related nerve endings are located in the pelvic infundibulum (**Fig. 18**).

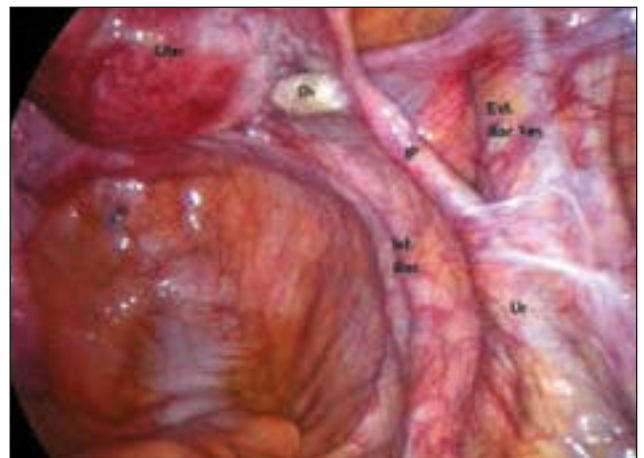


Fig. 18
Right ovarian artery and right pelvic infundibulum.

Another important artery that originates directly from the aorta is the inferior mesenteric artery, which supplies the left half of the transverse colon, all the descending colon, the sigmoid and part of the rectum. The mesenteric artery originates from the aorta 3–4 cm superior to the bifurcation of the common iliac arteries. It then crosses the left common iliac artery and continues in the pelvis as superior hemorrhoidal artery, which descends between the layers of the sigmoid and terminates in the superior part of the rectum.

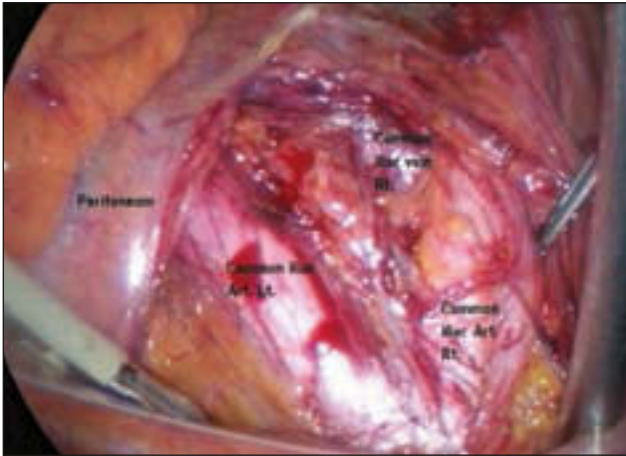


Fig. 19
Common iliac arteries and inferior vena cava.

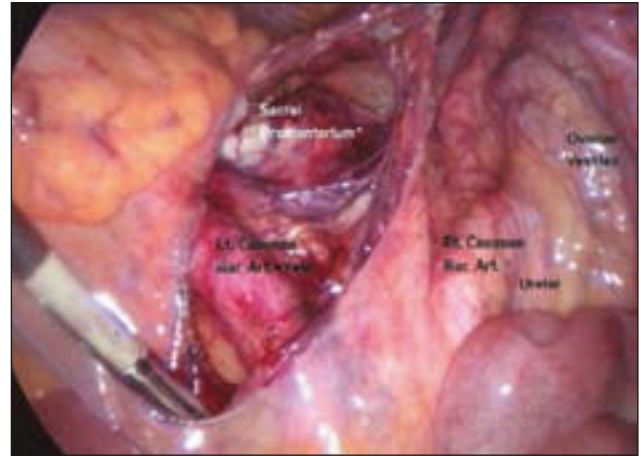


Fig. 20
Principal vessels at the level of the sacral promontory.

6.2 The Inferior Vena cava

The inferior vena cava is a large venous trunk, which drains the subdiaphragmatic part of the human body as far as the right atrium. The abdominal portion of the inferior vena cava has a caliber of 22 mm and is 20 cm long (**Fig. 19**).

The inferior vena cava is located to the right of the lumbar spine. It is formed by the union of the right and left common iliac veins at the level of the fifth lumbar vertebra. The left of the two branches of the common iliac vein is of major importance to the pelvic surgeon because this crosses the midline very close to the sacral promontory (**Fig. 20**). Injury to this vein can occur when the primary trocar is introduced through the umbilicus or during surgical maneuvers at the level of the sacral promontory.

Perforation or injury of the large vessels during introduction of the Veress needle or primary trocar is of low incidence, but nonetheless one of the most feared and dangerous complications of laparoscopic surgery. The major risk factors contributing to the occurrence of this complication are low intra-abdominal pressure, insufficient pneumoperitoneum, rapid or uncontrolled entry, incorrect position of the operating table or a patient with a very large abdominal girth. It must be recalled how important close attention is during this phase as a good third of complications of laparoscopic surgery occur during introduction of the Veress needle or primary trocar.

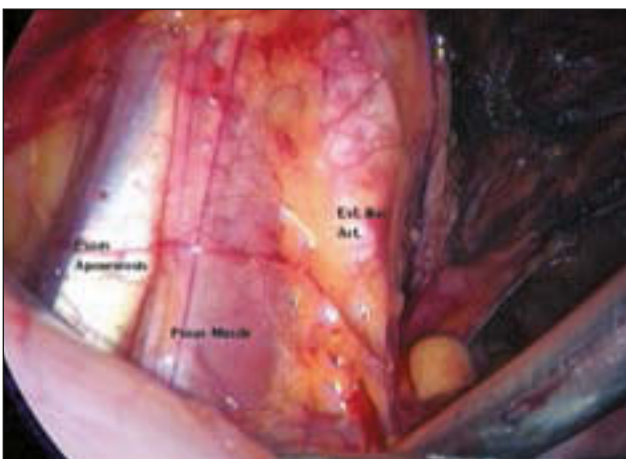


Fig. 21
The iliac vessels and psoas muscle.

6.3 The Iliac Arteries

The abdominal aorta divides into two branches, the common iliac arteries, to the left of the body of the fourth lumbar vertebra. They are about 5 cm long and divide in turn into the external and internal iliac arteries bilaterally.

The right common iliac artery is retroperitoneal with the small intestine, sympathetic nerves and the ureter anterior to it. Posteriorly are the bodies of the fourth and fifth lumbar vertebrae, the terminal part of the two common iliac veins and the start of the inferior vena cava. Laterally, the right common iliac vein and the psoas major muscle can be identified. The left common iliac vein passes medially.

The left common iliac artery is retroperitoneal with the small intestine, sympathetic nerves and superior hemorrhoidal artery in front of it, and at this point it is crossed by the ureter. The bodies of the fourth and fifth lumbar vertebrae are posterior. The left common iliac vein runs medial to the psoas major muscle (**Fig. 21**).

The branches of the common iliac arteries provide the blood supply to the ureter, psoas muscle, lymph nodes and peritoneum.

6.4 The Median Sacral Artery

This artery arises from the posterior part of the aorta, a little above its bifurcation. It courses in the midline anterior to the lumbar vertebræ, sacrum and coccyx. It supplies small branches to the rectum. In front of the sacrum it anastomoses with the lateral sacral arteries. It is crossed by the left common iliac vein.

The median sacral artery and the left common iliac vein may be accidentally injured by surgical maneuvers at the level of the sacral promontory. In the case of promonto-sacral surgery, it is advisable to make a true and proper fenestration of the retroperitoneum. A small retroperitoneal incision is made and after a short time, distension with CO₂ allows these vessels to be visualized better and identified (**Fig. 22**).

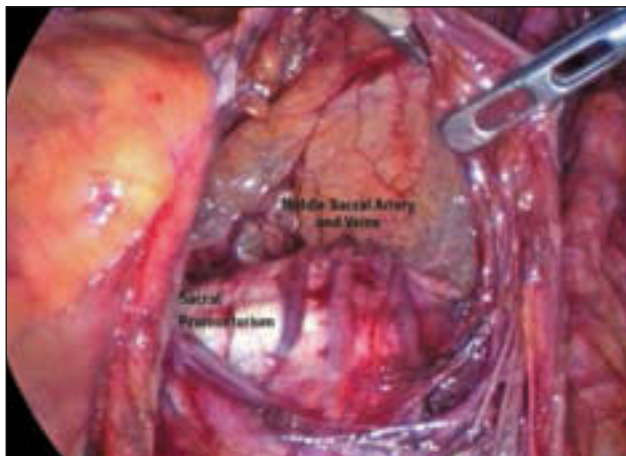


Fig. 22
The sacral vessels at the level of the promontory.

6.5 The External Iliac Artery

The common iliac artery divides into internal and external. The external iliac artery is bigger and passes obliquely and lateral to the border of the psoas muscle (**Fig. 23**). It then enters the inguinal canal where it tapers and is called the femoral artery. At its origin it is crossed by the ovarian vessels and, in some cases, by the ureter. The round ligament crosses it at the end of its course before it enters the inguinal canal. The external iliac vein runs below the artery together with numerous vessels and lymph nodes that are located along its course.

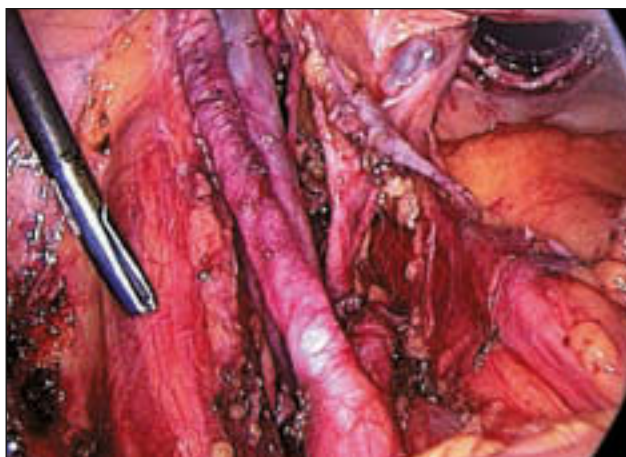


Fig. 23
Left external iliac artery.

6.6 The Branches of the External Iliac Artery

Apart from the small branches to the psoas muscle, it divides into two large branches, the inferior epigastric artery and the deep circumflex iliac artery.

The inferior epigastric artery arises from the medial part of the external iliac artery, 1 cm above the inguinal ligament. It forms a curve anterior to the subperitoneal tissue of the medial border of the internal inguinal ring, crosses the transversalis fascia and runs upward towards the rectus abdominis muscles and posterior fascia, finally dividing into numerous branches. Below the umbilicus, it anastomoses with the superior epigastric artery, a branch of the internal mammary artery, and with the inferior intercostal arteries (**Fig. 24**). This artery produces a prominence in the parietal peritoneum, known as the lateral umbilical fold. It supplies the rectus abdominis muscle and the anterior abdominal wall and gives a branch to the round ligament.

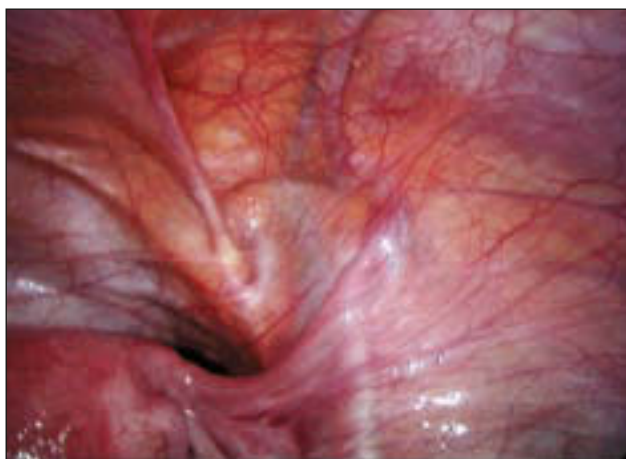

Fig. 24
Inferior epigastric artery.

The deep circumflex iliac artery originates from the lateral part of the external iliac artery opposite the origin of the inferior epigastric artery. It ascends obliquely and lateral to the inguinal ligament toward the anterior superior iliac spine, where it anastomoses with the ascending branch of the lateral circumflex femoral artery.

Particular attention must be paid to the branches of the external iliac artery when the lateral accessory trocars are inserted. The introduction of the lateral trocars should be done under direct vision of the two vessels, which run about

2 cm medial to the anterior superior iliac spine on both sides and lateral to the outer border of the rectus abdominis, running perpendicular to the anterior abdominal wall. The same attention is necessary when it is decided to insert lateral needles through the abdominal wall to fix the ovaries or intestine to the abdominal wall.

The external iliac artery is regarded as essential for the identification, dissection and removal of external iliac lymph nodes in oncological surgery.

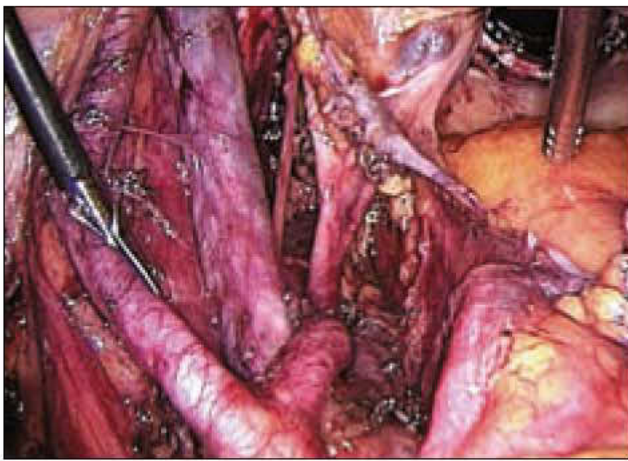


Fig. 25
Left internal iliac artery.

6.7 The Internal Iliac Artery or Hypogastric Artery

The internal iliac artery is highly important as it is responsible for the blood supply of the pelvic viscera. It is a large calibre vessel, shorter than the external iliac artery by about 4 cm (**Fig. 25**). It arises from the bifurcation of the common iliac artery below the upper border of the greater sciatic foramen and divides into two branches, anterior and posterior. It descends vertically in the posterior wall, accompanied by lymphatic vessels. Its division into branches between the upper border of the sacrum and the upper border of the greater sciatic foramen can vary anatomically. It is related anteriorly to the ureter, which crosses it from the left side beneath the internal iliac vein. At its origin, the external iliac vein runs laterally with the obturator nerve below.

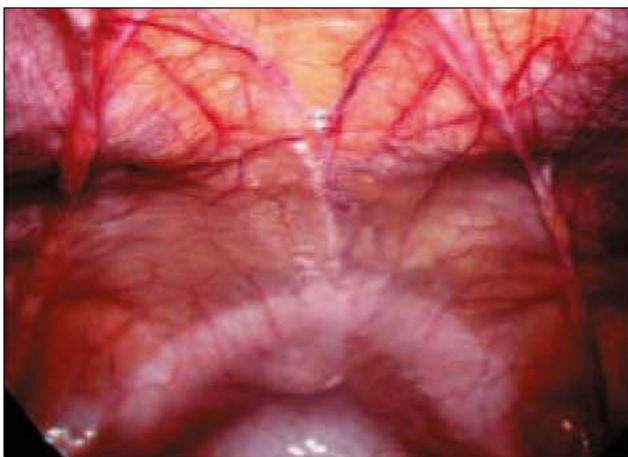


Fig. 26
The umbilical arteries.

6.8 The Branches of the Internal Iliac or Hypogastric Artery

These can be divided schematically into anterior and posterior:

Anterior:

- umbilical
- superior vesical
- middle vesical
- inferior vesical
- middle hemorrhoidal
- obturator
- internal pudendal
- inferior gluteal
- uterine
- vaginal

Posterior:

- iliolumbar
- lateral sacral
- superior gluteal

The umbilical artery is the first upper branch and is an important anatomical boundary for many surgical operations. The artery ascends lateral to the bladder and runs in the anterior abdominal wall toward the umbilicus (**Fig. 26**). The two umbilical arteries form the umbilical cord in the fetus and after birth these arteries are transformed into a fibrous cord, the medial umbilical ligament, which is easily identified at laparoscopy.

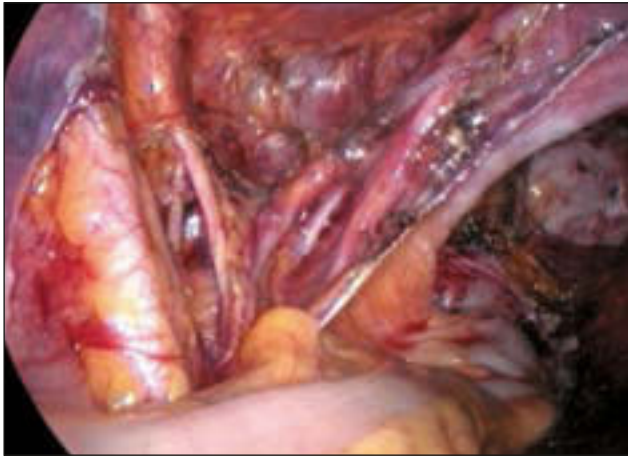

Fig. 27
Obturator fossa.

The obturator artery is an important anatomical boundary during lymphadenectomy along the external iliac artery. It is accompanied by the obturator nerve and vein. It is located deeply and laterally in the pelvis toward the upper part of the obturator foramen on both sides. Inside the obturator foramen, the nerve runs more laterally compared to the artery (**Fig. 27**). The artery passes through the obturator foramen and divides into an anterior and posterior branch. The obturator artery is related laterally to the obturator fascia and medially to the ureter. Anatomic variants of this vessel are common and to identify it the umbilical artery and external iliac artery are used as reference points as the obturator artery is located between these two vessels.

The middle rectal (or hemorrhoidal) artery descends lateral to the rectum in the pararectal space. It supplies the rectum and anastomoses with the superior and inferior rectal arteries.

The internal pudendal artery is the smallest of the terminal branches of the internal iliac and supplies the external genitalia and perineum. It passes downward and external to the inferior part of the greater sciatic foramen, behind the sciatic spines, and leaves the pelvis through the coccygeus and piriformis muscles. It then crosses the sciatic spine and inferior pubic ramus to terminate in the middle of the fascia of the urogenital diaphragm and the area of the clitoris. In its course it is accompanied medially by the pudendal nerve, the inferior rectal nerve and the inferior gluteal vessels and laterally by the sciatic nerve, the inferior gluteal nerve and the internal obturator nerve.

The inferior gluteal artery is the most important of the terminal branches of the internal iliac (hypogastric) artery. It descends anterior to the nerves of the sacral plexus and piriformis muscle, posterior to the internal pudendal artery and passes

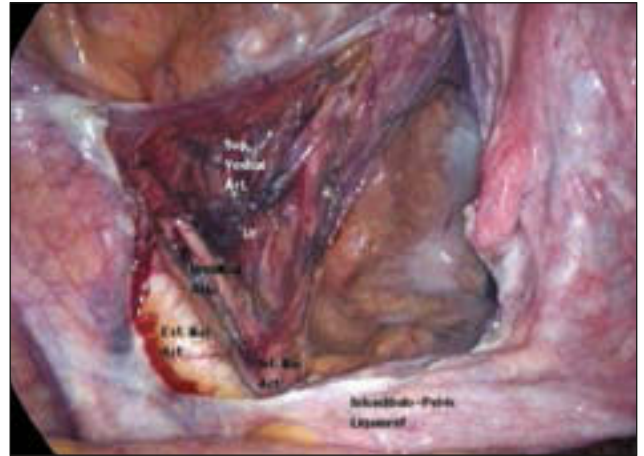


Fig. 28
Superior vesical artery.

toward the lower part of the greater sciatic foramen. It supplies the piriformis muscle, the coccygeus and levator ani with the rectal vessels.

The vaginal artery arises from the internal iliac artery in a common trunk with the uterine artery and middle rectal artery. The ureter crosses it posteriorly and from this point the artery descends in the direction of the vagina medial to the ureter. It ends in the middle third of the vagina in small anastomosing branches and supplies all of the vagina.

The superior vesical artery arises from the proximal part of the anterior trunk of the internal iliac artery and supplies numerous branches to the upper part of the bladder and ureter.

The middle vesical artery is a branch of the superior vesical artery and supplies the base of the bladder (**Fig. 28**).

The inferior vesical artery normally arises in common with the middle hemorrhoidal artery or the vaginal artery. It supplies the base and inferior part of the bladder and the trigone.

The posterior branches of the internal iliac or hypogastric artery:

The iliolumbar artery is a branch of the posterior trunk and passes behind the obturator nerve and external iliac vessels toward the medial border of the psoas major muscle, where it divides into a lumbar branch and an iliac branch.

The lateral sacral arteries are branches of the posterior trunk, normally two in number, one superior and one inferior, which descend to the lateral border of the sacrum.

The superior gluteal artery goes to the gluteal area, running behind the lumbosacral trunk at the level of the first sacral nerve and leaving the pelvis through the piriformis, dividing into a superficial and deep branch.

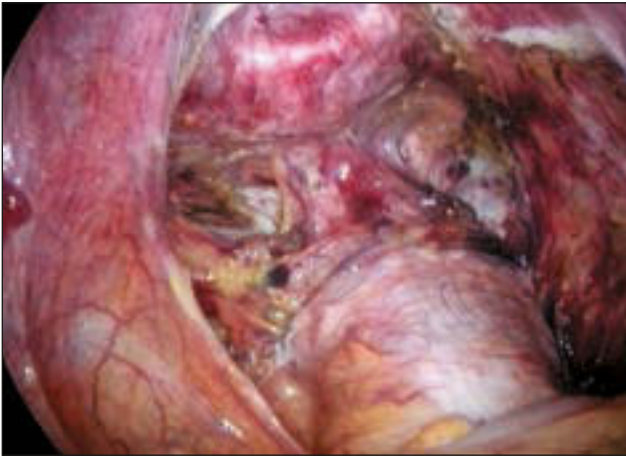

Fig. 29 Pararectal space.

7.0 The Pelvic Spaces

7.1 The Pararectal Space

The pararectal spaces are lateral to the rectum bilaterally. They are located posterior to the base of the broad ligament, which forms the anterior boundary of these spaces. The lateral boundary is formed by the ureter and internal iliac artery. The base consists of the puborectalis muscle (part of the levator ani). This space contains the uterosacral ligament laterally, which passes posteriorly in the direction of the sacrum (**Fig. 29**).

Laparoscopic operations for uterine prolapse or endometriosis of the rectovaginal septum are procedures require a solid knowledge of the anatomy of these spaces. Correct dissection of the pararectal space is of crucial importance to prevent iatrogenic injury to the vesical and rectal nerve plexuses, which cross this space.

This space contains, from medial to lateral, the obliterated umbilical artery, the obturator artery and vein and the obturator nerve, together with lymph nodes and lymphatic vessels (**Figs. 30–31**). The paravesical space is particularly important in pelvic lymphadenectomy.

7.2 The Paravesical Space

The paravesical space is located anteriorly at the base of the broad ligaments bilaterally. The medial boundary is the bladder, the lateral boundary is the internal obturator fascia while its inferior boundary consists of the fibres of the iliococcygeus muscle, which terminate in the tendinous arch of the levator ani.

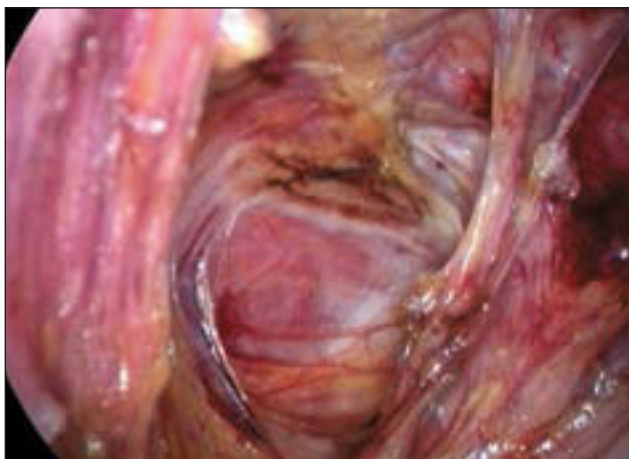

Fig. 30
Paravesical space.

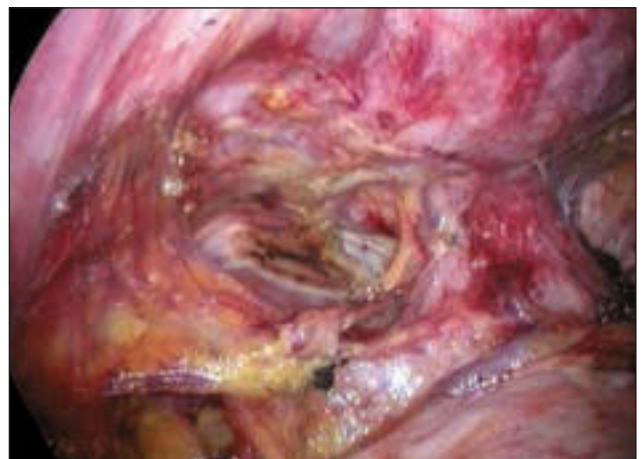
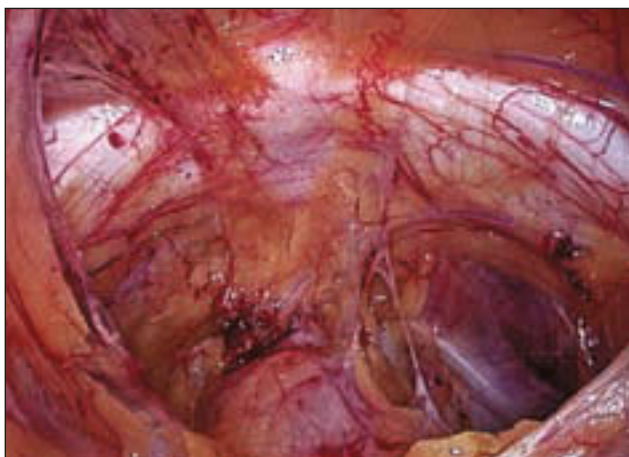
Fig. 31
Lateral view of the paravesical space: the internal obturator muscle, puborectalis muscle and the two tendinous arches can be seen.



7.3 Space of Retzius

The space of Retzius or retropubic space is located between the posterior part of the pubic bone and Cooper's ligament, which is its anterior boundary. The anterior part of the bladder is the posterior boundary of this space. The lateral boundary is formed by the internal obturator muscle and it is continuous posteriorly with the vesicovaginal space. The floor of the space of Retzius is the pubocervical (paravaginal) fascia, which is inserted into the tendinous arch (connective tissue located medial to the insertion of the iliococcygeus muscle) in the internal obturator fascia (**Fig. 32**).

Fig. 32
Space of Retzius.

7.4 The Vesicovaginal Space

This space is found between the anterior part of the vagina and the posterior part of the bladder. It contains the bladder trigone and the vesicovaginal fascia. It is bounded laterally by the vesicouterine ligaments or vesical pillars (**Fig. 33**). The inferior vesical arteries and veins and ureters pass beneath the pillars toward the bladder neck.

This space is also virtual and it is dissected during hysterectomy to free the bladder; the surgeon must avoid lateral dissection because of the risk of ureter injury.

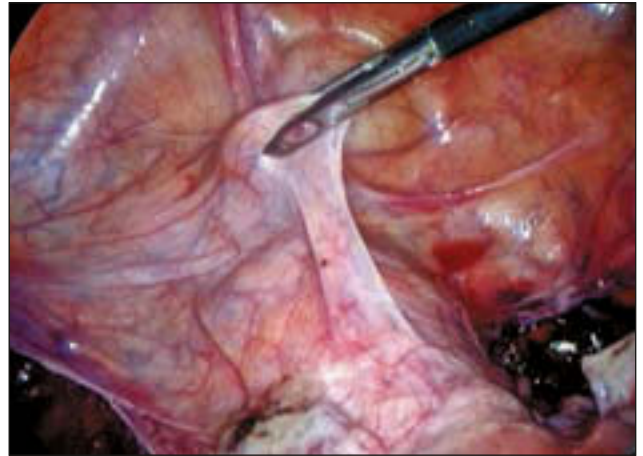


Fig. 33
Vesicovaginal space.

7.5 The Rectovaginal Space

The recto-vaginal space is another virtual space located between the posterior part of the vagina and the anterior part of the rectum. It begins at the medial junction of the utero-sacral ligaments and the pouch of Douglas. It is bounded laterally by the iliococcygeus muscles of the levator ani.

7.6 The Presacral Space

This is located posterior to the parietal peritoneum in front of the vertebral column at sacral level. It is bounded posteriorly by the anterior longitudinal ligament, the sacral promontory and the sacrum (**Fig. 34**). The right lateral boundary is the right common iliac artery and the right ureter. On the left are found the left common iliac artery, left ureter and the inferior mesenteric artery and vein. It contains fat and the presacral nerves, which receive multiple afferent and efferent connections from the sympathetic, parasympathetic and somatic system of the sacral nerves. Dissection of this space is necessary when presacral neurectomy is performed.

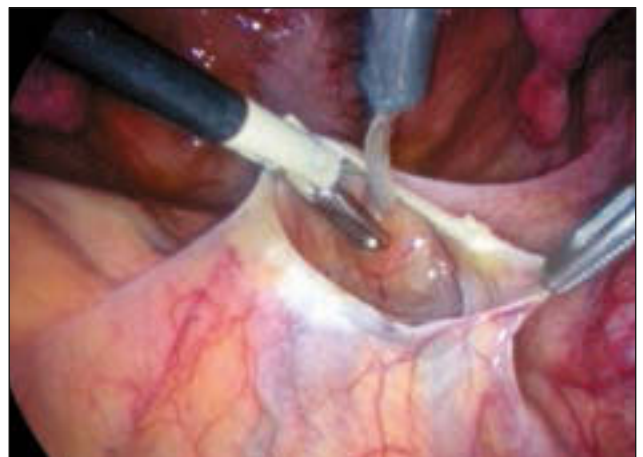

Fig. 34
Presacral space.

Recommended Reading

1. DUBREUIL-CHAMBARDEL, L: (1925) *Traité des Variations du System Artériel Variations des Artères du Pelvis et du Membre Inferieur*, Masson et Cie., Paris
2. GASPARRI F, MASSI GB: (1976) *Trattato italiano di ginecologia*
3. PELAGE JP, LE DREF O, JACOB D, SOYER P, ROSSIGNOL M, TRUC J, PAYEN D, RYMER R: Uterine artery embolization: anatomical and technical considerations, indications, results, and complications *J Radiol.* 200 Dec;81 (12 Suppl): 1863–72.
4. PELAGE JP, LE DREF O, SOYER P, JACOB D, KARDACHE M, DAHAN H, LASSAU JP, RYMER R: Arterial anatomy of the female genital tract: variations and relevance to transcatheter embolization of the uterus. *AJR Am J Roentgenol.* 1999 Apr;172(4): 989–94.

Chapter V

Suturing Techniques in Gynecologic Laparoscopy

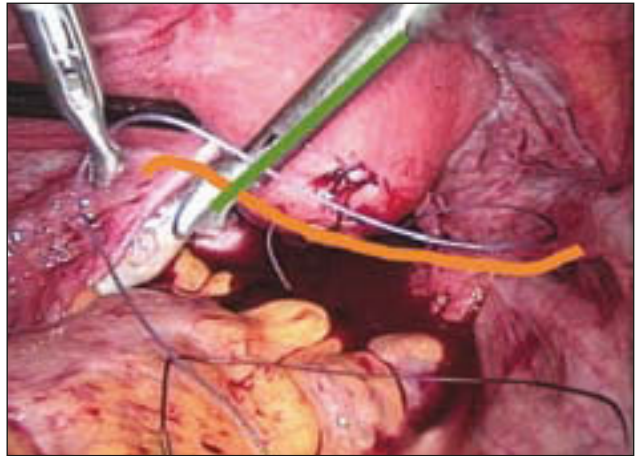
**Daiana Tonello¹, Paulo Ayroza²,
Arnaud Wattiez³ and Luca Mencaglia⁴**

¹Barra D'Or Hospital, Rio de Janeiro, Brazil

²Department of Gynecology and Obstetrics,
Medical School of the Santa Casa University of São Paulo, Brazil

³Strasbourg University Hospital, Strasbourg, France

⁴Centro Oncologico Fiorentino, Florence, Italy



1.0 Ergonomics

To make suturing easier it is important for the surgeon to adopt as ergonomic a position as possible.

The surgeon must be at a height where the angle between his upper arm and forearm is > 90 degrees. It must be borne in mind that the patient's abdominal wall is distended by the pneumoperitoneum and is further elevated by the Trendelenburg position and also that the surgeon's hands are situated about 20 cm higher because of the presence of the trocars and instruments. If the operating table cannot be lowered sufficiently, the surgeon may use a footrest to assume the correct position.

Suturing techniques in laparoscopy do not require large movements of the trunk and arms but only control of the

instruments by the hands and fingers. The arms must be relaxed and the elbows beside the trunk.

It is extremely important that all of the surgical team is arranged correctly around the table and that the surgeon's line of vision (eye-monitor) always passes between the surgeon's hands.

Moreover, for correct ergonomics during laparoscopic suturing, the trocar ports should be positioned relative to the tissue to be sutured to take into account as far as possible the hand holding the needle holder, the plane of suturing and the angle of incidence between needle and tissue.

2.0 Suturing

Suturing is defined as any surgical step intended to approximate the edges of a tissue that is discontinuous with its anatomical planes. Its function can be mechanical (opposing the forces that tend to separate the wound edges), joining different anatomical planes together or isolation (preventing bacterial contamination).

Essentially there are two traditional suturing techniques:

- interrupted
- continuous

Interrupted (noncontinuous) sutures are placed to approximate the wound edges, placing individual sutures equidistant from each other.

The interrupted suture can be simple, when the purpose is simply to approximate the tissue, double (two simple sutures without breaking the continuity of the thread) when hemostasis is also desired or inverting when it is necessary to invaginate the tissue more deeply.

This type of suture has certain advantages: if a knot comes undone, this is not enough to cause suture dehiscence, it is well tolerated by the tissues because less foreign material is present and, in the event of infection, it prevents this from spreading to the entire wound following the course of the suture. At the same time, however, it must be borne in mind that it takes longer compared to a continuous suture, is less hemostatic and provides relatively lower resistance.

Continuous suture allows approximation of the edges with an uninterrupted series of stitches using one thread. It can be a straight line, and in this case the suture is stopped by a knot at either end, or circular (also called purse-string), where the knot is tied with the two ends of the suture. For this type of suture, it is preferable to use a smooth and flexible thread. The advantage of the continuous suture is that it is fast and provides optimal tensile strength retention but the disadvantage is that if a suture gives way, this is more likely to produce dehiscence of the entire suture and in the event of infection, it favors spread along the suture.

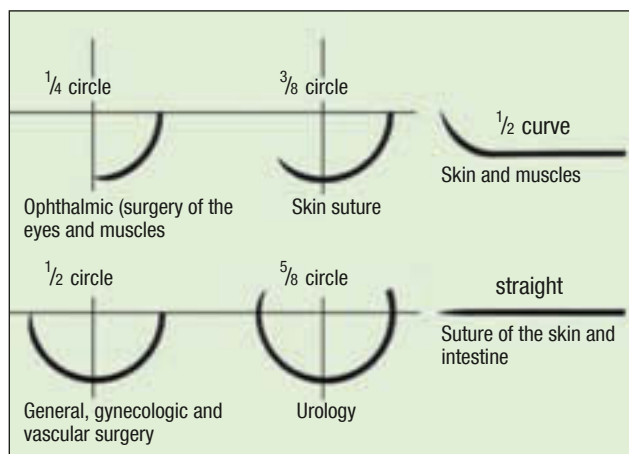


Fig. 1
Types of suture needles.

3.0 Materials

The materials used in the traditional suturing technique are needles and suture threads.

3.1 Surgical Needles

Surgical needles are available in six different geometric forms: straight, $\frac{1}{2}$ curve, $\frac{1}{2}$ circle, $\frac{1}{4}$ circle, $\frac{3}{8}$ circle, $\frac{5}{8}$ circle and they are distinguished by the type of point: rounded, conical, diamond point and by the body: circular, oval, triangular, lancet, hexagonal (**Figs. 1–2**).

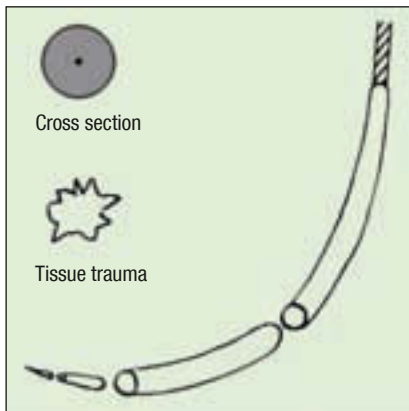


Fig. 2a
Needles with a cylindrical cross section (tissue with little resistance).

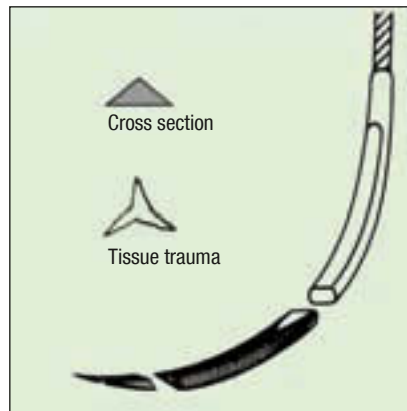


Fig. 2b
And triangular cross section (two cutting edges for highly resistant tissue).

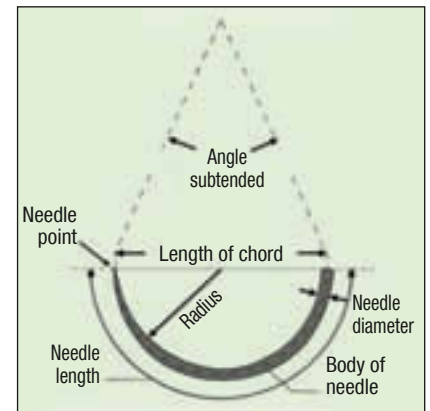


Fig. 3
The maximum length of needles used in laparoscopy is the size of the arc, which can vary from 27 to 36 mm.

In general, semicircular round-bodied surgical needles with a conical tip with a length varying according to the tissue being sutured are used almost exclusively (**Fig. 3**).

In the case of tissues with a firm consistency, some surgeons prefer to use needles with all three edges of the tip cutting but round-bodied (taper cut) which penetrate more easily without causing excessive trauma.

Straight surgical needles can be used transparietally to suspend tissues such as the intestine, ovaries and vaginal vault with the aim of improving exposure of the operative field (**Figs. 4–6**).

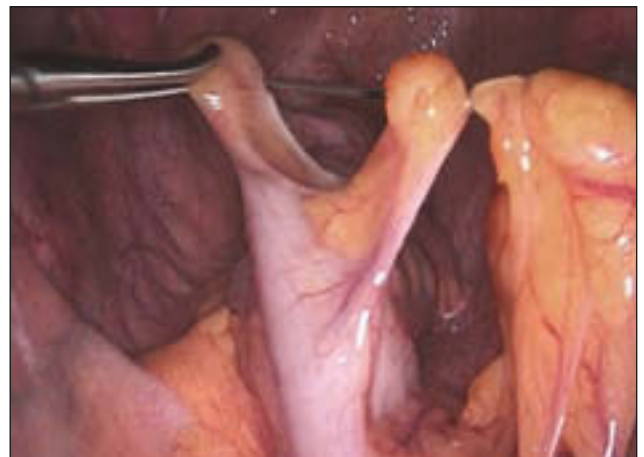

Fig. 4
The intestine is anchored to the abdominal wall by means of a suspensory suture. The peri-intestinal fat is transfixated with a straight needle.

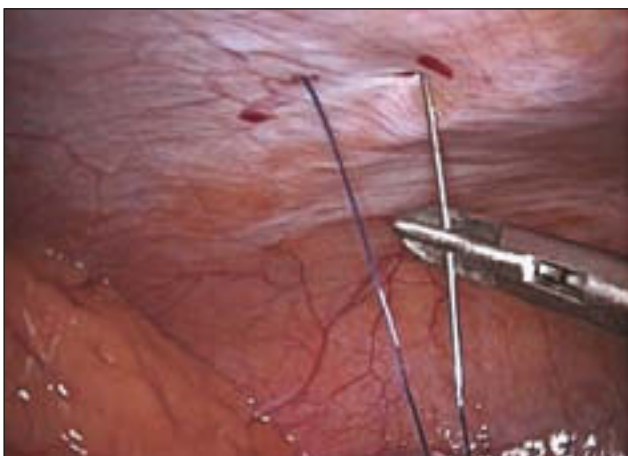


Fig. 5
The intestine is anchored to the abdominal wall by means of a suspensory suture. The abdominal wall is transfixated.

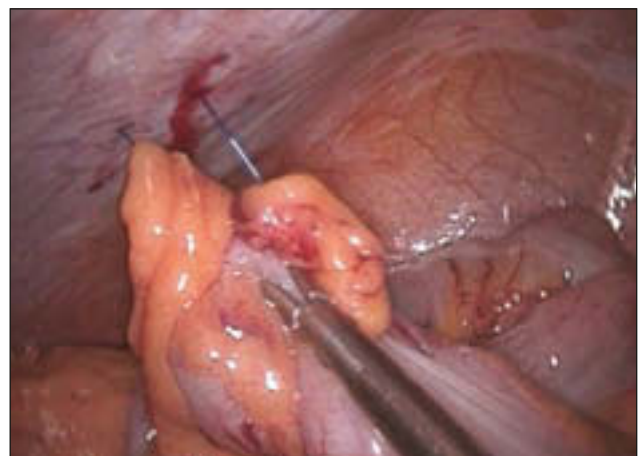

Fig. 6
The intestine is anchored to the abdominal wall for the duration of the operation by means of a suspensory suture.

3.2 Suture Threads

Suture materials are classified in relation to their:

Diameter: there are two classification systems, European and U.S. Pharmacopeia. The latter is the one commonly used (Tab. 1).

Structure: **Monofilament**
Multifilament

- twisted
- braided
- pseudomonofilament (Fig. 7)

Absorption: **Absorbable** (fast, medium, slow)
Non-absorbable

Material: **Natural**
Synthetic

The thickness of the suture is correlated with the choice of needle size and the type of tissue being sutured.

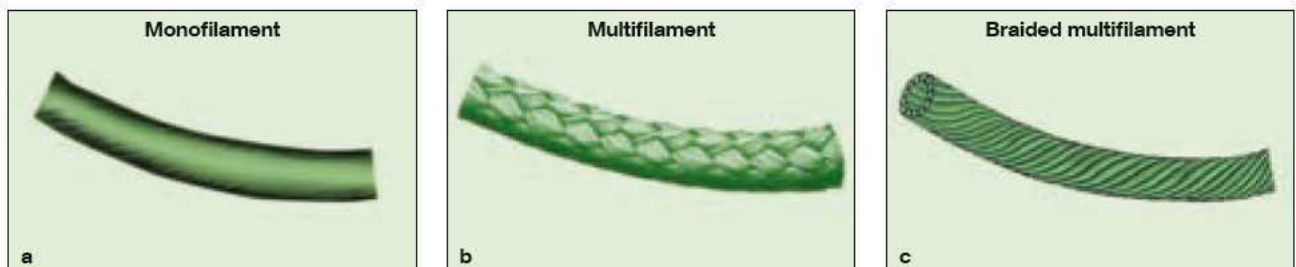
Monofilament characteristically is smooth and so is particularly indicated for continuous suture but at the same time, it is less easy to handle and more fragile if used for intracorporeal suture and knots hold less well compared to a multifilament suture of equal gauge.

The choice of suture in relation to its duration depends exclusively on the indication for the suture; in surgery to reconstruct the pelvic floor, for example, non-absorbable sutures are used to maintain the support function longterm.

In laparoscopy, the length of the suture is particularly important: > 90 cm for extracorporeal sutures and > 15 cm for intracorporeal sutures.

Diameter in mm	European Pharmacopeia (EP)	United States Pharmacopeia (USP)	
		Absorbable and natural sutures	Non-absorbable and synthetic sutures
–	–	–	12/0
0.010–0.019	0.1	–	11/0
0.020–0.029	0.2	–	10/0
0.030–0.039	0.3	–	9/0
0.040–0.049	0.4	–	8/0
0.050–0.069	0.5	–	7/0
0.070–0.099	0.7	7/0	6/0
0.100–0.149	1	6/0	5/0
0.150–0.199	1.5	5/0	4/0
0.200–0.249	2	4/0	3/0
0.250–0.299	2.5	3/0	2/0
0.300–0.399	3	2/0	0
0.400–0.499	4	0	1
0.500–0.599	5	1	2
0.600–0.690	6	2	3 and 4
0.700–0.790	7	3	5
0.800–0.899	8	4	6

Tab. 1
 Classification of suture materials according to the European Pharmacopeia (EP) and the U.S. Pharmacopeia (USP).



Figs. 7a–c
 Different types of suture materials.

The most important physical properties of a suture material are:

- **tensile strength retention:** ability of a thread to oppose traction
- **smoothness:** force necessary to make a suture glide in a tissue. Strictly correlated with the friction coefficient of the suture material
- **elasticity:** capacity of a suture to elongate under traction
- **capillarity:** physical property by which molecules of liquid are induced to move inside a tube independently of gravity
- **hydrophilia:** chemical phenomenon denoting the greater or lesser affinity for water of various materials
- **flexibility:** property by which a suture is capable of supporting acute angulation without breaking or opposing excessive resistance
- **plasticity:** this is the lack of recovery of the initial dimensions of the suture after forced lengthening
- **handling:** this is a property that cannot be measured with instruments but is a special and subjective quality assessed only by the surgeon's hand; it is the resultant of all the physical properties described above.

The sutures most commonly used in laparoscopy are:

Vicryl (Polyglactin 910). Braided absorbable synthetic suture. Also produced in a form coated with calcium stearate to make it water-repellent and more rigid.

Advantages: optimal handling
good knot retention
predictable absorption
very versatile
minimal tissue reaction

Disadvantages: braided and capillary
retention reduced in the presence of urine

Vicryl is the most commonly used suture in gynecologic laparoscopy because of its optimal handling and versatility.

Polyester (Dacron). Commercial names: Ethibond (polyester coated with polybutylate), Mersilene (polyester), Micron (polyester covered with silicone). Non-absorbable synthetic monofilament suture.

Advantages: optimal tensile strength retention
low reactivity
good flexibility
optimal smoothness

Disadvantages: asepsis of the tissue
removal of the sutures if infected

Polyester, because of its smoothness and non-absorbability, finds its greatest use in surgery of the pelvic floor.

Monocryl (polyglactaprone 25). Absorbable synthetic monofilament suture.

Advantages: high tensile strength retention
absorbable

Disadvantages: low knot retention
50% absorbed in 7 days

Particularly indicated for suturing delicate tissues such as the tube and ovary as it produces less tissue reaction.

Polypropylene Commercial names: Prolene, Surgilene. Non-absorbable synthetic monofilament suture.

Advantages: good knot retention
optimal smoothness
low tissue reaction
optimal tissue resistance
versatile applicability

Disadvantages: memory
low flexibility
knot tying difficult with bigger suture diameters

Small-diameter material is used for vascular sutures while larger diameters are used for temporary suspension of the ovaries or sigmoid.

4.0 Instrumentation

To speed up and facilitate as much as possible the suturing process, perfect knowledge of the required laparoscopic instruments is essential.

4.1 Trocars

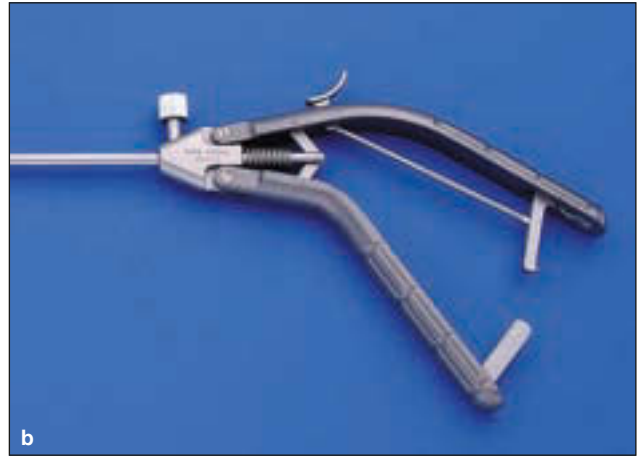The trocar allows various types of laparoscopic devices to be passed into and used in the abdominal cavity.

The 6-mm trocars allow finer and more precise movements so 5-mm instruments are usually employed; however, needles are introduced and removed more easily through 11-mm trocars. It is therefore possible to use a 11-mm trocar with reducer although 11–13 mm trocars are currently available that do not require reduction from 13 to 6 mm because they come with a special valve, though this is extremely fragile and easily damaged when needles are passed through it. When suturing delicate small structures such as the ureter or tube, where it is preferable to use 3-mm instruments, 3.9-mm trocars can be used.

The trocars have different types of valves:

- **multifunctional valve:** this is opened by pressure exerted by an external plunger
- **automatic valve flaps:** this opens automatically when the instrument is pushed against it
- **silicone leaflet valve:** with a membrane, bicuspid or tricuspid shape

When suturing, attention should be paid to the type of trocar valve; the silicone leaflet valve remains open when two sutures are passed inside it, causing gas to leak. When using extracorporeal knots, trocars with a tricuspid valve are therefore preferable.



Figs. 8a, b
Needle holders with straight and curved handles.

4.2 Needle holders

The needle holder is the fundamental instrument for laparoscopic suturing as it must carry the needle, place the stitch and tie the intracorporeal knot (**Fig. 8**).

There are different versions depending on the handle design (curved, straight), opening and closing ratchet mechanism (central position, right, left), stitch (straight, curved, single or double) and jaws but in general, they must all be easy to

handle, lightweight and sturdy at the same time. They must allow the needle to be grasped firmly but also to scale the force while the suture is being manipulated.

There are needle holders capable of straightening the needle but they have the disadvantage of not allowing any variation of the angle of impact on the tissue being sutured.

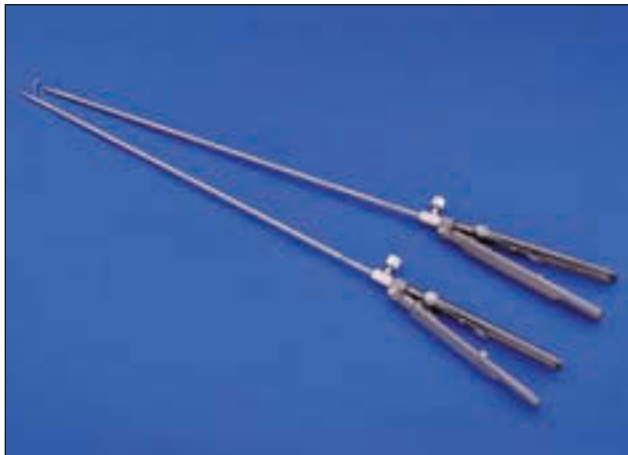
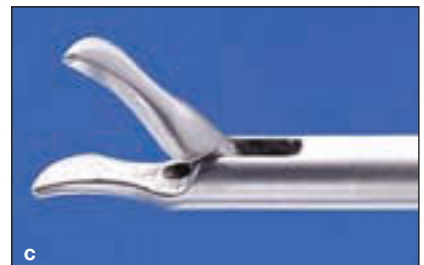
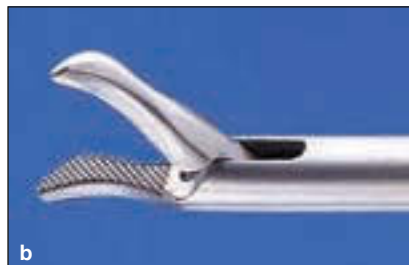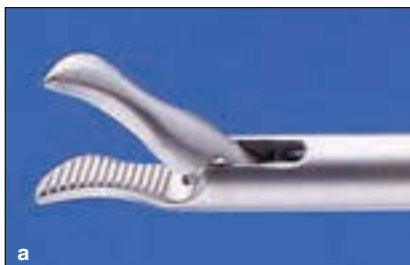Fig. 9
Needle holder and assistant needle holder.

4.3 Assistant Needle Holder

The assistant needle holder is the instrument that assists the needle holder in placing the suture (**Figs. 9–10**).

In general, a second needle holder is used to allow good control of the needle and at the same time allow both hands to be used equally. Any forceps can be chosen as assistant needle holder, preferably with flat jaws that allow both the suture and the tissues to be grasped securely.



Figs. 10a–c
Jaws of different needle holders.

4.4 Knot Pusher

The knot pusher is an instrument that allows a previously tied extracorporeal knot to be introduced into the abdominal cavity. There are different knot pushers (**Fig. 11**) depending on the type of knot: simple half hitch, Roeder.

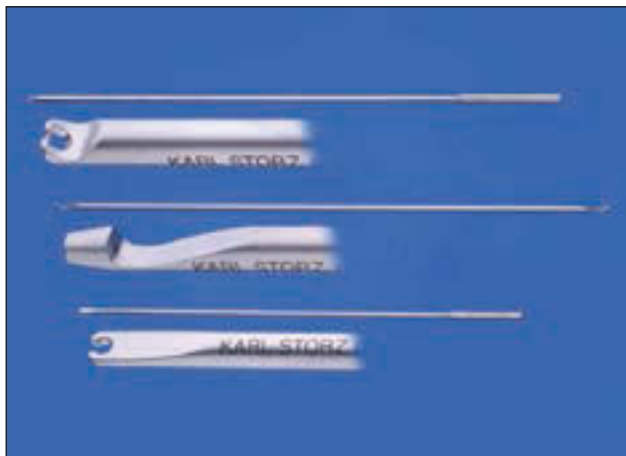


Fig. 11
Knot pusher.

4.5 Scissors

The scissors used to cut suture material must not be the same as those used for dissection because they are extremely delicate.

Using dissecting scissors to cut suture material can result in a dramatic decrease of their cutting performance. This effect becomes even more evident at an earlier stage if the scissors are used in combination with electro-surgical instruments.

Scissors vary according to the design of the blades: straight, curved, hooked. Hooked scissors are preferable for cutting sutures (**Fig. 12**).



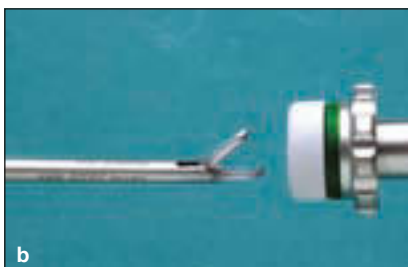Fig. 12
Different types of laparoscopic scissors.

5.0 Insertion and Removal of the Needle from the Abdominal Cavity

The insertion and removal of the needle depend on its shape and size, and not least, on the trocar size.

Straight needles can be inserted in any type of trocar or even directly through the abdominal wall, while curved needles

can be introduced in 6-mm trocars up to 12 mm in length, in 11-mm trocars up to 28 mm, in 13-mm trocars up to 34 mm and in 15-mm trocars up to 40 mm in length (**Figs. 13–15**).



Figs. 13a–c


The sequence demonstrates how the needle holder is inserted in the cannula (**a**)

and finally protrudes from the distal opening of the 13-mm trocar (**c**).



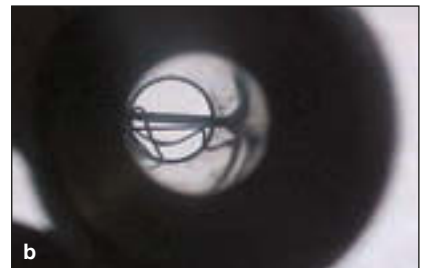Figs. 14a–c

Sequence demonstrating loading of the suture and thus of the needle inside the cannula.



Figs. 15a–d ▶

Sequence demonstrating the subsequent insertion of the cannula loaded with suture and needle inside the trocar.



Figs. 16a, b ▶

When the length of the needle exceeds the inner diameter of the cannula, this can pose problems of its own, such as the needle becoming impacted inside the cannula.

During insertion and removal of the needle from the abdominal cavity, constant videoendoscopic monitoring of the port in use is mandatory, because there is always a risk of the needle becoming impacted in the valve and dropping into the abdominal cavity (**Fig. 16**).

The ideal would be to use trocars with an automatic valve. There are specific introducers on the market, which are inserted in the trocars and allow the needle to be passed through safely.

The needles can be introduced directly through the cutaneous ports but with the risk of iatrogenic injury to the abdominal wall, bleeding and subcutaneous emphysema. To do this, it is necessary to remove the trocar from the abdominal wall, introduce the needle holder in the trocar and pick up the end

of the suture, then withdraw the needle holder from the trocar until the needle is located about 10 cm from the distal end of the trocar; at this point, the needle holder is reinserted in the trocar and the suture is grasped about 3 cm from the swage of the needle. The needle holder, needle, suture and trocar can then be introduced into the abdominal wall, seeking to find the correct route.

To remove the needle, apart from the methods described above, taking care not to mount the needle in the needle holder but handling it by the suture to provide it with some freedom of motion, it is possible to straighten the needle in the abdominal cavity using two needle holders so that it can be removed directly through the 6-mm trocar but with the risk of breakage of the needle itself or of the needle holders.

6.0 The Stitch

The stitch is one of the most difficult steps in laparoscopic suturing.

It is always necessary to refer to the "ideal stitch" which is obtained when the angles between the wound, needle and needle holder are each 90 degrees and the suture line is parallel to the needle holder. To come as close as possible to this situation, there are three variables:

- choice of principal needle holder (central or lateral trocar)
- straight or reverse mounting of the needle in the needle holder
- angle between the needle and needle holder

Once the needle has been introduced into the abdomen and the principal needle holder has been adjusted relative to the suture plane, the needle is mounted in the needle holder without locking at the level of its maximum curve. At this point the assistant needle holder, grasping the suture 2 cm from the needle swage, causes the needle to rotate forward or backward through 180 degrees, in this way allowing the

orientation of the needle to be changed from forward to back or vice versa.

The assistant needle holder will be able to perfect the angle between needle and needle holder with traction on the suture close to the swage or small pushes on the tip of the needle. The same maneuver may be performed by the same needle holder supporting the needle on sufficiently rigid tissue.

After locking the needle by closing the needle holder, it is then possible to place the stitch. The movement transmitted to the needle holder and needle must consist of rotation only (Figs. 17-23).

If it is desired to place the suture more deeply it is possible to externally rotate the wrist or move the grip of the needle holder as far as possible toward the swage.

When the needle is extracted from the tissue, one should attempt to grasp the needle with the needle holder immediately, avoiding letting it drop and losing time required for repositioning.

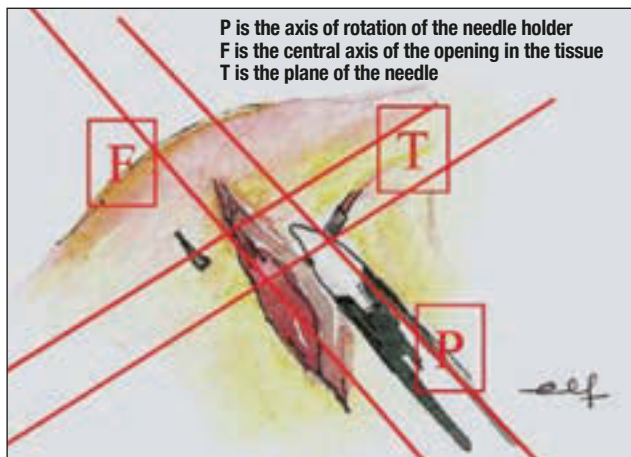


Fig. 17
Coordinates of the suture plane.

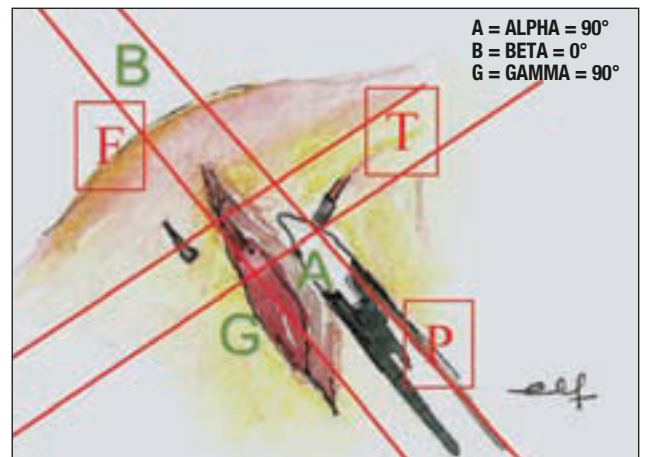


Fig. 18
Suture angles.

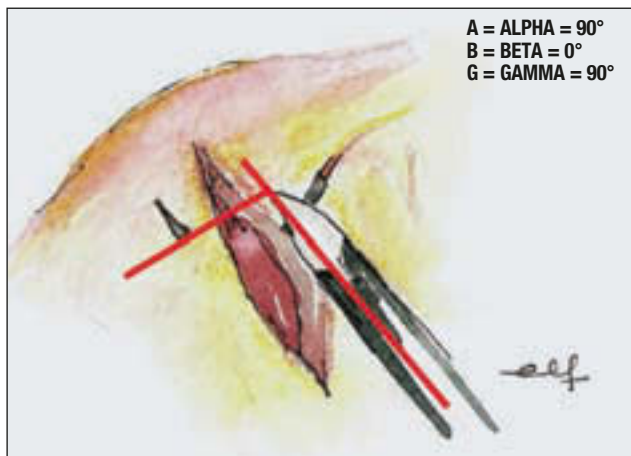


Fig. 19
Ideal suture angles.

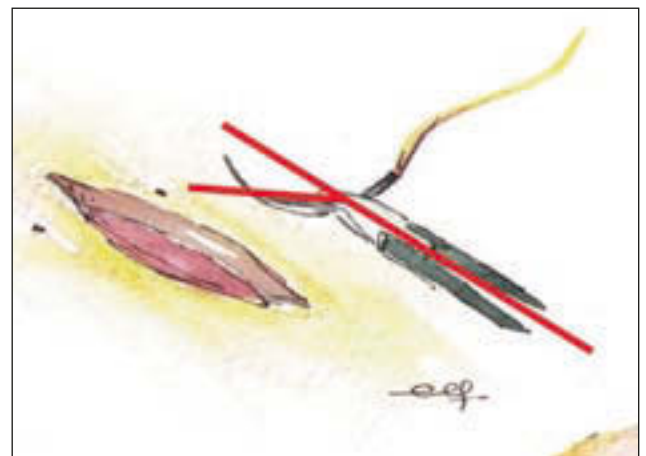



Fig. 20
Modifications of the suture angle: tip opened 110°.



Figs. 21 a, b
Modifications of the suture angle: tip closed 45°.

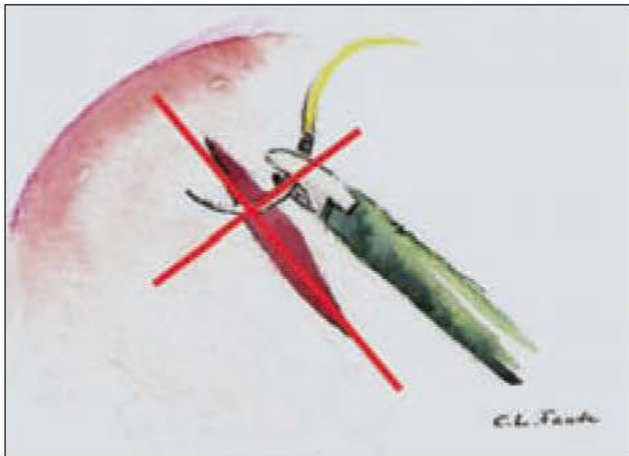


Fig. 22
Cross to check correct needle trajectory.

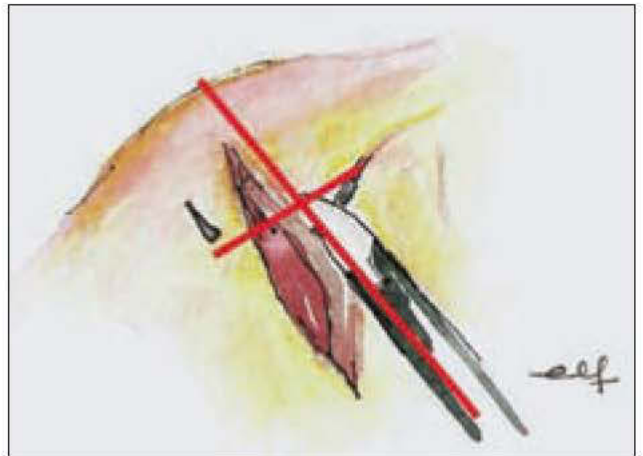


Fig. 23
Correct axis of the suture line.

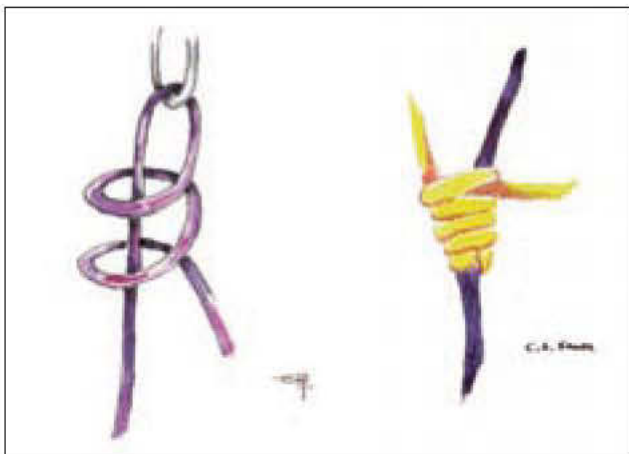


Fig. 24
Extracorporeal knots.

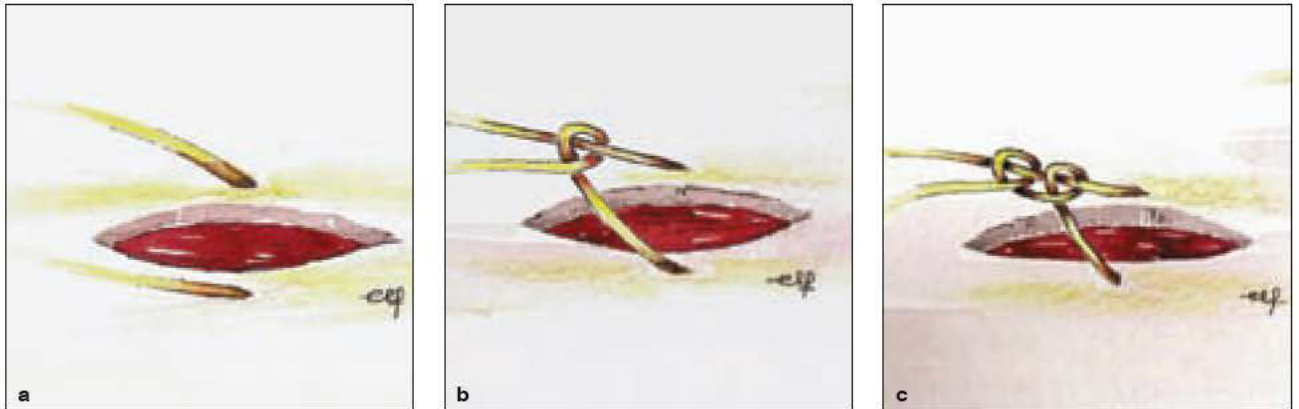
7.0 Extra-corporeal Knots

These are knots prepared outside the abdominal cavity and then pushed in.

There are various types of extracorporeal knots and the ones most commonly used are:

- Half hitch
- Slipknot (Roeder)
- Weston (Fig. 24)

The half hitch is tied externally, passing the active strand around the passive strand and then, maintaining moderate tension on both ends, the knot pusher, supported on the active strand, pushes this half hitch down and laterally, taking care to keep the two strands parallel.



Figs. 25a–c
Extracorporeal knot: half hitch.

To tie a surgical knot, it is important that:

- the first two half hitches be identical, that is, the two strands always maintain the same role;
- the third half hitch, which has the locking role, is opposite to the previous one, that is, the strand that was previously passive becomes active or vice versa (**Figs. 25–27**). This knot is easy and quick to tie and holds excellently if tied according to the rules.

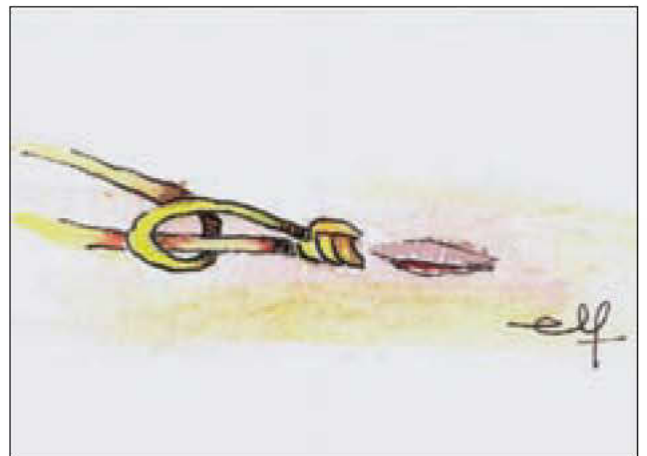


Fig. 26
Extracorporeal knot: half hitch.

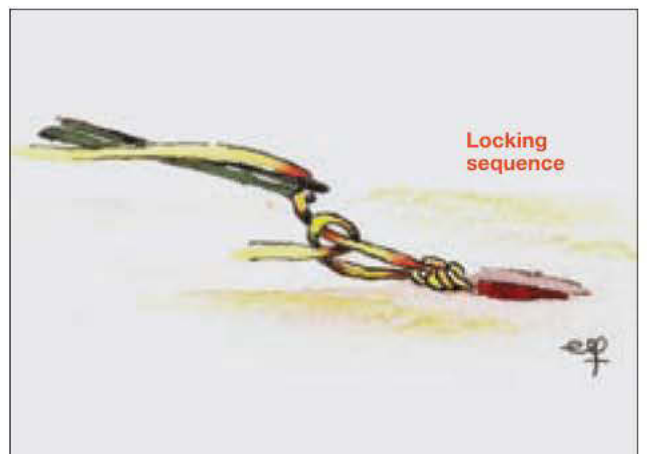


Fig. 27
Extracorporeal knot: half hitch (locking sequence).

The Roeder knot is tied as follows:

- A first half knot is tied,
- the active strand of the suture makes three turns around both strands of the previously formed loop,
- the active strand makes a second half knot on the passive strand of the loop,
- the knot is tightened.

It is important to avoid crossing the two strands of the knot by asking the assistant to place a finger on the trocar to separate the two ends of the suture.

This knot is secure and easy to tie with a good sliding capacity and at the same time optimal holding strength so it provides a high level of safety when ligating vascular pedicles (**Figs. 28–31**).

The Weston knot is made with

- an initial half knot
- the active strand is first wrapped around the passive strand of the previously formed loop
- then twisted around both strands of the loop, making the active strand pass through the loop that has just been made
- and finally the active strand passes from anterior to posterior in the loop closest to the surgeon's hands

It is pushed into the abdomen by simply pulling the passive strand and locked pulling the two ends in opposite directions.

As with the Roeder knot, it is important to keep the two ends of the suture separate. This is a knot with optimal smoothness but the holding strength of the knot is not optimal especially with suture sizes less than zero.

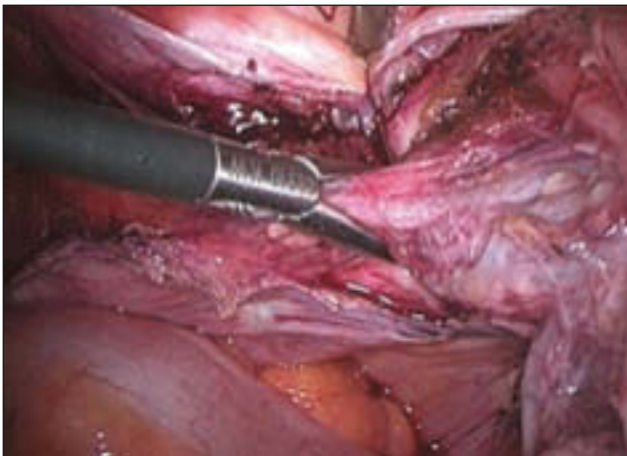

Fig. 28
The stitch is placed in sequence.

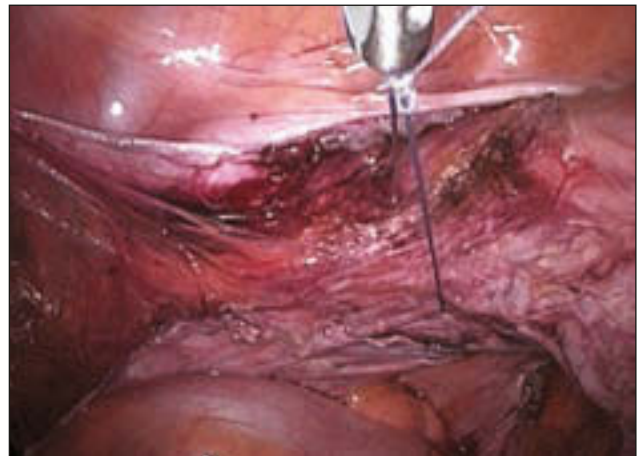

Fig. 29
The margins are approximated by the knot.

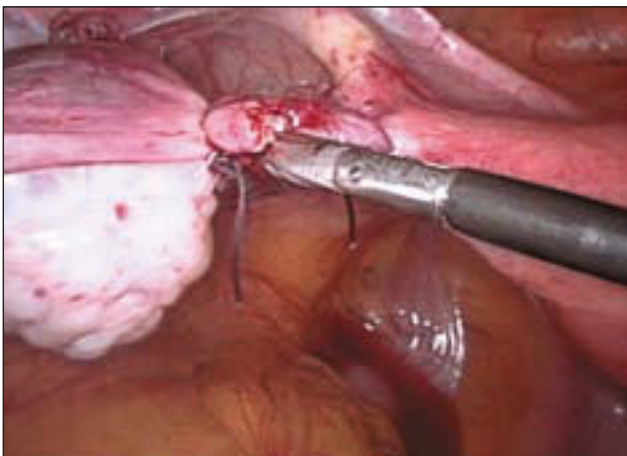


Fig. 30
Suture placed at the infundibulum.

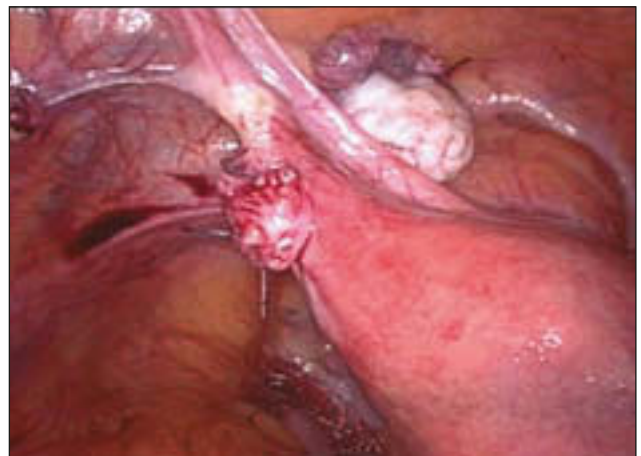

Fig. 31
Final outcome of the suture.

8.0 Intracorporeal Knots

To tie an intracorporeal knot, it is important to perform the following steps in order:

- the needle holder picks up the suture 2 cm from the swage and moves it from the opposite side with respect to the needle's exit point, passing above the suture hole
- the assistant needle holder wraps twice around the suture after which it grasps the end of the suture
- the two ends are then pulled in opposite directions with the two needle holders to pull the first square knot taut.
- the maneuver can be repeated with a single turn each time until the surgical knot is complete (**Figs. 32, 33**).

The result should be a surgical knot defined classically as a succession of half knots and/or half hitches in which the last should be the reverse of the previous one. However, the first must be a double half knot, that is, a half knot made by passing the end of the suture twice through the same loop; this prevents the knot from becoming slack while the next is being tied.

In this step it is very important never to mount the needle in the needle holder because this is associated with the risk of iatrogenic injury to adjacent organs.

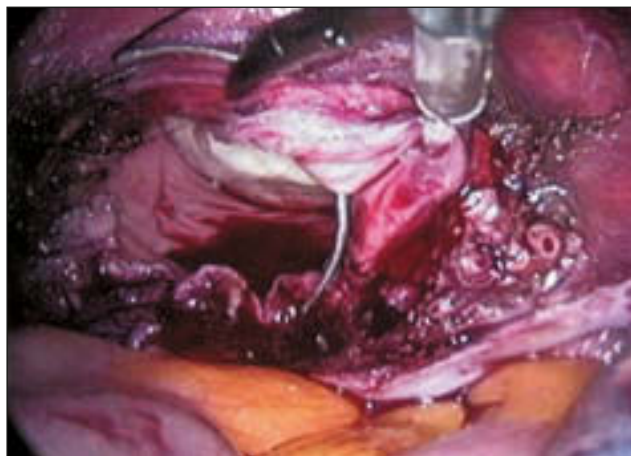


Fig. 32
Preparation of the knot.

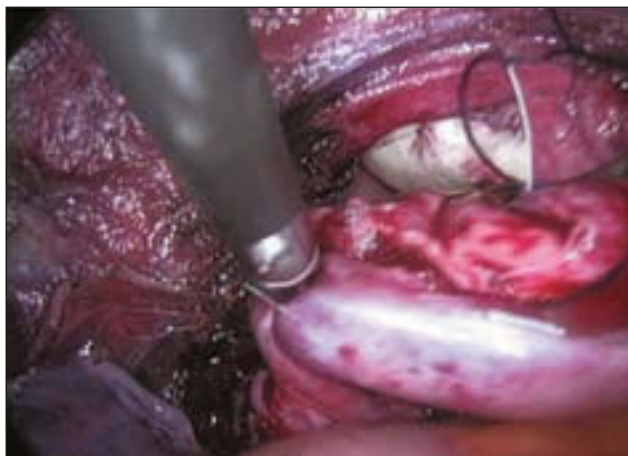

Fig. 33
Preparation of the knot.

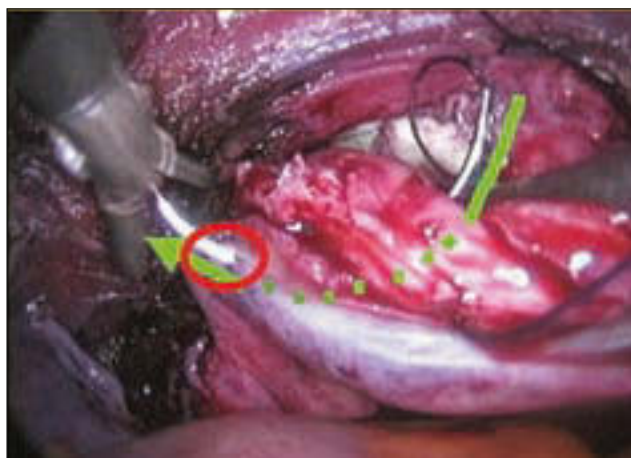


Fig. 34
Intracorporeal knot-tying depends on correct preparation.

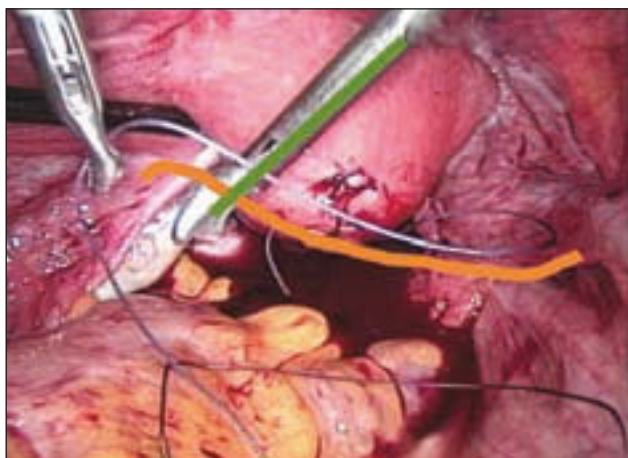


Fig. 35
The line of the suture (green line) allows the knot to be tied rapidly.

9.0 Endoloop

There are ready-made loops that can be used in laparoscopy for hemostasis of vascular pedicles and pedunculated fibromas.

They are available in Vicryl, Prolene and PDS and usually employ the Roeder knot. The guiding aid in which the suture runs also acts as knot pusher.

The endoloop, used for ligatures, is a variation of the Roeder knot suitable for tonsillectomy operations. This is a preformed

loop for making a fisherman's knot. The free end is mounted in a plastic guide tube and caught at the detachable proximal end of the guiding tube. If it is not possible to use a trocar with a silicone leaflet valve, an adaptor must be used to prevent gas leakage. After placing the loop around the tissue that is to be ligated, the proximal end of the guiding tube is broken off and used to exert traction on the free end of the thread while the distal part of the tube is used to push the knot.

Recommended Reading

1. AL FALLOUJI M: Making loops in laparoscopic surgery: state of art. *Surg Laparosc Endosc* 1993; 3(6):477–81
2. BABETTY Z, SUMER A, ALTINTAS S: Knot properties of alternating sliding knots. *J Am Coll Surg* 1998;186(4):485–9
3. BONARDINI L, ROSATO S: *Suture e fili chirurgici*, Ed Mediche Italiane, 1989
4. BROWN RP: Knotting technique and suture materials, *Br J Surg* 1992;79(5):399–400
5. DORSEY JH, SHARP HT, CHOVAN JD, HOLTZ PM: Laparoscopic knot strength: a comparison with conventional knots. *Obstet Gynecol*. 1995 Oct;86(4 Pt 1):536–40.
6. EMAM TA, HANNA GB, KIMBER C, DUNKLEY P, CUSCHIERI A: Effect of intracorporeal-extracorporeal instrument length ratio on endoscopic task performance and surgeon movements. *Arch Surg* 2000; 135(1):62–5
7. FREDE T, STOCK C, RENNER C, BUDAIR Z, ABDEL-SALAM Y, RASSWEILER J: Geometry of laparoscopic suturing and knotting techniques. *J Endourol* 1999; 13(3):191–8
8. GOMEL V, TAYLOR PJ: *Laparoscopia ginecologica*. Diagnostica e chirurgia, UTET, 1998
9. HANNA GB, SHIMI S, CUSCHIERI A: Optimal port locations for endoscopic intracorporeal knotting. *Surg Endosc* 1997; 11(4):397–401
10. HANNA GB, FRANK TG, CUSCHIERI A: Objective assessment of endoscopic knot quality. *Am J Surg* 1997; 174(4):410–3
11. KADIRKAMANATHAN SS, SHELTON JC, HEPWORTH CC, LAUFER JC, SWAIN CP: A comparison of the strength of knots tied by hand and at laparoscopy. *J Am Coll Surg* 1996;182(1):46–54
12. LUKS FI, DEPREST J, BROSENS I, LERUT T: Extracorporeal surgical knot. *J Am Coll Surg* 1994; 179(2) :220–2
13. MEDINA M: Analysis and physics of laparoscopic intracorporeal square-knot tying. *JLS* 2005;9(1): 113–21.
14. ROMEO A, MINELLI L: *Manuale dei nodi e delle tecniche d'annodamento in laparoscopia*, EGES Edizioni, Verona, 2006
15. SHARP HT, DORSEY JH, CHIVAN JD, HOLTZ PM: The effect of knot geometry on the strength of laparoscopic slip knots. *Obstet Gynecol* 1996;88(3):408–11
16. TRIMBOS JB, RIJSSEL EJ, KLOPPER PJ: Performance of sliding knots in monofilament and multifilament suture material. *Obstet Gynecol* 1986; 68(3): 425–30
17. VAN RIJSSEL EJ, TRIMBOS JB, BOOSTER MH: Mechanical performance of square knots and sliding knots in surgery: comparative study, *Am J Obstet Gynecol* 1990;162(1):93–7

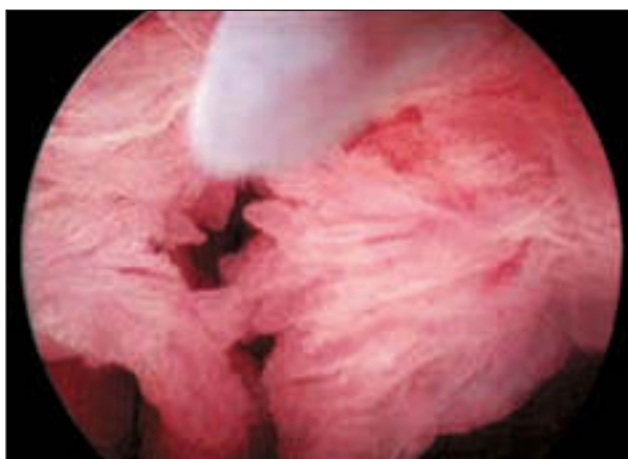Chapter VI

**The Role of Diagnostic Laparoscopy and
Transvaginal Endoscopy (TVE) in Infertility and
Assisted Reproduction Technology (ART)**

Emmanuel Lugo¹, Carlo Tantini² and Luca Mencaglia¹

Centro Oncologico Fiorentino, Florence, Italy

²Department of Gynecology and Obstetrics,
Hospital of Cecina, Italy



1.0 Introduction

Exploring the peritoneal cavity and visualizing its organs is essential in the diagnosis of female pelvic pathology, especially in the case of infertility or pelvic pain of non-specific etiology.

The pelvis can be visualized endoscopically by *diagnostic laparoscopy or transvaginal endoscopy*.

Both techniques have benefits and drawbacks so that it is not possible to choose definitively between them. In summary, it can be stated that both are minimally invasive endoscopic techniques that require general anesthesia in the vast majority of cases (even if performed as day surgery) and the use of a fully equipped operating room. Although many authors have suggested the use of local anesthesia for these outpatient

procedures applying either technique, general anesthesia is nearly always necessary in our experience.

Diagnostic laparoscopy provides a panoramic view of the pelvis – not feasible by transvaginal endoscopy (TVE) – and facilitates switching to endoscopic surgery in the event of pelvic pathology. From the surgical point of view, transvaginal endoscopy has certain limitations. With the aid of a 30°-hysteroscope and fluid medium for distension of the peritoneal cavity, the transvaginal approach undisputably provides some absolutely unique angles of vision and types of images. Nonetheless, it must be said, that TVE allows salpingoscopy of the distal tubal segment to be performed only in selected cases.”

2.0 Laparoscopic Diagnosis

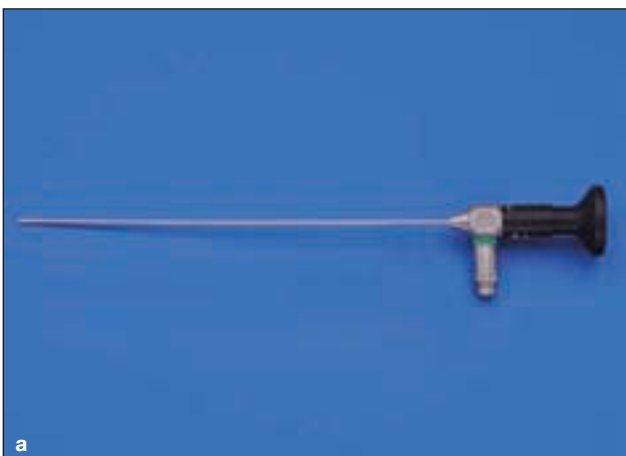
Diagnostic laparoscopy is indicated in infertile patients if tuboperitoneal pathology is suspected to be the primary cause of inhibited female reproduction. Among the most common indications are suspected tubal defects or irregularities on the hysterosalpingogram, previous abdominal surgery suggesting the tentative diagnosis of adhesions, and signs of endometriosis or hydrosalpinx on ultrasound. Diagnostic laparoscopy allows conversion to open surgery and immediate surgical treatment of any unexpected pelvic pathology prior to initiating **Assisted Reproductive Technology (ART)** procedures.

Laparoscopy combined with diagnostic hysteroscopy is therefore considered the gold standard for the assessment of the pelvis and female reproductive tract. Even in the case of Mullerian malformation, the combined use of laparoscopy and hysteroscopy is ideal for a definite diagnosis since it allows assessment of the exterior contour of the uterine corpus. In fact, hysteroscopy on its own does not allow differential

diagnosis between a septate uterus and bicornuate uterus so it must always be supplemented by diagnostic laparoscopy or transvaginal ultrasound.

Diagnostic laparoscopy is also indicated in infertile patients to exclude the presence of pelvic pathology when 1st level ART procedures for a period of 6–8 months did not yield a positive result. Laparoscopy must be scheduled during ovulation or the second phase of the cycle and must always be combined with diagnostic hysteroscopy to evaluate the condition of the uterine cavity and allow endometrial biopsy sampling, if needed.

The diagnostic measures above must be performed with utmost care and precision to prevent iatrogenic trauma to the tissue being examined. Modern technology allows minimally invasive diagnostic laparoscopy by use of miniaturized telescopes, instruments and trocars.



Figs. 1a, b
Laparoscopes with diameters of 1 mm, 2 mm, 5 mm and 10 mm.

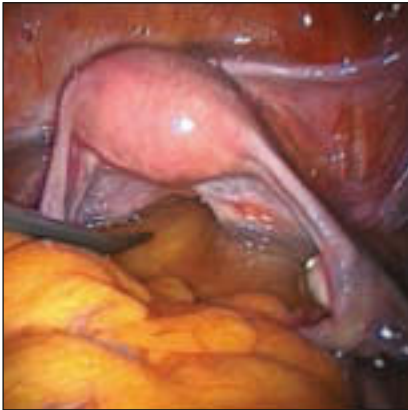

Fig. 2
Panoramic view of the pelvis.

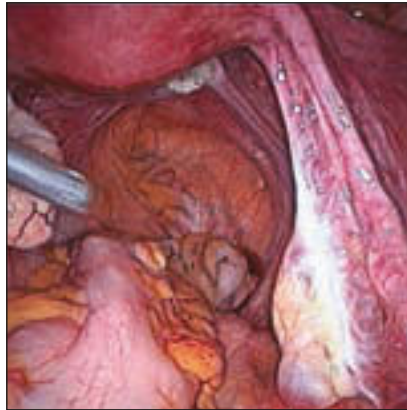


Fig. 3
Endoscopic view of the tube and ovary.

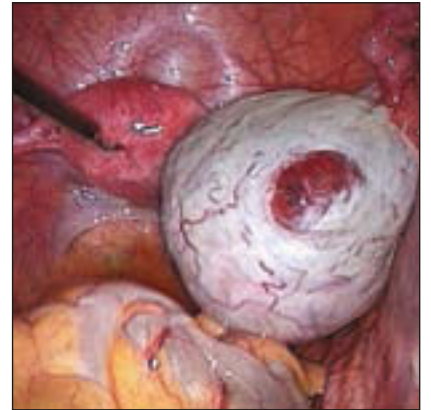

Fig. 4
Endoscopic view of the ovary.

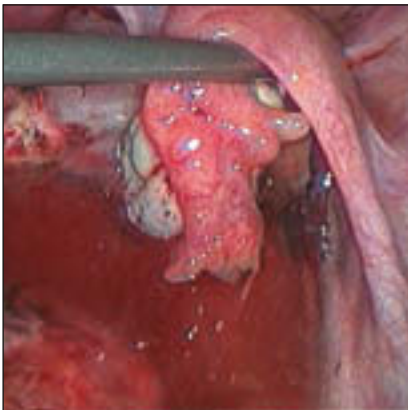


Fig. 5
The left tube is positioned prior to chromopertubation.

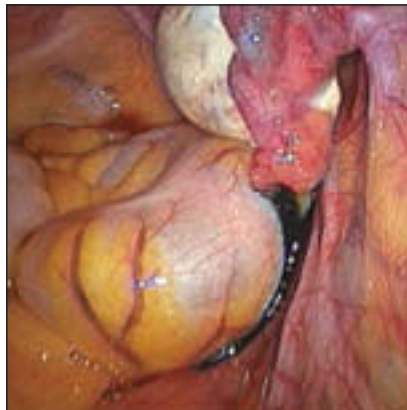

Fig. 6
Injection of methylene blue dye.

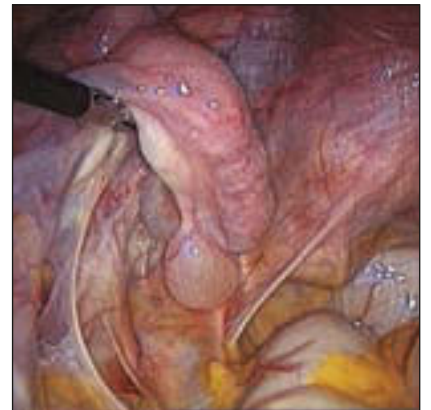

Fig. 7
Abnormal dilatation of the tube, sactosalpinx or hydrosalpinx.

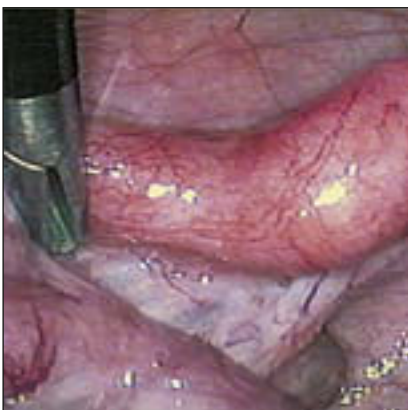

Fig. 8
Salpingitis of the isthmus.

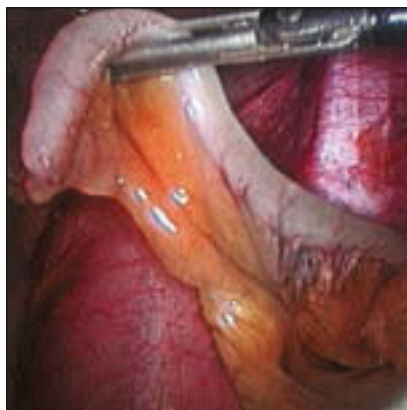


Fig. 9
Appendix.

However, the surgeon must be readily prepared for endoscopic-guided surgical treatment of any pathology encountered during the diagnostic session.

Diagnostic laparoscopy is normally performed as day surgery with the patient being discharged on the same day (Figs. 1–9).

2.1 Patient Positioning

Positioning on the operating table involves the cooperation of the awake patient. The patient must be placed in gynecological position with her arms close to the body and her legs placed in stirrups, avoiding positions that might cause compression of the plexuses or peripheral nerves. In addition, the legs must be positioned low to prevent interference with the surgeon's maneuvers conducted through the lateral ports. It is preferable to use a uterine manipulator to facilitate viewing the pelvic organs and for injecting methylene blue dye for chromopertubation.

Normally, diagnostic laparoscopy is performed through a double access:

- periumbilical port for the laparoscope and videocamera;
- along the midline of the lower abdomen for the atraumatic forceps needed to manipulate the pelvic organs.

The diameter of the trocars varies according to the diameter of the chosen instruments and laparoscope.

3.0 Anesthesia

Diagnostic laparoscopy can be performed under both local and general anesthesia.

Various authors have suggested using local anesthesia with periumbilical skin infiltration and intravenous sedation. In this case it is vitally important to keep abdominal distension very low with insufflation of 1–2 liters of CO₂ at the most to avoid pain caused by abdominal distension and problems related to spontaneous respiration.

In the case of general anesthesia, agents that guarantee rapid recovery can be used so that the patient can be discharged a few hours after the procedure. In this case, too, local infiltration anesthesia applied to the trocar insertion area has proven to be useful to reduce postoperative pain.

4.0 Instrumentation

- 5 mm-laparoscope and videocamera
- Insufflation system
- Xenon cold light source
- 6 mm-trocar
- Veress needle
- Atraumatic grasping forceps
- Suction / irrigation system
- Uterus manipulator

5.0 Technique

Pelvic endoscopy allows visual inspection of the peritoneal cavity and the female genital tract involved in the reproductive process.

An extensive diagnostic laparoscopy must include full visualization of the entire peritoneal cavity, a panoramic view of the pelvis and pouch of Douglas, the peritoneal liquid, the uterosacral ligaments, thorough inspection of the ovarian and tubal surfaces (including the fimbriae) and chromopertubation.

Various types of instruments can be used for laparoscopy in infertile patients:

- Traditional laparoscopy, performed by using 5 mm- or 10 mm-laparoscopes, provides optimal visibility at relatively low expenditures. The second port is a 5 mm-trocar through which an atraumatic grasping forceps can be used.

- Minilaparoscopy is performed with a laparoscope, 3 mm or even 1.2 mm in diameter. The laparoscope may be introduced through the Veress needle; the atraumatic grasping forceps (diameter 3 mm) may be used through a second port. The principal technical problem in this particular case is related to the extremely reduced diameter of the laparoscope which provides only low-level lighting conditions in the operative field, even given the use of a xenon light source. It is therefore necessary to keep the laparoscope close to the area to be inspected to obtain enough light. In addition, this type of laparoscope is particularly fragile and delicate (**Figs. 10–12**).

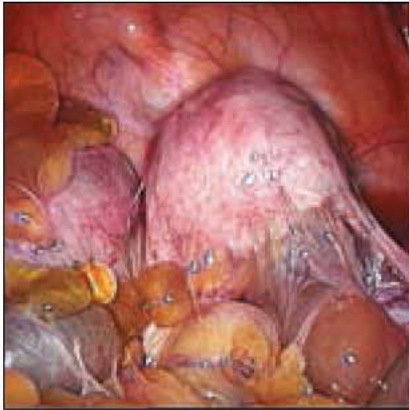

Fig. 10
Diffuse, delicate adhesions in the pelvis.

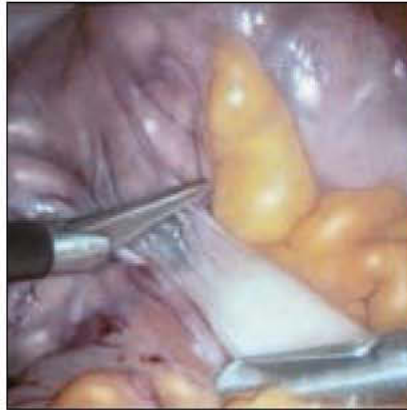

Fig. 11
Lysis of delicate adhesions.

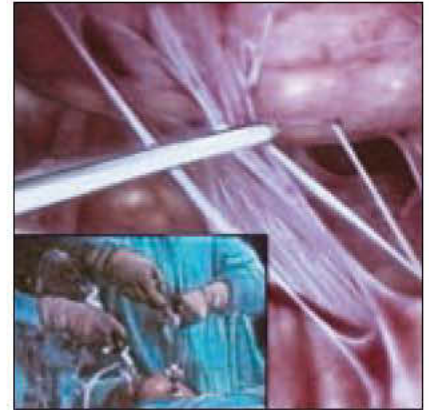


Fig. 12
Lysis of diffuse adhesions.

6.0 Postoperative Care

The patient is discharged 2 to 6 hours after regaining consciousness if no additional surgical procedure has been performed. A mild analgesic is usually given.

7.0 Transvaginal Endoscopy (TVE)

A new endoscopic technique known as transvaginal endoscopy (TVE) has been developed recently. It can be performed as a day procedure. With a miniature endoscope introduced through the vaginal wall it is possible to visualize the pelvic organs, evaluate tubal patency and perform salpingoscopy.

TVE is a simple, safe, precise and effective procedure which, in combination with transvaginal ultrasound and hysteroscopy, allows the main organs involved in reproduction (and infertility) to be assessed with good patient compliance. This technique is a new alternative option in the field of gynecologic endoscopy for diagnosis and surgical treatment in selected cases.

Set for Transvaginal Endoscopy (TVE)

- 30°-hysteroscope, (diameter 2.7 mm) and videocamera
- Microprocessor-controlled suction / irrigation system (HAMOU ENDOMAT®)
- Xenon cold light source
- Specific trocar needle system for use in TVE, (diameter 3.9 mm, length 25 cm) (**Fig. 13**)



Fig. 13
Set for transvaginal endoscopy comprising: 5 mm sheath with a 5 Fr working channel, dilating sheath, 30°-hysteroscope (diam. 2.7 mm), 3.5 mm diagnostic sheath with Veress needle.

8.0 Patient Selection Criteria

This method is indicated mainly for infertile patients or those with pelvic pain.

Potential indications for diagnostic TVE:

- Diagnostic assessment of infertility
- Visualization of the pelvis after conservative medical therapy or surgical treatment.
- Pain mapping
- Diagnostic assessment of patients with pelvic endometriosis
- Study of tubal and ovarian physiology
- Early diagnosis of extrauterine pregnancy
- Visualization of the appendix

Initially, bimanual vaginal examination and transvaginal ultrasound are performed to assess the position of the uterus

and to exclude the presence of pathology in the pouch of Douglas. The purpose of the technique is to visualize and assess the relationships between the tubes and ovaries, the mucosa of the fimbria and ampulla, presence of adhesions or pelvic endometriosis and tubal patency (**Figs. 14–16**).

The contraindications to this technique are an intact hymen, a particularly narrow vagina, vaginal infection, obliteration of the pouch of Douglas or the presence of prolapsed structures in the pouch of Douglas, retroverted uterus and hemoperitoneum.

Emergency situations, such as acute pelvic inflammation or ectopic pregnancy with hemoperitoneum are not indications for TVE because the presence of adhesions or hemorrhage can severely impede visibility. Undoubtedly, TVE and, in particular, transvaginal salpingoscopy are useful modalities for diagnostic purposes.

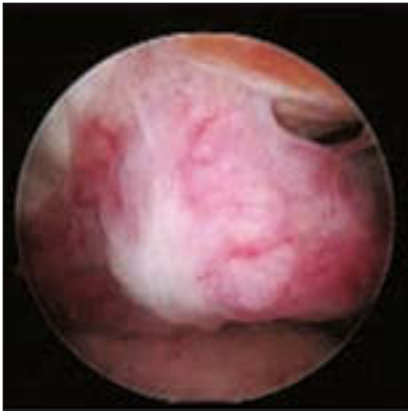

Fig. 14
Tubo-ovarian adhesion.

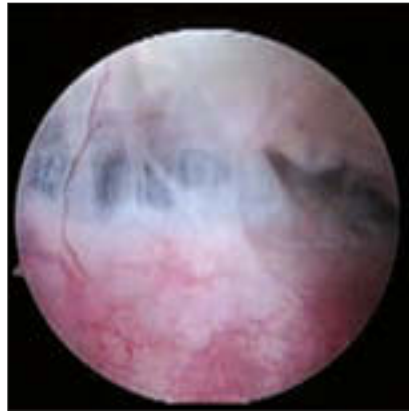

Fig. 15
Microadhesions.

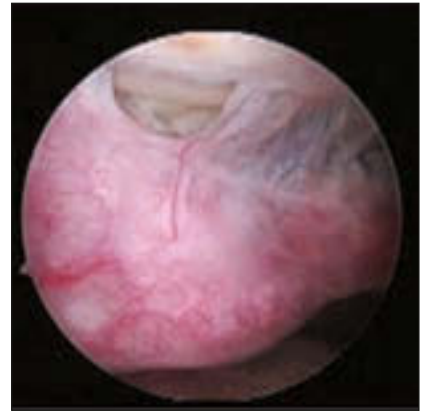


Fig. 16
Microadhesions.

9.0 Anesthesia

Various authors have reported that this technique can be performed under local anesthesia, suggesting a routine outpatient setting. Unfortunately, this is possible only in selected cases with a particularly high pain threshold since

the maneuvers to visualize the pelvic organs are quite painful demanding for general anesthesia in the vast majority of cases.

10.0 Technique

Transvaginal endoscopy is usually performed from the seventh day of the cycle onwards. After placing the patient in dorsal lithotomy position and vaginal disinfection with aqueous chlorhexidine solution, the procedure commences with a diagnostic hysteroscopy. A 30°-hysteroscope (diam. 2.7 mm with a 3.5 mm-sheath) is introduced into the vagina. The vaginal walls are gently expanded by continuous inflow of normal saline solution up to a maximum pressure of 120 mmHg. After identification of the cervix, the hysteroscope is introduced into the cervical canal and a traditional diagnostic hysteroscopy is performed.

To carry out TVE, after insertion of a Collin speculum in the vagina, the posterior vaginal fornix and the posterior lip of the

cervix are infiltrated with 1.8 ml of local anesthetic (articaine 40 mg with epinephrine 0.006 mg/ml), and the posterior lip is then grasped with a Pozzi forceps and placed under traction. At this point, a trocar needle system designed particularly for this technique is used; the device consists of a type of Veress needle (length 25 cm) (**Fig. 17**), a dilator and an external trocar of diameter 3.9 mm, which are put together before starting the procedure. The system is positioned in the midline 10–15 mm below the insertion of the posterior vaginal wall on the cervix. The release button of a trigger mechanism is actuated which causes the Veress needle to penetrate the vaginal wall. This modality reduces pain and allows the vagina to be perforated without traction. Finally, the distal tip of the needle and dilating sheath are located in the pouch of Douglas.

The Veress needle and dilating sheath are then removed and the same endoscope used for diagnostic hysteroscopy is introduced through the trocar. Once, the correct intra-abdominal position of the hysteroscope's distal tip has been visually confirmed, continuous flow of prewarmed saline solution (37° C) can be started.

Unlike traditional laparoscopy, it is not possible to obtain a panoramic view, so it is appropriate to proceed with imaging in the standard manner. The examination begins with localizing the posterior surface of the uterine corpus. The adnexae are then visualized by on-axis rotation of the hysteroscope and movements to the right and left. Once, the ovary and utero-ovarian ligament have been identified, the tubal isthmus and ampulla are identified and inspected gradually advancing toward the fimbrial tubal portion. The posterior surface of the uterine corpus serves as a guide for moving the endoscope to the contralateral side where the same procedure is repeated. Finally, the pouch of Douglas and uterosacral ligaments are thoroughly inspected (**Figs. 18–20**).

Tubal patency is assessed similarly to traditional laparoscopy by injection of methylene blue dye via a no. 14 Foley catheter previously placed in the uterine cavity (**Fig. 21**).

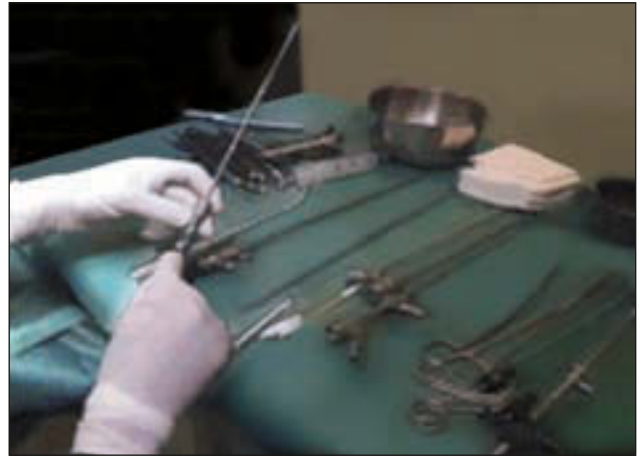

Fig. 17
Preparation of instrumentation used for transvaginal endoscopy.

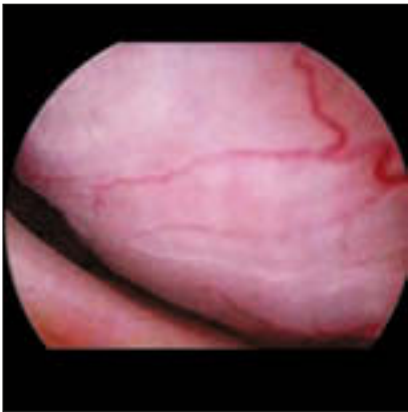


Fig. 18
Posterior surface of the uterine corpus.

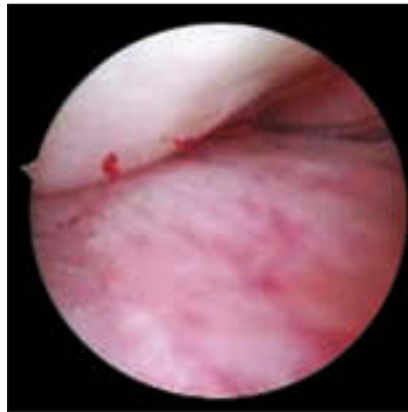
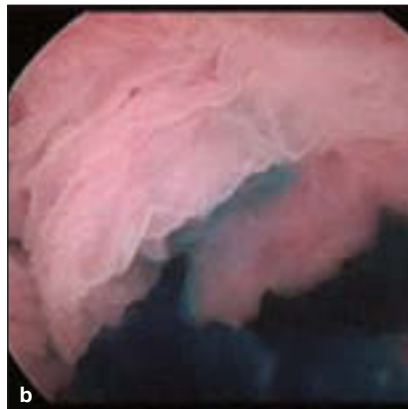
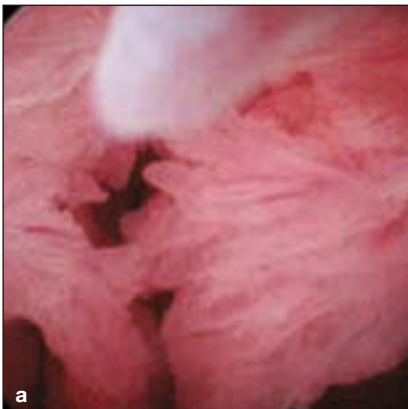


Fig. 19
Ovarian fossa.

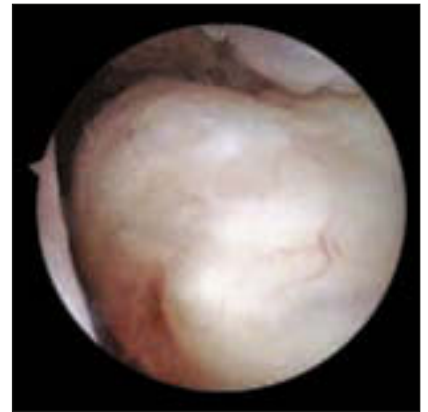
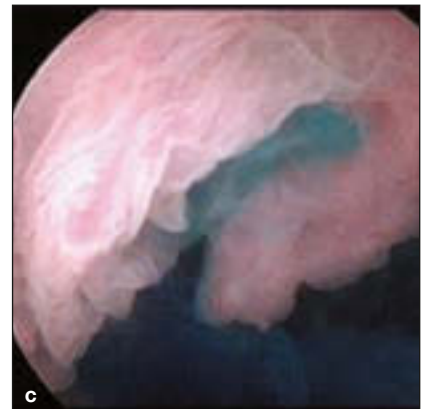
Fig. 20
Surface of the ovary.



Figs. 21a-c
Chromopertubation.

11.0 Salpingoscopy

With sufficient experience in the technique, it is possible to perform salpingoscopy of a few centimeters of the distal tubal segment. The ampulla and the proximal tubal ostium are identified and the endoscope is then inserted. The infundibulum is easily identified by its characteristic concentric folds. The endoscope is gradually advanced and, as a result of the reduced inflow of saline, the ampulla is distended until the longitudinal folds come into view. Visualization of the folds and intra-tubal microanatomy is continued while the endoscope is withdrawn slowly. Canalization of the abdominal tubal ostium is easier in the post-ovulatory phase when the fimbriae are more congested and stiff (**Figs. 22–24**).

Inflow of saline is continued throughout the procedure as this allows the intestine and tubo-ovarian structures to remain floating. The volume of liquid required for distension varies from 200 to 400 ml depending on the duration of the examination (average time 45 min). At the end of the procedure, the liquid is evacuated via the trocar. The point of trocar insertion in the vaginal fornix rarely requires suturing, unless there is bleeding.

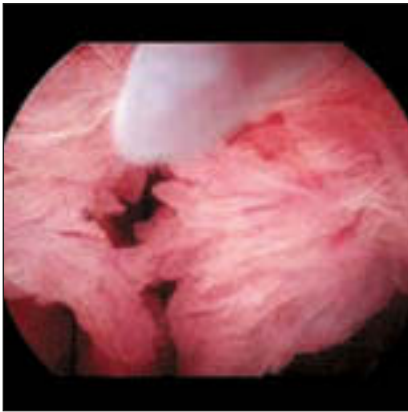

Fig. 22
Fimbriae.

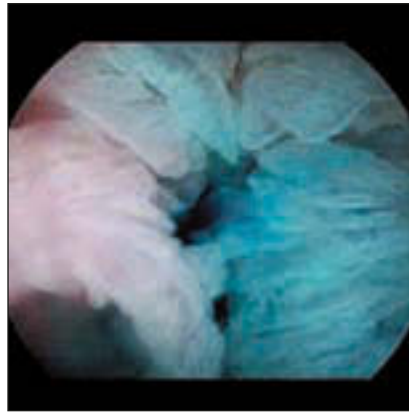


Fig. 23
Infundibulum of the Fallopian tube.

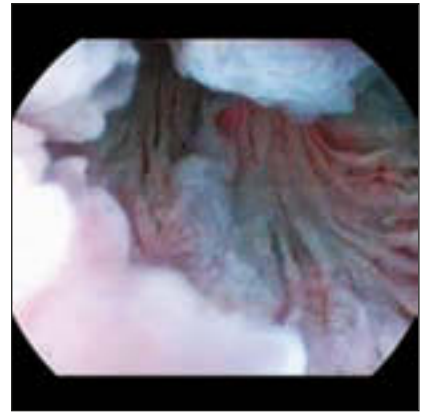


Fig. 24
Major and minor folds.

12.0 Complications

The needle-dilator-trocar system used for TVE has been specially designed to reduce to the minimum accidental injuries which may occur during insertion of the instrument. Moreover, the use of this special TVE instrumentation set is capable to prevent iatrogenically-induced sequelae, such as pelvic infections, rectal or intestinal perforation, bleeding of the vaginal fornix or injury of the posterior surface of the uterine corpus.

To keep to a minimum the potential risk of bleeding in the vagina, it is advisable not to incise the vaginal mucosa but to insert the appropriate-sized needle directly, dilating the vagina a second time and using a vasoconstricting agent in combination with the local anesthetic. In fact, minimal bleeding can give rise to serious problems in terms of unimpeded vision, hence it follows that this complication should be avoided.

13.0 Post-operative Follow-up

The patient is informed of the possibility of watery or bloody vaginal discharge and is advised not to use intravaginal tampons and to abstain from sexual intercourse for one day. Prophylactic antibiotic medication is administered (azithro-

mycin 500 mg/day for 3 days). The patient can be discharged at the end of the procedure or when she has adequately recovered from general anesthesia.

Recommended Reading

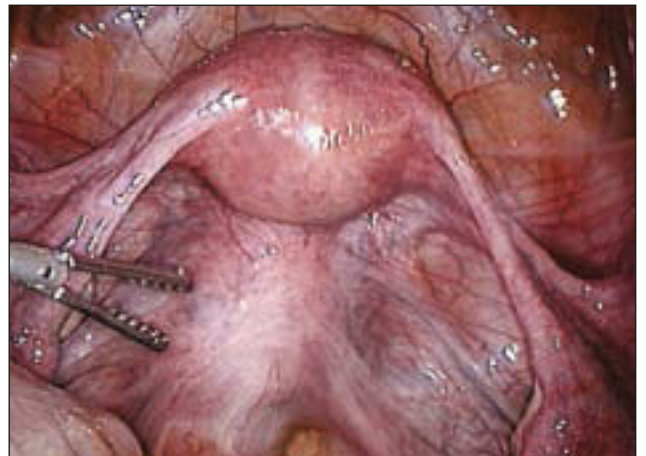
1. DURRUTY G, VERA C, MACAYA R, BIANCHI M, MANZUR A: Resultados de la salpingoneostomía laparoscópica en infertilidad por hidrosalpinx. Departamento de Obstetricia y Ginecología, Unidad de Reproducción Humana, Hospital Clínico Pontificio. Universidad Católica de Chile. *Revista chilena de obstetricia y ginecología*. Santiago (Chile). 2002. 67(6): 488–493
2. GOMEL V: Reproductive surgery. Department of Obstetrics and Gynecology. Faculty of Medicine. University of British Columbia. Vancouver (Canada). 2005. *Minerva*. 57:21–8
3. GOMEL V, ZOUVES C: Laparoscopia quirúrgica en las enfermedades de las trompas. *Cirugía Laparoscópica en Ginecología*. Soderstrom. Segunda edición Marban. (Philadelphia) 1999. (1):87–95.
4. GORDON AG: Tubal Endoscopy. Consultant Gynaecologist, BUPA Hospital Hull and East Riding, Lowfield Road, Anlaby, Hull HU10 7AZ. 2004
5. GORDTS S, CAMPO R, BROSENS I: Microcirugía endoscópica en medicina reproductiva. *Cuadernos de medicina reproductiva*. Pellicer Antonio. Primera edición. Madrid (España). 2002. 8 (1): 55–72
6. HULKA and REICH: Textbook of laparoscopy. (USA). 2002. (1): 285–300
7. LEVINE R: Laparoscopic tubal Sterilization. A practical manual of Laparoscopy. A clinical Cook book. Kentucky (USA). 2002. (1): 107–114
8. MARCONI G., VILELA M., GOMEZ RN, BUZZI J., De ZUNIGA I, QUINTANA R: Salpingoscopia. *Cuadernos de medicina reproductiva*. Pellicer Antonio. Primera edición. Madrid (España). 2002. 8 (1): 213–237
9. YOUNG E, VAN TRILLO: Hidrosalpinx e Infertilidad. *Cuadernos de medicina reproductiva*. Pellicer Antonio. Primera edición. (Madrid) 2002. 8 (1): 89–100

Chapter VII

Techniques of Laparoscopic Tubal Sterilization

Emmanuel Lugo and Luca Mencaglia

Centro Oncologico Fiorentino, Florence, Italy



1.0 Introduction

Female surgical sterilization is the most widely employed method of family planning in the world and the laparoscopic technique is currently used the most. The historical development of this technique dates from the 1970s with *Rioux* and *Corson*. After that came *Kleppinger* (bipolar), *Lay* and *Yoon* (silastic rubber ring), *Hulka* and *Clemens* (plastic clip), *Semm* (endocoagulator), up to *Filshie* who in 1996 suggested the use of a titanium clip with a silicone rubber lining and a kind of “memory function”. Basically, all the laparoscopic techniques are simple, they do not leave an external scar, the costs are lower compared to other

methods, all of the abdominal cavity can be visualized panoramically and the procedure is usually performed as day surgery. In most cases, the period of convalescence is short, which explains the widespread patient acceptance of laparoscopic techniques. Anesthesia is normally general, especially in industrialized countries. In a few cases, patients receive spinal and/or epidural anesthesia. The best form of anesthesia is certainly local anesthesia since it is safer, more economical and without late effects, and can be combined with a sedative and antiemetic.

2.0 Patient Selection

Potential candidates for tubal sterilization are women who want an irreversible method of contraception or those for whom pregnancy itself constitutes a risk factor of potential clinical significance. The sterilization procedure can be performed during or outside the postnatal period. Today, clinicians have the choice among a wide range of endoscopic techniques and it is possible to choose the most suitable time for sterilization. There are a few contraindications, obviously apart from the presence of a gynecologic malignancy or

any other major gynecologic disease. According to the literature, the main contraindications relating to the technique are adhesions following multiple laparotomies, severe obesity, previous history of peritonitis or salpingitis and any other pelvic disease. Ileus and large abdominal tumors are reported in association with a high rate of complications and failures. Severe cardiopulmonary disease or dysfunction can be generic contraindications to tubal sterilization and to the creation of a pneumoperitoneum.

3.0 Patient Positioning

The patient should be placed in gynecologic position with the legs positioned so as not to interfere with maneuvers performed through the lateral trocar ports. An uterine manipulator should be used to facilitate vision and exposure of the fallopian tubes. The Trendelenburg position makes the procedure easier.

Laparoscopic tubal sterilization is normally performed via the following three ports:

- periumbilical primary port, for laparoscope and video camera
- two other lateral ports in the lower quadrant of the abdomen, used for grasping forceps holding the tube and the instrument required for tubal sterilization. The trocar size varies according to the instruments required.

4.0 Instrumentation

- 5 mm laparoscope and videocamera
- Insufflator
- Electrosurgical unit
- Xenon light source
- 6 mm trocar
- Veress needle
- 5 mm atraumatic grasping forceps
- 5 mm scissors
- Suction/irrigation system for irrigation and hydrodissection
- Uterine manipulator

5.0 Technique

There are various techniques of tubal sterilization, which employ electricity, heat or mechanical devices. Surgical interruption of the tubes by transection via a laparotomy

or laparoscopy approach has been found to account for recanalization in up to 4% of cases. For this reason, mere transection with scissors is not recommended.

5.1 Unipolar Electrocoagulation

This is probably the most widely employed method and has a very low failure rate. A panoramic view of the operating field is imperative before proceeding to sterilization. A distorted video image and the loss of overall vision that can occur if the distal lens of the laparoscope is too close to the operating field can confuse even the most experienced laparoscopist. After removing the intestine from the operating field, the junction zone between the proximal and midtubal segments is grasped to dislodge it from the pelvic cavity toward the anterior abdominal wall. Once, the fimbriae have been visualized and the forceps is in correct position, the electro-surgical unit can be connected (**Fig. 1**) to the grasping forceps (**Fig. 2**), a precaution that prevents inadvertent pedal activation, which might cause electrical injury to a vital intra-abdominal organ. In general, a power of 50 W is sufficient to induce complete tubal occlusion by unipolar electrocoagulation of the tubal

tissue between the jaws of the forceps. The tissue damage extends 0.5 – 1 cm laterally. The tube becomes whitish and the passage of electrons through the tissue leads to cellular vaporization and creates a clean cutting effect.

It is appropriate to coagulate about 3 cm of tube. Further applications are frequently required to achieve this effect; they should be toward the medial part of the tube, that is, in the direction of the uterine body to avoid electrical injury to the bowel close to the distal segment or tubal fimbriae.

The tube must be viewed from all sides to confirm that coagulation is appropriate. “Missed spots” in the coagulated target area can be coagulated again. At least 0.5 cm of the adjacent mesosalpinx should also be coagulated, thus cutting off the vascular supply.



Fig. 1
The high frequency electro-surgical unit AUTOCON® II 400, (KARL STORZ Tuttlingen, Germany).

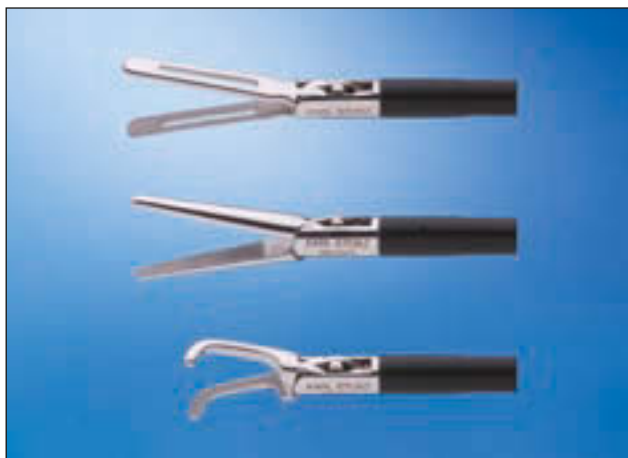

Fig. 2
Grasping forceps.



Fig. 3
Various types of bipolar forceps.

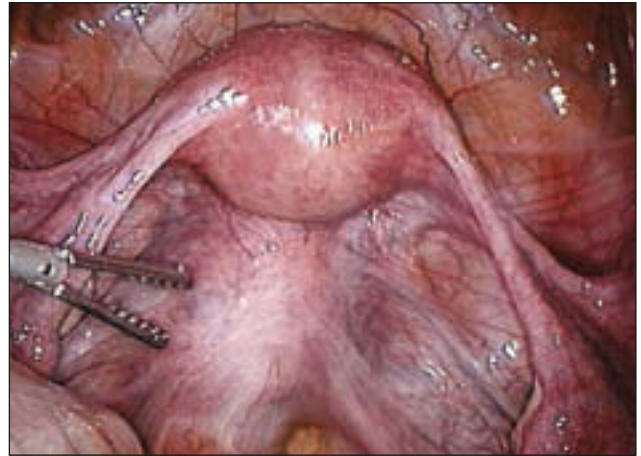


Fig. 4
Point where sterilization is performed using bipolar high frequency current.

5.2 Bipolar Electrocoagulation

The principles of the bipolar mode represent an extremely important element in techniques of female sterilization. Even if the macroscopic appearance of a tube coagulated by bipolar energy can appear the same as that coagulated by means of unipolar energy, it must be considered that the depth of destruction and lateral extension of the thermal trauma is certainly reduced, so the maneuver has to be performed for a longer time to achieve the same effect. In reality, the outcome of any method of electrocoagulation, unipolar or bipolar, depends more on the length of the tubal segment destroyed than on the number of applications. Most authors consider that coagulation of a tubal segment of at least 3 cm is necessary.

The isthmic tubal portion must be grasped with the bipolar forceps (**Fig. 3**) approximately 2 cm from the uterine cornu (**Fig. 4**) so as not to cause injury to the uterine corpus. The HF electrosurgical unit should be set to a power no greater than 25 W using direct current. 2 or 3 applications are often required to achieve coagulation of a 3 cm tubal segment. In the literature there is still controversy whether or not to transect the tube following coagulation.

5.3 Thermal Sterilization

The Waters instrument is used for thermal sterilization or real cauterization. This is a thermal hook, which resembles the resistance of a toaster, sheathed in a heat-resistant plastic protector. The hook is used to grasp the tube and pull it inside the plastic protector where the energy can be activated to induce thermal damage to the tissue. However, the extent of tissue destruction is less than 1 cm.

Another instrument, suggested by *Kurt Semm*, is called the Semm Endotherm. This consists of a type of forceps coated with Teflon, which produces a temperature of 120°C to 160°C and performs cauterization of the tubal segment during an exposure time of 60–90 seconds. The area of thermal injury is limited to the width of the forceps so repeated applications are required to achieve coagulation of 2 to 3 cm of tube.

5.4 Mechanical Devices

Tubal sterilization with Yoon rings

Inbae Yoon first published successful occlusion of the fallopian tubes using a silastic ring in 1974. This technique was then adapted to operative laparoscopy with an applicator 8 mm in diameter, which allows a tubal segment to be lifted up with a pronged forceps inside the applicator sheath and the silastic ring to be put on (**Figs. 5–7**).

Various complications have been reported with this technique, the majority associated with possible injury to the posterior mesosalpinx and with hemorrhage. Rigid or large tubes can be divided by the applicator and bleed. The bleeding can be controlled with bipolar coagulation.

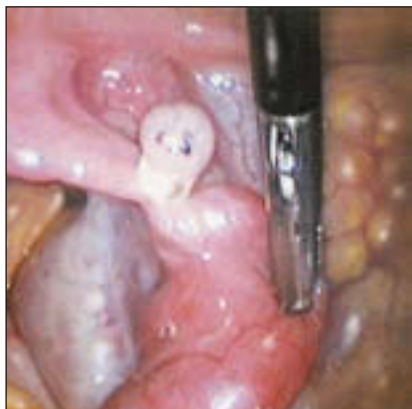

Fig. 5
Tubal sterilization with Yoon rings.

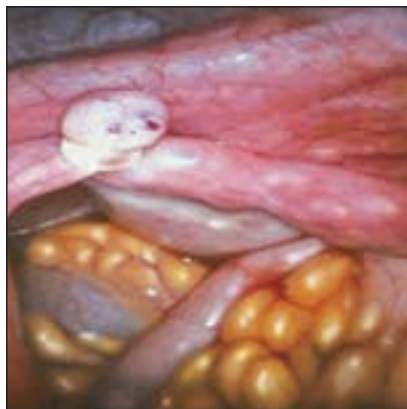

Fig. 6
Detailed view of the site of tubal sterilization with Yoon rings.

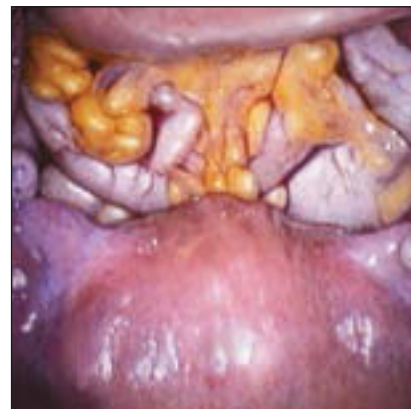

Fig. 7
Methylene blue test following tubal sterilization.

Sterilization with Clips

This method offers the greatest reversibility since only a few millimeters (**Fig. 8**) of the tube are damaged, if properly applied in the isthmic portion. Therefore, the technique can be recommended in women under 30 years who request sterilization. The clips that have proven effective are Filshie and Hulka-Clemens clips. The Filshie clips are made of titanium coated on the inside with silicone, while the Hulka-Clemens clips are made of 3 mm Lexan plastic with jaws articulated by a small metal spring.

An operative laparoscope designed for clip application is available although the clip can be applied through a second port using an applicator. Application through a second port also facilitates exposure, rotating from one side to the other. The clip must be applied at an angle of 90° in the isthmic tubal segment 2 or 3 cm from the uterine cornu. Application of the clip to a different part of the tube can be ineffective due to the diameter of the tubal lumen which may not be occluded completely while pinched between the jaws of the clip. Following application, the clip remains closed owing to a spring mechanism. It is always necessary to reconfirm proper placement of the clip. If residual tubal patency is suspected, a second clip should be applied.

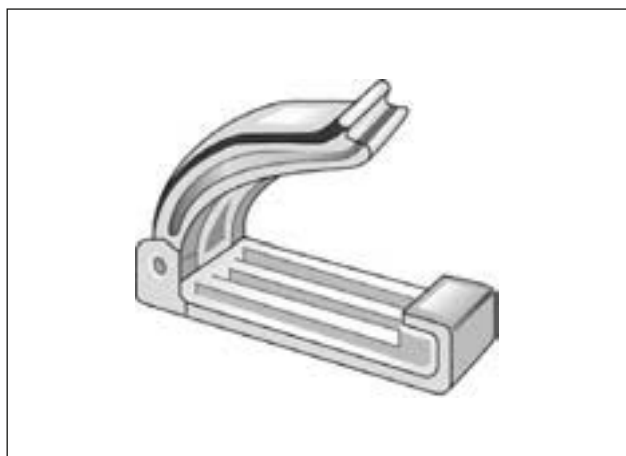

Fig. 8
Hulka-Clemens clip.

6.0 Postoperative Care

The patients are usually discharged 2 to 6 hours after the surgical procedure. It is advisable to give postoperative analgesia to prevent pain due to acute necrosis of the tissue following ring / clip application.

Recommended Reading

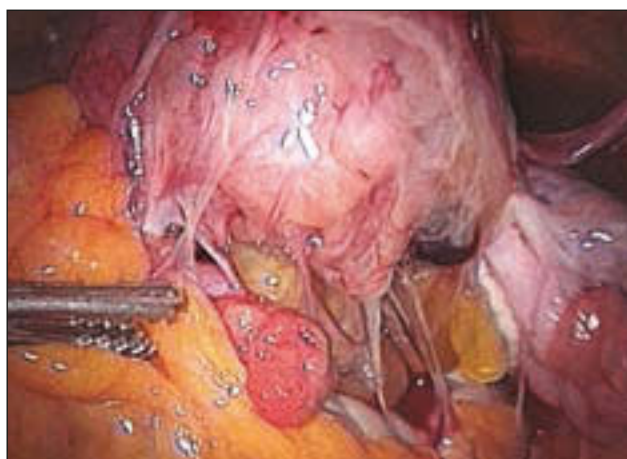
1. HULKA AND REICH: Textbook of laparoscopy. (USA). 2002. (1): 285–300
2. LEVINE RONALD: Laparoscopic tubal Sterilization. A practical manual of Laparoscopy. A clinical Cook book. Kentucky (USA). 2002. (1): 107–114
3. SODERSTROM M. RICHARD, RIOUX JACQUES: Esterilización laparoscópica. Cirugía laparoscópica en ginecología. Philadelphia (USA). 1999. (1): 183–196

Chapter VIII

Laparoscopic Tubal Surgery

Emmanuel Lugo and Luca Mencaglia

Centro Oncologico Fiorentino, Florence, Italy



1.0 Introduction

The most recent technical developments provide surgeons working in the field of infertility with ever more sophisticated and effective methods of surgical reconstruction including endoscopic procedures. On the other hand, it should be borne in mind that the outcomes of assisted reproduction technology (ART) procedures are improving constantly, raising the question of whether surgical repair of a tubal defect may be useful. In practice, if tubal damage is suspected or confirmed, it is necessary to decide whether to directly proceed to ART procedures or to diagnostic laparoscopy and endoscopic surgical treatment of confirmed tubal infertility. This decision is influenced by a range of secondary factors, such as the patient's age, presence of other pathology or changes in semen quality. Younger patients with distal tubal occlusion should consider surgery first and then ART, whereas ART procedures should start directly in women

between 37 and 43 years. Moreover, the indication for laparoscopic tubal reconstructive surgery is inversely proportional to the extent and severity of the tubal damage. In other words, the "typical" patient for surgical laparoscopy will be young, with tubal damage of modest degree and preferably located distally. However, it should be noted that adequate decision-making often calls for diagnostic laparoscopy in view of the inherent limitations of other diagnostic techniques such as hysterosalpingography or transvaginal ultrasound, which do not allow definitive assessment in the majority of cases. Another crucial factor influencing the choice between reconstructive tubal surgery and ART procedures is the logistical and economic factor, since the latter requires the patient to be close to specialized and highly reliable centers, where the costs are usually high.

2.0 Preoperative Assessment

The diagnostic follow-up in couples with infertility problems must be performed within a short time and should be as non-invasive as possible for emotional reasons. They should include a complete clinical history, transvaginal ultrasound with sonohysterosalpingography and diagnostic hysteroscopy with the goal of assessing the uterine cavity accurately.

The possible presence of pelvic inflammatory disease (PID) should be considered; this can lead to tubal infertility in

more than 20% of cases. In all infertile women, cervical and vaginal swabs are advisable to detect the presence of micro-organisms commonly responsible for pelvic inflammatory disease such as *Chlamydia trachomatis*, *Neisseria gonorrhoeae* and *Mycoplasma hominis*.

Diagnostic laparoscopy should be performed in all patients with a high probability of pelvic or tubal pathology.

3.0 Patient Positioning

The classical position for gynecologic laparoscopy is lithotomy with uterine manipulator, including the option to change to the Trendelenburg position if required by the

surgeon. Two accessory 6-mm trocar ports are usually required, one in each lower abdominal quadrant.

4.0 Instrumentation

- 5-mm or 10-mm laparoscope and video camera
- Laparoin insufflator
- Electrosurgical unit
- Xenon light source
- 6-mm or 11-mm trocars
- Veress needle
- 5-mm atraumatic grasping forceps
- 5-mm scissors
- Suction/irrigation system for irrigation and hydrodissection
- Bipolar forceps
- Laparoscopic suturing instruments
- Uterine manipulator

5.0 Diagnostic Laparoscopy

Laparoscopy allows direct inspection of the pelvis and abdominal organs and assessment of tubal function by means of chromopertubation. When the umbilical primary trocar and the accessory ports are in place, the pelvis is inspected systematically. If the patient is in Trendelenburg position, the intestine can be pushed in cephalic direction, distant from the pelvis. The pelvic organs are assessed first: the uterus, tubes and ovaries on both sides. If necessary, a fluid sample is taken from the pouch of Douglas for microbiological culture. Particular attention must be paid to looking

for typical and atypical endometriotic implants, inspecting the peritoneal surface quadrant by quadrant and also using the laparoscopic contact view. In the case of pelvic and adnexal adhesions, these must be determined accurately and graded according to their extent. In the presence of periadnexal adhesions only, these should be treated by salpingo-ovariolysis during diagnostic laparoscopy (**Tab. 1**). This simple treatment results in an intrauterine pregnancy rate between 51% and 62% and an extrauterine rate between 5% and 8%.

Classification of Anexal Adhesions according to the American Society for Reproductive Medicine				
Adhesion		< 1/3 occlusion	1/3–2/3 occlusion	> 2/3 occlusion
Ovary	R Filmy	1	2	4
	Dense	4	8	16
	L Filmy	1	2	4
	Dense	4	8	16
Tube	R Filmy	1	2	4
	Dense	4*	8*	16
	L Filmy	1	2	4
	Dense	4*	8*	16

(*) If the fimbrial end of the fallopian tube is completely occluded, the score is set to 16.

Prognostic classification of adnexal adhesions:

- Minimal 0–5
- Mild 6–10
- Moderate 11–20
- Severe 21–32

Tab. 1

Laparoscopic classification system of adnexal adhesions according to the American Society for Reproductive Medicine (ASRM).

The outer surface of the ovaries must first be assessed; they are then elevated and the ovarian fossa and the rest of the pelvic wall must be assessed, paying special attention to the uterosacral ligaments. The proximal part of the tubes is then examined, looking initially for the presence of adhesions, endometriosis or specific tubal pathology such as nodular isthmic salpingitis. The distal end of the tube must be assessed for tubal function and then phimosis or obstruction

is looked for. The fimbriae in particular must be assessed carefully.

Salpingoscopy can be performed at the same time as laparoscopy and provides a direct endoscopic view of the ampullary part of the tube using a specific rigid optic. This allows the endotubal epithelium to be assessed according to the following classification (**Tab. 2**).

Salpingoscopic Classification of Tubal Lesions				
Score	Mucosal folds	Adhesions	Nuclear staining	Vascular alterations
1	Floating, flexible, trophic	Absent	Absent	Absent
2	Slight flattening	Mild, without intraluminal occlusion	A few isolated nuclei, 25% of the mucosa stained	Morphology altered in 25%
3	Marked flattening, dense, focally absent	Moderate intraluminal occlusion > consistency and extent	> concentration of stained nuclei, occupying between 25%–50% of the mucosa	Vessels altered in 50% or more. Areas of neovascularization
4	Absent	Severe intraluminal occlusion	High concentration of stained nuclei, > 50% of the mucosa affected	Reduced vascularization of tubal wall, neovascularization in all of the tube

Tubal epithelium type A: score ranging from 8 to 10 points. The tubes are normal or show a minor pathologic abnormality.

Tubal epithelium type B: score ranging from 11 to 17 points. The tubes are considered abnormal, usually with combined pathology.

Tubal epithelium type C: score ranging from 18 to 32. The endosalpinx is severely damaged or completely destroyed.

Tab. 2
Salpingoscopic classification of tubal lesions.

After the internal genitalia have been examined, chromopertubation is performed. The instillation of the methylene blue used for the test allows assessment of tubal patency and to check for the presence of tubal phimosis or fimbrial adhesions (**Figs. 1–7**).

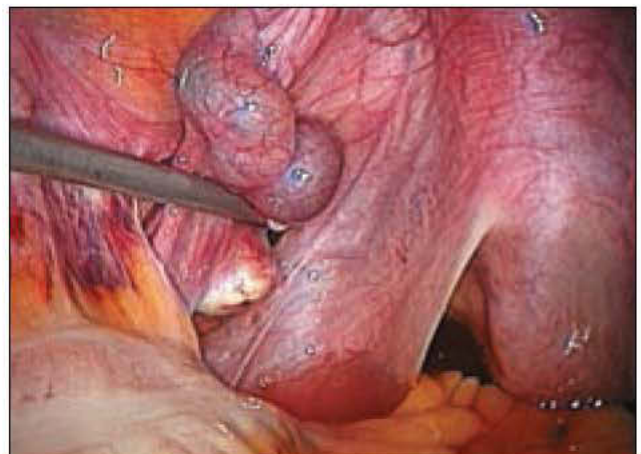


Fig. 1
Tubal and peri-uterine adhesions.

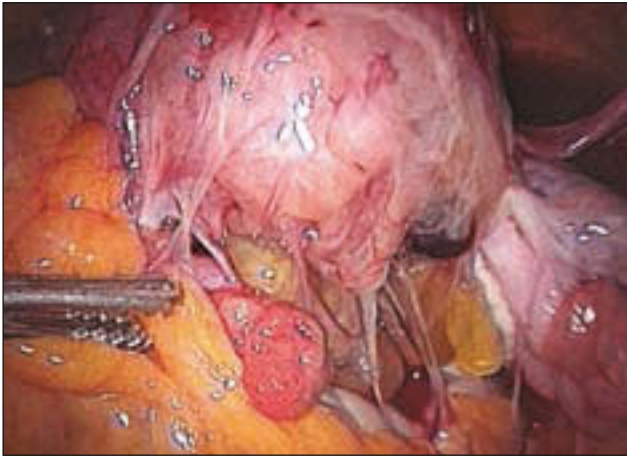


Fig. 2
Dense pelvic adhesions.

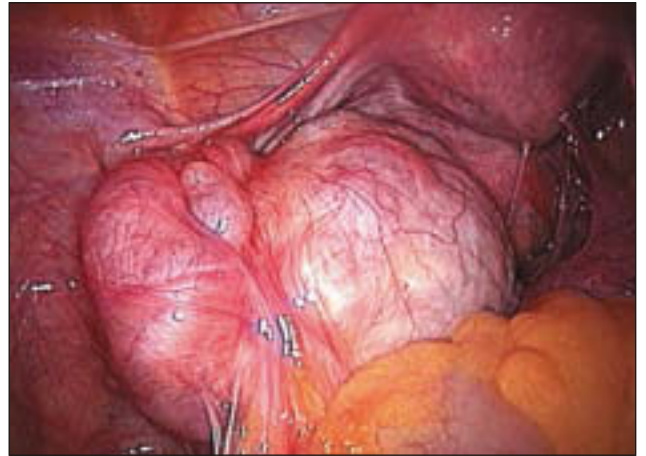


Fig. 3
Hydrosalpinx and ovarian cyst.

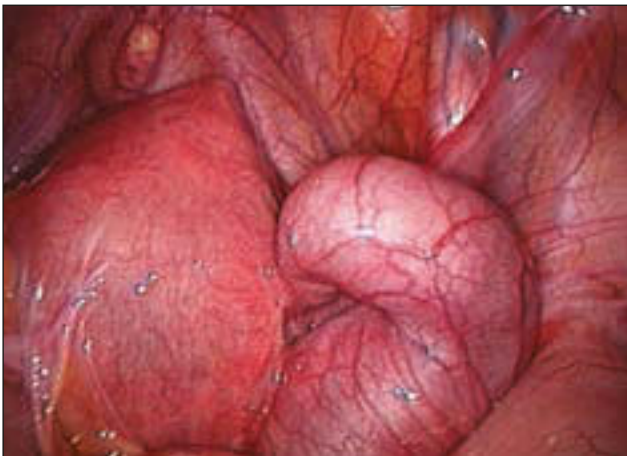


Fig. 4
Large hydrosalpinx.

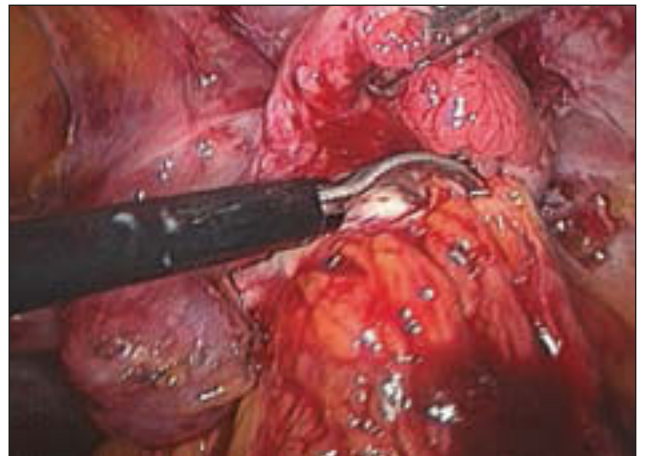


Fig. 5
Lysis of uterine adhesions can cause bleeding.

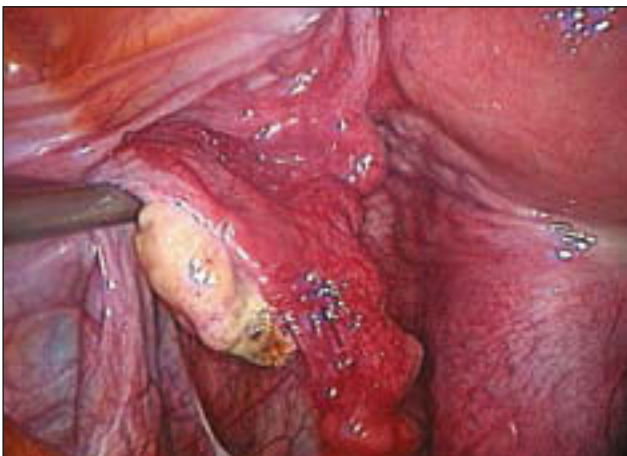

Fig. 6
Preparation for chromopertubation.

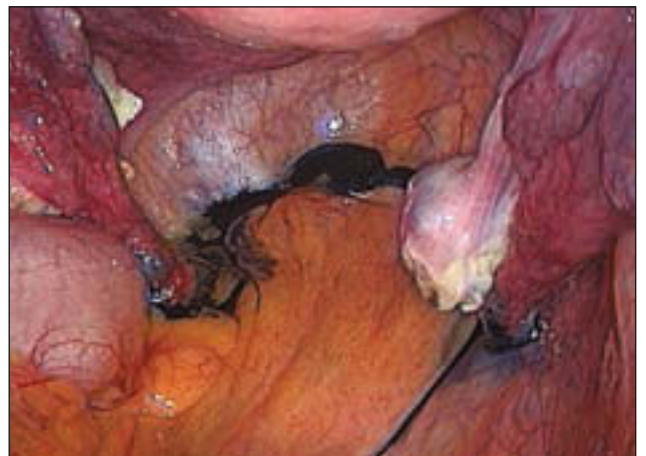

Fig. 7
Chromopertubation.

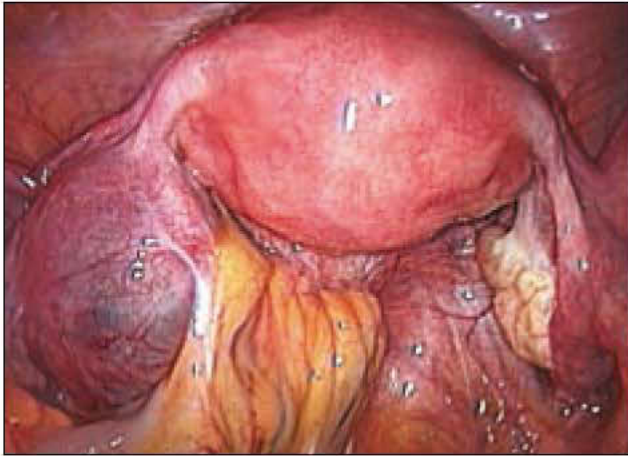


Fig. 8
Large tubo-ovarian abscess.

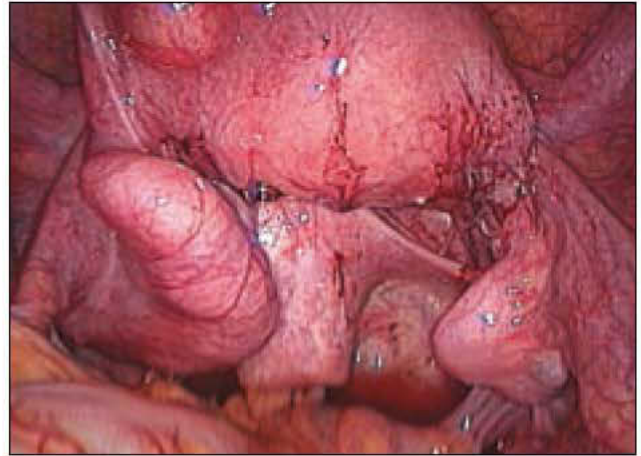


Fig. 9
Tubal abscess.

6.0 Laparoscopic Surgery for PID and Tubo-ovarian Abscess

One of the main causes of tubal damage is pelvic inflammatory disease (PID). The main objective in the management of PID is eradication of etiologic organisms, which in the majority of cases are *Chlamydia trachomatis* or *Neisseria gonorrhoeae*. It is necessary to make a correct diagnosis with culture of the peritoneal fluid and an antibiogram. Treatment frequently requires a combination of several antibiotics. The technique that allows definitive diagnosis is laparoscopy (Figs. 8–9).

The laparoscopic criteria for the diagnosis of PID are listed in the following table (Tab. 3).

In cases of tubo-ovarian abscess, some authors prefer the open laparoscopic technique regardless of the size of the abscess. In a first step, blunt removal of all adhesions by traction and stretching must be performed. Lysis with scissors or electrocautery should be conducted with great care to avoid possible intestinal perforation taking into account that

the intestinal mucosa is particularly edematous and fragile in these cases. Peri-hepatic adhesions (Fitz-Hugh-Curtis syndrome) are correlated with pelvic infection with *Chlamydia trachomatis* and do not need to be removed surgically if they are asymptomatic (Figs. 10–11).

Laparoscopic classification of PID

Mild	Erythema, edema, the tubes are mobile. Absence of purulent discharge.
Moderate	Erythema, edema more marked; mucopurulent discharge; tubes are fixed; fimbriae may not be visible.
Severe	Presence of pyosalpinx and/or abscess.

Tab. 3

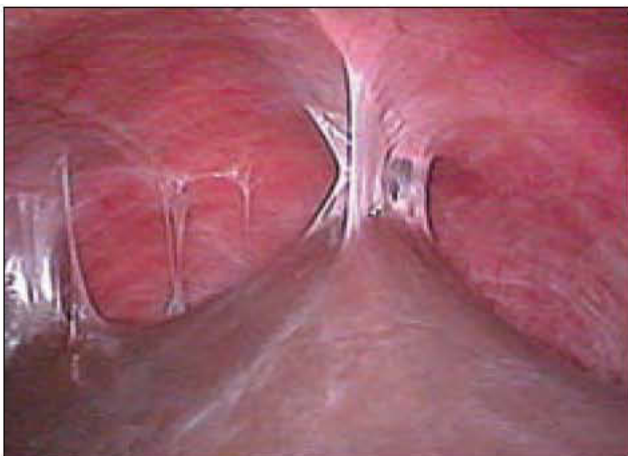


Fig. 10
Adhesions of the Fitz-Hugh-Curtis syndrome are usually subclinical or asymptomatic and do not require surgical lysis.

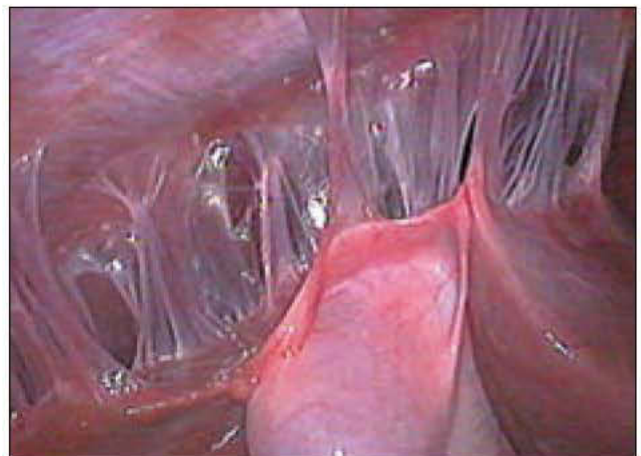


Fig. 11
In some cases, adhesions of the Fitz-Hugh-Curtis syndrome can be symptomatic.

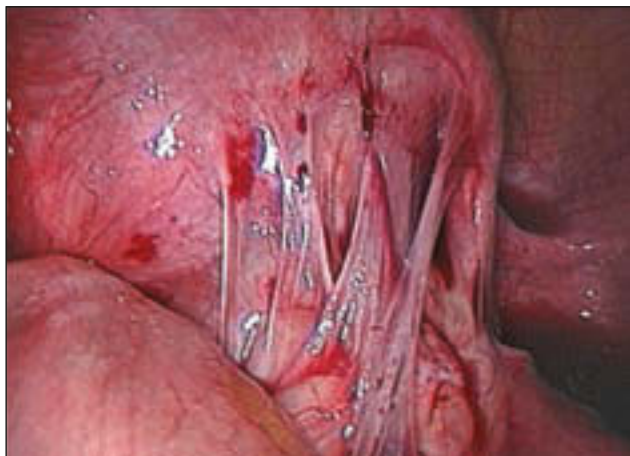

Fig. 12
Periovarian adhesions.

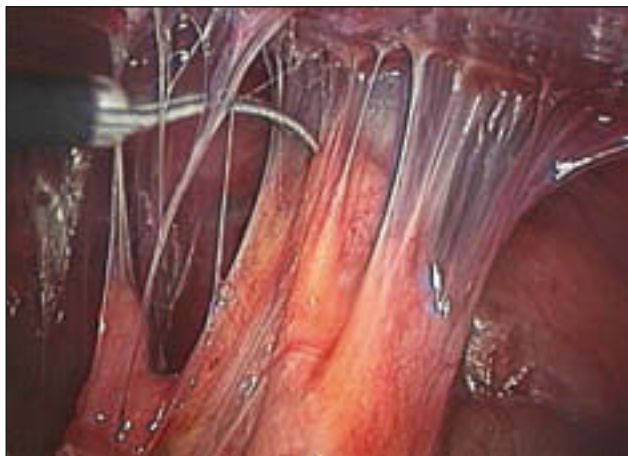


Fig. 13
Adhesiolysis by use of scissors.

Following complete lysis of adhesions, the tubo-ovarian abscess must be aspirated and drained (**Figs. 12–13**). Aspiration is performed with a laparoscopic suction tube or by introducing a 5–10 mm trocar through the abdominal wall, perforating the wall of the abscess and aspirating it through the trocar. Once the purulent liquid has been completely evacuated, copious lavage is performed with Ringer lactate

through the trocar cannula which is left in place until the aspirated liquid is completely clear. Assessment of the tube will permit a decision on whether or not removal is indicated. At the end of the procedure, it is important to introduce a drain (e.g., Jackson-Pratt) into the pelvis. The drain should be removed 24 to 48 h after the operation.

7.0 Reconstructive Laparoscopic Tubal Surgery

The fallopian tubes can be occluded proximally or distally, i.e., at the fimbrial ends. The condition can coexist with peri-adnexal adhesions. Tubal blockage can also be correlated with an inflammatory process or a medical history of surgical interruption. Reconstructive surgery is feasible only in cases of a minor, circumscribed damage, and if possible, not bilateral. Some pathological findings, such as

salpingitis isthmica nodosa and/or genital tuberculosis, which by definition is associated with severe tubal damage, rule out the option of reconstructive laparoscopic surgery, mainly because they are considered to have a poor prognosis regarding the predictable degree of functional recovery (**Figs. 14–15**).

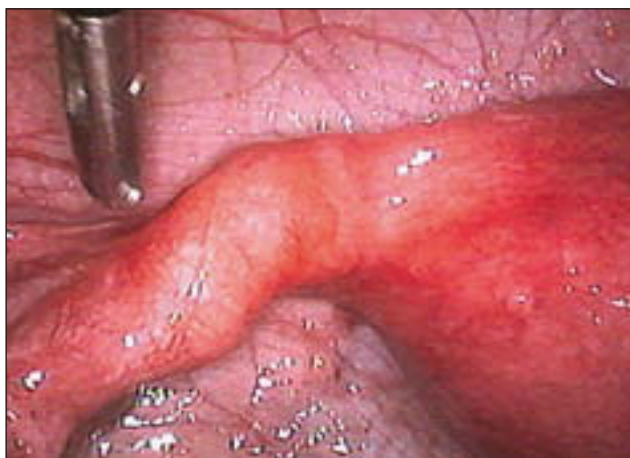

Fig. 14
Salpingitis isthmica nodosa.

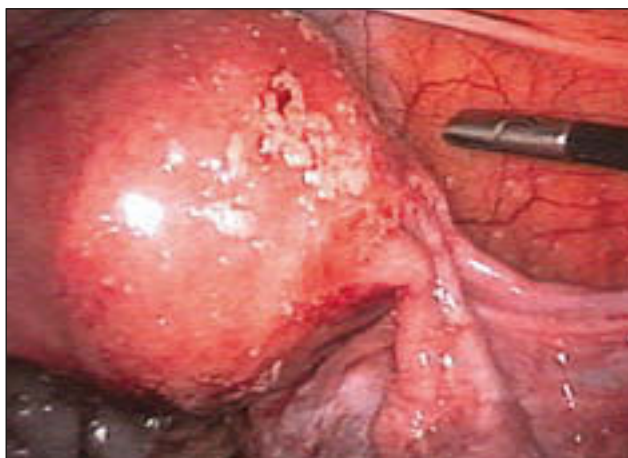


Fig. 15
Uterine tuberculosis.

7.1 Fimbrioplasty

Fimbrial phimosis (agglutination of the fimbriae) often coexists with peri-adnexal adhesions and is repaired by laparoscopy. The intrauterine pregnancy rate after laparoscopic fimbrioplasty varies between 40% and 48% depending on its severity and extent, with an extrauterine pregnancy rate ranging between 5% and 6%. In cases where the mucosal folds are densely adherent or in the presence of ampullary mucosal adhesions, the prognosis is very poor.

The principle of fimbrioplasty is anatomical and functional repair of the infundibulum. To visualize the phimotic region, it is often necessary to perform perioperative chromopertubation to distend the tube. Surgical repair can be achieved with a fine atraumatic grasping forceps, introducing the closed tip into the area of phimosis extremely careful and

gradually opening the jaws. The maneuver must be repeated several times, changing the direction in which the forceps is opened. Manipulation of the tissues must be very gentle to avoid bleeding (**Figs. 16–22**).

Rarely, even though the fimbrial ends appear normal, proximal stenosis can be found at the abdominal opening of the tube (prefimbrial phimosis). This stenosis can be diagnosed by chromopertubation only. The surgical management involves dissecting along the antimesenteric border of the tube from the fimbriae as far as the distal ampulla, traversing the area of stenosis. Dissection is performed by use of electrocautery. As a final step, the site of repair is sutured with a very fine suture (6/0).

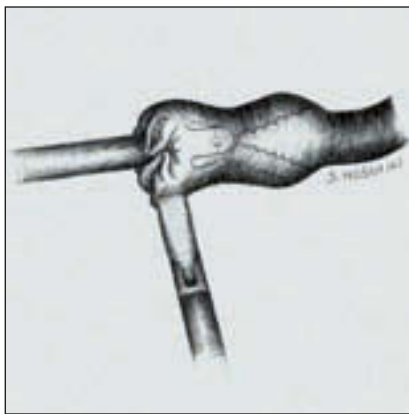


Fig. 16
Introduction of forceps into the phimotic ostium of the tube.

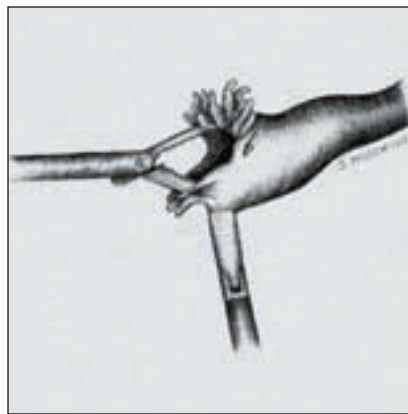


Fig. 17
Opening the jaws of the forceps.

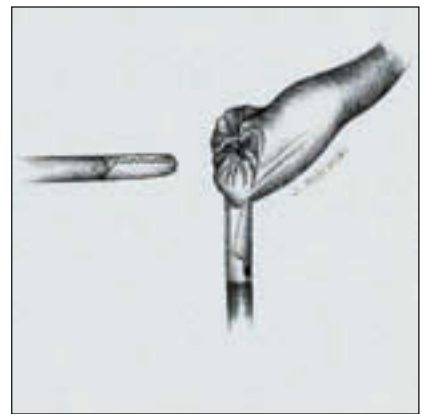


Fig. 18
Normal appearance of the abdominal tubal ostium at the end of the procedure.

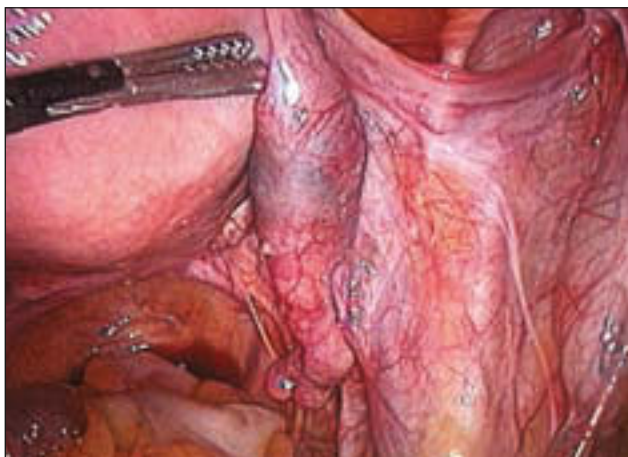


Fig. 19
Hydrosalpinx with fimbrial phimosis.

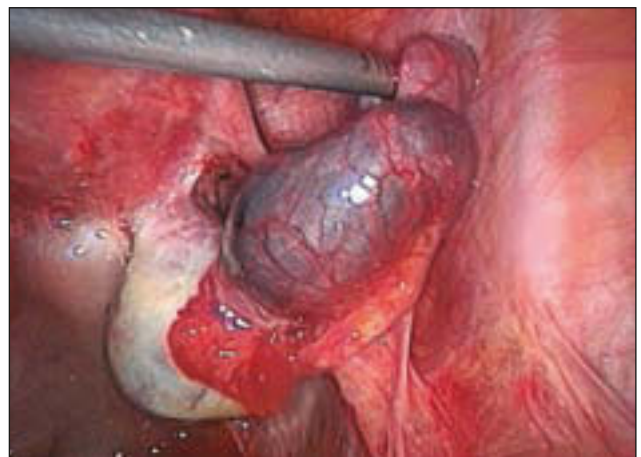


Fig. 20
Methylene blue injection for perioperative chromopertubation.

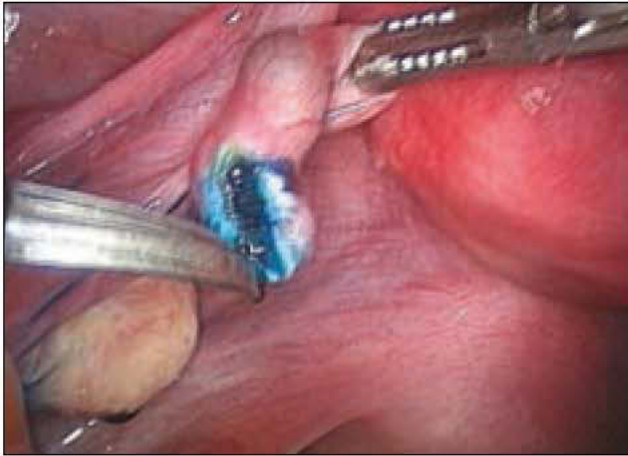

Fig. 21
Introduction of the instrument, opening of the jaws.

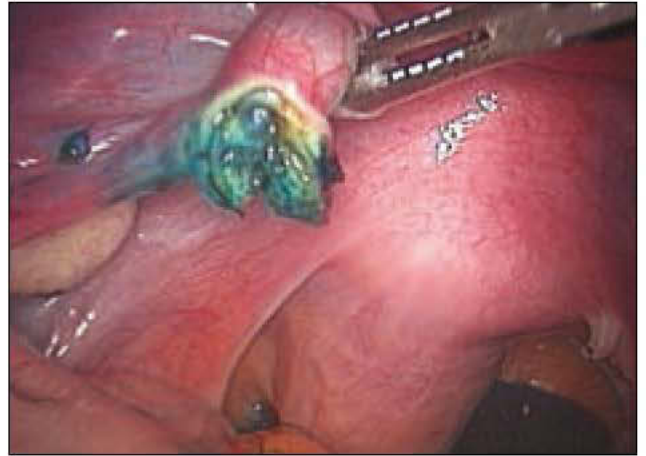

Fig. 22
Neosalpingostomy.

7.2 Salpingostomy (Salpingoneostomy)

Hydrosalpinx can be treated by laparoscopic salpingostomy. The main factors contributing to the outcome of salpingostomy are the diameter of the distal tubal portion, the thickness of the wall, the condition of the tubal epithelium and the type and extent of adhesions. In cases with a favorable prognosis, pregnancy rates vary between 40% and 60% and fall to 20% in less favorable cases. The decision-making regarding the appropriate surgical approach must be based on laparoscopic examination of the tubes and pelvis, preferably including salpingoscopy (Tabs. 4, 5).

Tab. 4 ▶
Classification according to Mage modified by the intraoperative assessment of tubal occlusion.

Parameter	Extent of tubal damage	Score
Patency	Normal	0
	Phimosi	5
	Hydrosalpinx	10
Wall	Normal	0
	Thin	5
	Fibrous	10
Mucosa	Normal	0
	Reduced folds	5
	Absence of folds	10

Classification of tubal occlusion by intraoperative assessment

Grade	Tubal occlusion	Score
1	Mild	0 a 5
2	Moderate	10 a 15
3	Severe	20 a 30

Classification of distal tubal occlusion (American Fertility Society)			
Distal ampullary diameter	< 3 cm	3–5 cm	> 5 cm
	1	4	6
	1	4	6
Thickness of tubal wall	Normal thickness	Moderate or edematous	Increased and rigid
	1	4	6
	1	4	6
Mucosal folds	Normal / > 75% preserved	35–75% preserved	< 35% preserved (adhesions in the mucosal folds)
	1	4	6
	1	4	6
Adhesions	None/minimal/mild	Moderate	Extensive
	1	3	6
	1	3	6
Type of adhesions	None/ filmy	Moderately dense (or vascular)	Dense
	1	2	4
	1	2	4

Tab. 5

The management of hydrosalpinx is based essentially on the quality of the tubal mucosa:

- For thin-walled hydrosalpinx with normal mucosa and without mucosal adhesions, salpingostomy via the laparoscopic approach is indicated. The majority of pregnancies occur within the first year post-operatively.
- For thin-walled hydrosalpinx with focal adhesions, either reconstructive surgery or ART procedures are indicated. Reconstructive surgery in these cases is associated with an increase in the risk of extrauterine pregnancy.
- For thin-walled hydrosalpinx with extensive mucosal adhesions (> 50% of the mucosal folds), ART procedures only are indicated, more specifically in vitro fertilization. Many authors, including ourselves, regard it as appropriate in these cases to perform laparoscopic salpingectomy because this has been found to considerably improve the outcomes of ART.

In the presence of adnexal adhesions, diagnostic laparoscopy is followed by adhesiolysis with gentle maneuvers using closed atraumatic forceps in the case of filmy and avascular adhesions; if they are dense and vascular, it is advisable to use bipolar coagulation and scissors. The tubo-ovarian ligaments must be exposed to confirm patency of the fimbriated tubal portion. If the tube is fixed to the ovary, the two structures must be separated.

Once adnexal adhesiolysis has been completed, the tube should be distended by transcervical instillation of methylene blue dye using the uterine manipulator. In the area of occlusion, scar tissue can frequently be found. The target site of the cross- or star-shaped neo-ostium should be located at the thinnest and most avascular area possible, which usually corresponds to the original site of the ostium. The cruciate incision at this level is made using scissors, electrosurgery or by laser application with the aim of creating eversion of the mucosa of the distal tubal portion. Closed atraumatic grasping forceps can be introduced in the opening to gently incise the margins of the neo-ostium. To make the margins evert properly, fine bipolar forceps may be used at low current setting; this is performed by touching the serosa at the base of the margins previously created to induce shrinking and simultaneous eversion. If the tubal wall is thick, sero-serous sutures can be placed alternatively with atraumatic sutures (Vicryl 5–7/0).

In conclusion, the surgical procedure to create a neo-ostium involves two steps, incision and eversion:

- To create the neo-ostium, two to four 1–2 cm incisions are made parallel to the longitudinal mucosal folds, in an avascular area.
- Eversion is obtained with various techniques, such as bipolar coagulation of the serosa or placement of a few sutures.

7.3 Tubo-tubal Anastomosis

True pathological occlusion of the proximal tube necessitates a microsurgical procedure with tubo-cornual re-anastomosis, which can be performed laparoscopically. Laparoscopic techniques of tubal anastomosis have recently been described in patients who had a previous history of tubal sterilization. The image magnification properties of video-endoscopy and the unique angles of vision offered by modern laparoscopes, together with the option of bringing the video image close to the operating field, provides advantages superior to traditional microsurgery.

The major application of laparoscopic microsurgery is tubo-tubal anastomosis regardless of its site and regardless of whether it is done because of the presence of occlusion or to reverse previous tubal sterilization. The surgical technique of tubo-tubal anastomosis does not vary from the laparotomy approach with a traditional microscope. In the case of adhesions, salpingo-ovariolysis is first performed. This is followed by infiltration of the mesosalpinx in the area chosen for the anastomosis with 1 or 2 ml of a solution of vasopressin to reduce bleeding and facilitate accurate hemostasis.

The proximal end of the tube is distended by means of transcervical injection of methylene blue, which facilitates localization of the occluded segment of the proximal tube. At this point, a cut is made at the level of the occlusion using laparoscopic scissors. It is very important to avoid damage to mesosalineal vessels. The tubal segment is separated from the mesosalpinx by electrosurgery. Hemostasis of the tubal segment of tube is accomplished by electrocoagulation (microelectrode) of the most important bleeding points.

Continuous irrigation allows even small bleeding points to be visualized rapidly. The distal tubal segment is prepared in a similar way so that there is no difference or asymmetry between the two stumps to be anastomosed. In this case, too, transcervical instillation of methylene blue can be used to facilitate delineating the margins. The two stumps are then approximated and sutured in two layers. The first layer joins the endotubal epithelium and muscle and the second joins the serosa. The distal suture must be placed at the antimesenteric border, and can be placed perfectly on the other stump also.

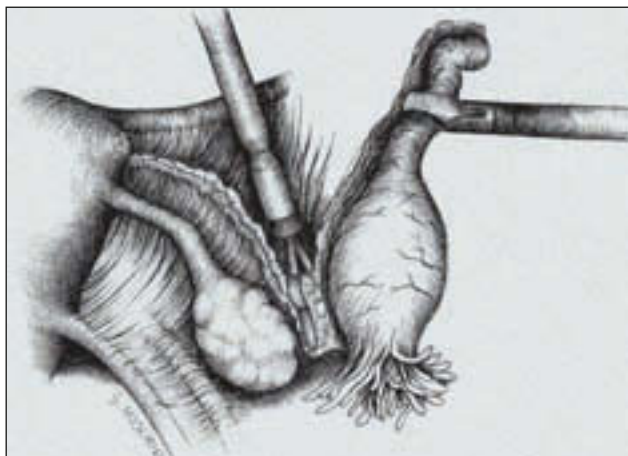
Recommended Reading

1. DURRUTY G, VERA C, MACAYA R, BIANCHI M, MANZUR A: Resultados de la salpingoneostomía laparoscópica en infertilidad por hidrosalpinx. Departamento de Obstetricia y Ginecología, Unidad de Reproducción Humana, Hospital Clínico Pontificio. Universidad Católica de Chile. Revista chilena de obstetricia y ginecología. Santiago (Chile). 2002. 67(6): 488–493
2. GOMEL V: Reproductive surgery. Department of Obstetrics and Gynecology. Faculty of Medicine. University of British Columbia. Vancouver (Canada). 2005. Minerva. 57:21–8
3. GOMEL V, ZOUVES CG: Laparoscopia quirúrgica en las enfermedades de las trompas. Cirugía Laparoscópica en Ginecología. Soderstrom. Segunda edición Marban. (Philadelphia) 1999. (1):87–95.
4. GORDON A G: Tubal Endoscopy. Consultant Gynaecologist, BUPA Hospital Hull and East Riding, Lowfield Road, Anlaby, Hull HU10 7AZ. 2004
5. HULKA and REICH: Textbook of laparoscopy. (USA). 2002. (1): 285–300
6. MARCONI G, VILELA M, GOMEZ RUEDA N, BUZZI J, DE ZUNIGA I, QUINTANA R: Salpingoscopia. Cuadernos de medicina reproductiva. Pellicer Antonio. Primera edición. Madrid (España). 2002. 8 (1): 213–237
7. YOUNG E, VAN TRILLO: Hidrosalpinx e Infertilidad. Cuadernos de medicina reproductiva. Pellicer Antonio. Primera edición. (Madrid) 2002. 8 (1): 89–100

Chapter IX

Laparoscopic Management of Ectopic Pregnancy

Cristiana Barbosa and Luca Mencaglia
Centro Oncologico Fiorentino, Florence, Italy



1.0 Introduction

Implantation of the zygote outside the uterus occurs in approximately 1 in 200 pregnancies and the incidence appears to be increasing. This increase in ectopic pregnancy correlates with the high incidence of sexually transmitted disease, delayed median age of first pregnancy and improved accuracy of diagnosis.

The most common site of ectopic pregnancy is at the ampullary tubal portion where fertilization normally occurs (**Fig. 1**) and then, less frequently, other parts of the tube, the cervix, the ovary and the abdominal cavity.

All variants of extrauterine pregnancy can be treated by a minimally invasive approach in the majority of cases. In the last decade, laparoscopic surgery has become very widespread in both gynecology and general surgery. The main advantages of the minimally invasive approach are reduced postoperative morbidity, less postoperative pain, and accordingly, less analgesic medication, early resumption of intestinal activity, reduced length of hospital stay and a rapid return to normal activity.

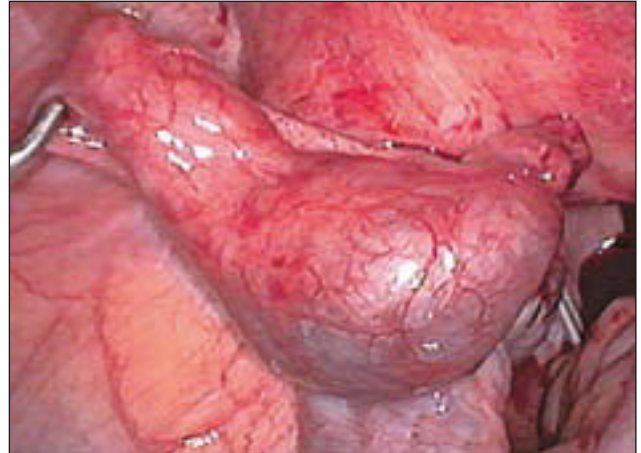


Fig. 1
Ectopic gestation in the ampullary tubal segment.

2.0 Preoperative Assessment

The clinical picture includes nausea, amenorrhea, lower abdominal pain, cramps and abnormal uterine bleeding. Pain in the shoulder raises the suspicion of tubal rupture with hemoperitoneum. Diagnostic preoperative assessment must include the history and bimanual gynecologic examination (which is able to diagnose an adnexal mass in 50% of cases). However, early diagnosis of ectopic pregnancy can be made with the combination of transvaginal ultrasound and measurement of the serum beta-HCG. The sensitivity of beta-HCG allows the diagnosis to be made only 10–15 days after ovulation. The growth curve of this hormone is abnormal in 46% of patients. A delayed increase in beta-HCG

should raise the suspicion of extrauterine pregnancy. The most recent generation of ultrasound allows visualization and localization of the gestational sac before the sixth week in 98% of cases. The presence or absence of a gestational sac on transvaginal ultrasound should be correlated with the pregnancy week and the serum levels of beta-HCG.

Other useful tests in diagnosing ectopic pregnancy are: endometrial thickness (cut off < 8mm), sonohysterography, color Doppler and blood progesterone level (cut off 17.5 ng/ml). Unfortunately, progesterone is not of use in patients who have undergone induction of ovulation.

3.0 Positioning of the Patient

The patient is positioned on the table in the classic gynecologic position. An intrauterine manipulator and Foley bladder catheter can be used.

5 mm- or 10 mm-laparoscope with the primary trocar introduced at the umbilicus. Two accessory 6 mm-ports in the right and left iliac fossa and a 6 mm suprapubic port for the grasping forceps, bipolar forceps and suction cannula.

4.0 Instrumentation

Laparoscope, diameter 5 mm or 10 mm
Videocamera
Microprocessor-controlled insufflation system
Electrosurgical unit
Xenon cold light source
Trocars, diameter 6 mm or 11 mm
Veress needle

Atraumatic grasping forceps
Scissors
Suction and irrigation system
Monopolar hook electrode
Bipolar forceps
Disposable extraction bag
Uterine manipulator

5.0 Surgical Technique

5.1 Evacuation of the Hemoperitoneum

A 5 mm suction cannula is usually sufficient for evacuating the hemoperitoneum. If the tube has ruptured and/or the patient is in shock with a large hemoperitoneum, an 11 mm-trocar may be used to introduce the suction tube.

The surgical management essentially involves partial or total salpingectomy, however, depending on each individual case, preservation of the organ may well be the approach of choice.

5.2 Salpingectomy

Extensive tubal dilatation is not necessarily an absolute contraindication to laparoscopic treatment. Unilateral or bilateral adhesiolysis is often performed in the same setting.

Salpingectomy is the method of choice in women who abandoned the desire for future pregnancies or in the case of tubal rupture. Other indications for salpingectomy are extrauterine pregnancy following failed sterilization, in a blocked tube, in a previously reconstructed tube, in a woman

requesting sterilization, in the case of persistent bleeding after salpingotomy, when the beta HCG > 100,000 mU/ml, in the case of recurrent tubal pregnancy and in the case of tubal pregnancy > 5 cm.

Following evacuation of the hemoperitoneum, the bipolar forceps and scissors are introduced into the abdominal cavity to coagulate and dissect the tube and mesosalpinx (**Figs. 2, 3**).

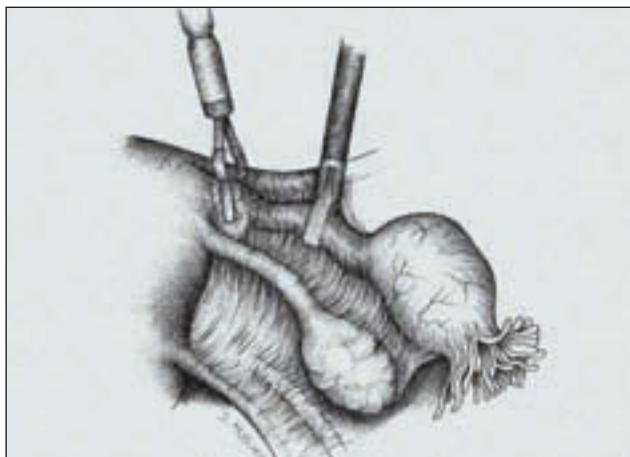


Fig. 2
Electrocoagulation of the tube and mesosalpinx.

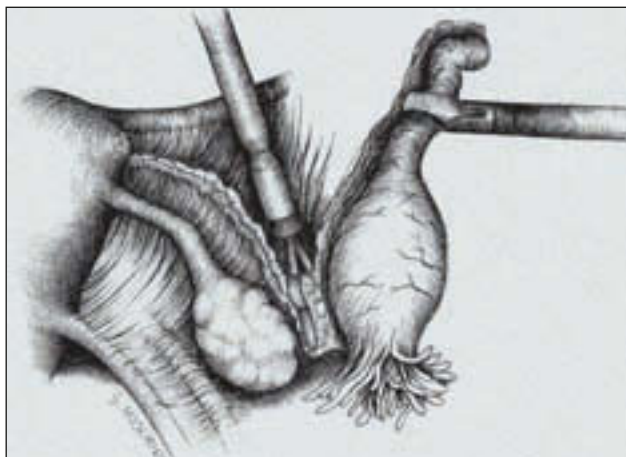


Fig. 3
Electrosurgical dissection of the mesosalpinx.

The tube containing the gestational sac is then removed from the peritoneal cavity through the 11 mm-umbilical port with the aid of forceps located in the suprapubic port. However, it is preferable to use an endobag for removing the tube and product of conception (**Fig. 10**). After reinsertion of

the laparoscope, final inspection of the abdominal cavity is recommended because in some cases, while grasping the tube for removal, the product of conception may slip out unnoticed which requires either aspiration with a suction tube or extraction by use of forceps.

5.3 Salpingotomy

Preservation of the tube should be attempted in all patients who wish to maintain fertility if they have a stable hemodynamic status and there is no evidence of tubal rupture.

After draining the hemoperitoneum, the adnexa is mobilized with the suction/irrigation tube or by dissection in the presence of adhesions.

Indications for linear salpingotomy:

- desire to preserve fertility
- hemodynamical stability
- size of ectopic pregnancy less than 5 cm
- gestational sac located in the ampulla, infundibulum or isthmic portion
- absence of pathology of the contralateral tube

Vasopressin: the mesosalpinx can be infiltrated with vasopressin 20 IU diluted in 50 ml of normal saline. A syringe with 22 gauge needle can be used for injection through one of the accessory ports. Alternatively, the outer sheath of a Veress needle can be used directly through the abdominal wall at pubic level, lateral to the deep inferior epigastric vessels, introducing a spinal needle (22 gauge) inside it. Great attention is required when starting infiltration of the mesosalpinx because of the risk of iatrogenic laceration of blood vessels. The serosa should be grasped gently prior to injecting 10–20 ml of solution, which will cause visible swelling of the mesosalpinx. The effect can last for about 2 hours, permitting physiological hemostasis.

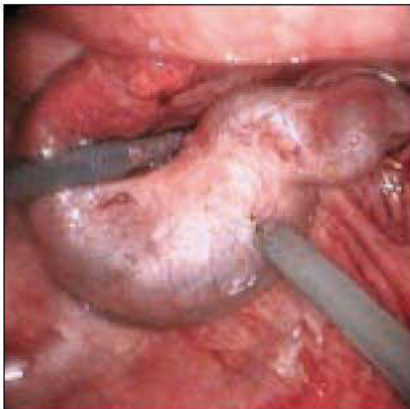


Fig. 4
Ectopic tubal pregnancy.

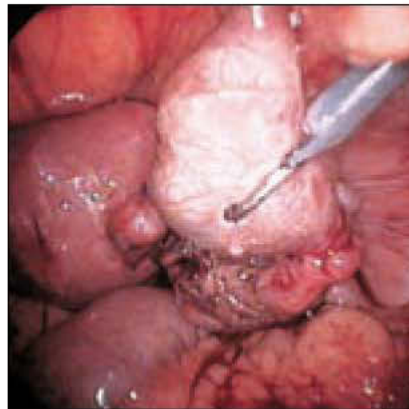


Fig. 5
Longitudinal incision along the area of maximum distension of the tubal pregnancy.

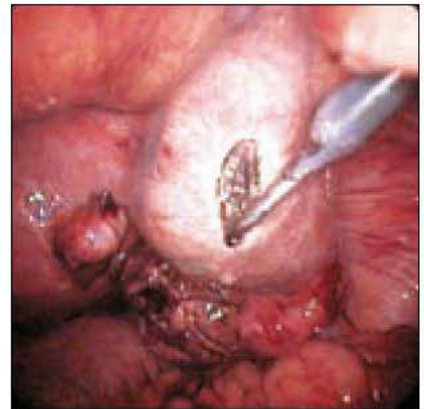


Fig. 6
Longitudinal dissection with an unipolar electrode.

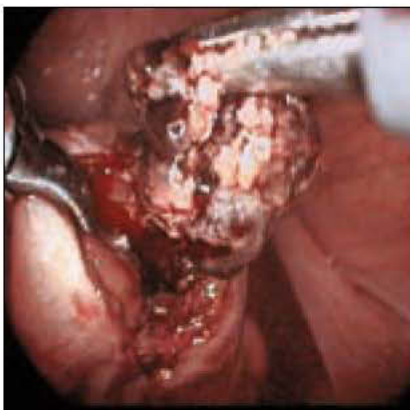

Fig. 7
The intratubal pregnancy is removed with forceps.

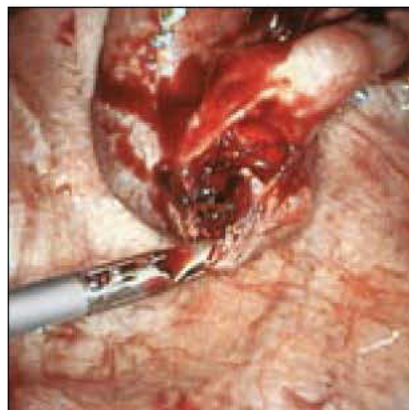


Fig. 8
Coagulation of the incision margins.

Because of its high metabolic rate, the trophoblast requires oxygen and the cells cannot withstand anoxia. It is most probable that vasopressin, by reducing the oxygen supply for about an hour, has fatal consequences for the trophoblast that has inadvertently left behind, reducing by a factor of five the 15% risk of persistence of ectopic pregnancy in the case of conservative salpingotomy. Use of vasopressin is contraindicated in patients with ischemic heart disease.

Incision and evacuation: with an unipolar knife electrode introduced through the 6 mm port, a 1–2 cm incision is made in the antimesenteric tubal wall at the site of maximum distension, using a cutting or blended current (20 or 70 W). In general, it is possible to identify the different layers of the tubal wall: serosa, muscularis externa and mucosa.

If the product of conception cannot be localized when the serosa is incised at the point of maximum dilation, it will be necessary to incise the still intact muscularis externa and mucosa to advance to the lumen of the tube. Once the ectopic pregnancy, which is usually of very friable consistency, has been identified, it can be evacuated by aspiration. If a mass surrounded by clot is encountered, the product of conception must be delivered through the tubal incision with the aid of pressurized irrigation or with grasping or biopsy forceps (**Figs. 4–10**).

The site of implantation and the tubal incision are then irrigated, making sure that the liquid introduced through the salpingotomy incision drains from the fimbrial end and vice versa.

Transcervical instillation of methylene blue will allow demonstration of tubal patency.

It should be borne in mind that when the ectopic pregnancy is located in the extraluminal space, it is possible that the tubal surface exhibits dilation without intraluminal involvement. It

is often easier to make a small incision for evacuation of a distinct, large-sized intraluminal ectopic pregnancy of friable consistency, compared to one of small size and poorly visible in the thickness of the tubal wall. The preferred route for removing the product of conception with or without the tube is through the 11-mm umbilical port. Alternatively, it can be reduced piecemeal by use of a biopsy forceps or suction cannula. In a few cases, it is advisable to use an extraction bag for removing the product of conception.

The salpingotomy incision usually does not require suturing. Seromuscular suturing will be necessary only if the incision is very large or in the case of mucosal eversion.

Hemostasis: if there is bleeding from the incision margins or site of implantation, hemostatic tamponade can be applied with grasping forceps prior to electrocoagulation, laser application or placing a suture. Often, 5 minutes of compression are sufficient for hemostasis. Even elevating the adnexa out of the pelvis can produce the same result as by compressing the vessels of the mesosalpinx.

Arterial bleeding can be present after removal of blood clot. In this case, the best hemostatic effect can be achieved by selective and targeted use of bipolar coagulation forceps, particularly if combined with continuous irrigation. Diffuse venous bleeding, especially from the site of implantation in the muscle layer in the case of extraluminal location, can be controlled readily with electrocoagulation. The superficial eschar in the extraluminal space does not interfere with normal healing of the tubal epithelium.

Following removal of an ampullary pregnancy, uncontrollable bleeding can occur. In such cases, an endoloop may be used, which is removed after 5–10 minutes; this makes it possible to localize and coagulate the source of bleeding. In severe cases, the mesosalpingeal vessels can be ligated selectively.

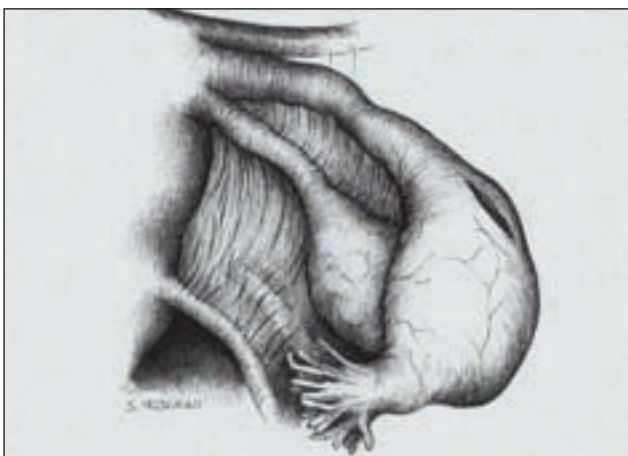


Fig. 9
Linear incision.

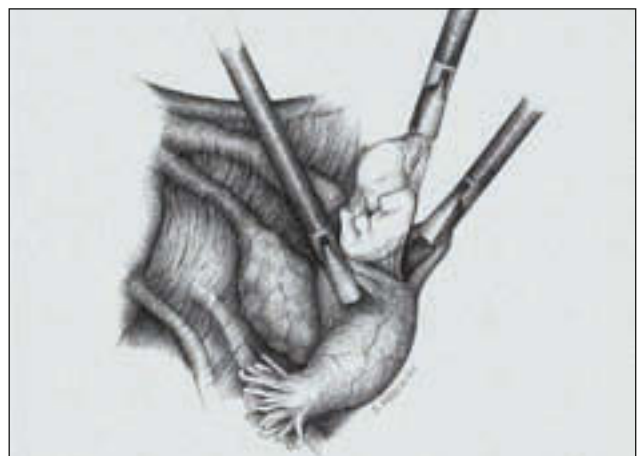


Fig. 10
Removal of the product of conception.

5.4 Partial Salpingectomy

Partial laparoscopic salpingectomy can be attempted to preserve the tube in the case of failed salpingotomy, tubal rupture, isthmic pregnancy, distal interstitial pregnancy or recurrent tubal pregnancy.

The procedure involves coagulation with bipolar forceps followed by division of both ends of the distended part of

the tube and corresponding mesosalpinx with subsequent removal of the tubal segment through the umbilical port. Alternatively, to avoid thermal (but not ischemic) injury, two endoloops, and if required, bipolar coagulation can be applied to complete hemostasis.

5.5 Extirpation of Tubal Pregnancy through the Fimbrial End

Extirpation of the tubal pregnancy through the fimbrial end, tubal aspiration or tubal abortion without salpingotomy are procedures that involve removal of the product of conception located at the fimbrial end or distal tubal segment. This is accomplished by aspiration or use of grasping forceps operating from inside or outside, gently pushing the product of conception until it is extruded. In certain cases tubal abortion has already occurred.

Since many ectopic pregnancies have actually not implanted in the intraluminal tubal portion, this type of procedure is often associated with incomplete removal of the trophoblast and damage to the tubal wall. For this reason, even though some

authors have reported excellent results when the pregnancy is located in the fimbrial portion, these techniques are not commonly recommended, neither by way of laparoscopy nor by laparotomy.

The technique may be applied in selected cases of intraluminal ectopic pregnancy not yet visible (invasion of the muscularis and serosa has not yet occurred) by introducing the suction tip into the tube from the distal ostium and instillation of liquid, that acts mechanically to dislodge and expel the product of conception into the peritoneal cavity eliminating the need for making an incision in the tubal wall.

5.6 Extraluminal Ectopic Pregnancy

This occurs when the ectopic gestation while growing rapidly infiltrates the tubal wall until occupying the space between the muscularis externa and serosa. In the majority of cases, as soon as the serosa is incised at the point of maximum distension, the gestational sac slips out without the need to enlarge the opening. Irrigation in this case will not produce a flow of liquid from the distal part of the tube. Rarely, the surgeon will be faced with the dilemma of having to enter the tubal lumen which should be avoided as much as possible.

Occasionally, it is possible to infiltrate 360° of the space between serosa and muscularis. In this case, after removing the trophoblast and achieving hemostasis with the aid of compression or electrocoagulation, the surgeon can conclude the operation and follow the patient carefully with serial beta HCG measurements. Methotrexate can be considered as possible adjuvant treatment.

5.7 Interstitial or Cornual Ectopic Pregnancy

Interstitial ectopic pregnancy can be treated laparoscopically by electrosurgical resection of the uterine cornu. This procedure will allow the greater part of the tube to be preserved on the one hand, but on the other hand, the complete destruction of the interstitial part will make it highly probable that any anastomosis will fail. Coagulation of the ascending branch of the uterine artery and utero-ovarian arteries can be necessary to achieve good hemostasis. Use of vasopressin is not considered in this case.

In both laparotomy and laparoscopy, the approach is piecemeal resection of the uterine cornu using cutting or blend current (**Figs. 10–14**). The technique is very similar to myoma removal. Hemostasis must be obtained with bipolar coagulation and hydrodissection of the tissue planes using pressurized normal saline.

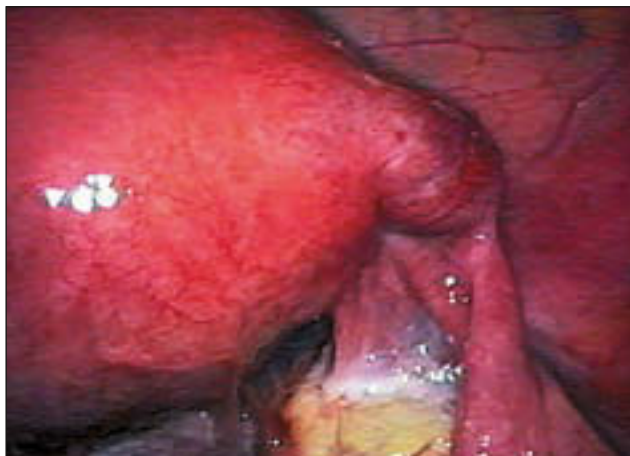

Fig. 11
Laparoscopic view of cornual pregnancy.

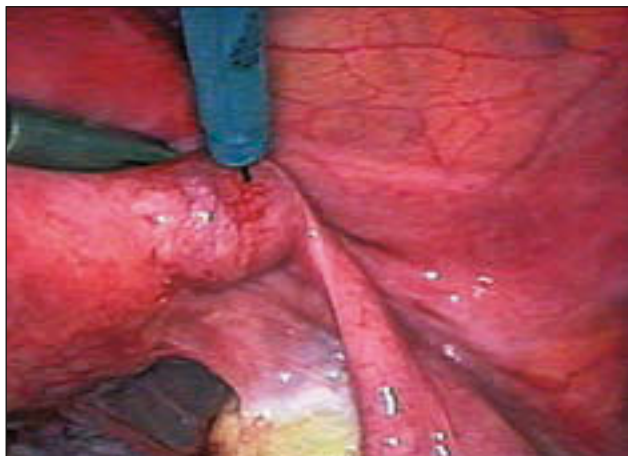


Fig. 12
The cornual pregnancy is incised with a unipolar needle electrode.

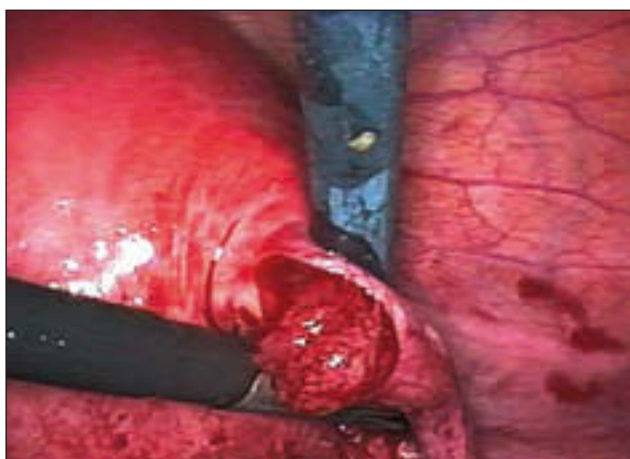


Fig. 13
Expressing a cornual pregnancy with two forceps.

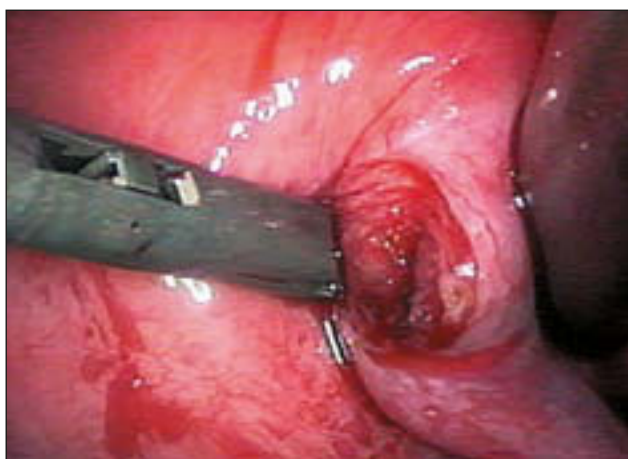


Fig. 14
Appearance after removal of the cornual pregnancy.

Rupture of a tubal pregnancy has always been considered a contraindication to the laparoscopic approach even though removal of a ruptured tube can be accomplished easily with bipolar coagulation. There is controversy about the management of patients with hemodynamic instability. In this case, hemorrhage must be arrested at once and the tube removed as quickly as possible. The majority of surgeons prefer to manage the situation by emergency laparotomy.

The laparoscopic bipolar forceps is capable of coagulating even large uterine or ovarian vessels. Alternatively, ligature with an endoloop may be employed. After achieving hemostasis, the tube or part of it is removed. Rupture of an interstitial pregnancy may also be treated with simple coagulation of the uterine and ovarian vessels but this approach is associated with a higher risk of persistent and recurrent ectopic pregnancy.

5.8 Ectopic Ovarian Pregnancy

Ectopic ovarian pregnancy, when diagnosed, must be treated like any ovarian cyst of unknown origin and must therefore be enucleated intact through a small incision in the ovarian cortex. Ovarian function usually remains unchanged. An ovarian pregnancy should be suspected when the serum levels of beta HCG exceed 6000 mU/ml, ultrasound shows an empty endometrial cavity and tubal pregnancy is not found

on laparoscopy. With monopolar forceps, the ovarian surface is incised along its major axis at the point where the neoformation appears most superficial. The trophoblastic material can then be dissected and removed, using a suction/irrigation system. The gestational sac is usually removed as a whole and suturing of the ovarian parenchyma is not necessary.

5.9 Ectopic Abdominal Pregnancy

Ectopic abdominal pregnancy is a rare event and accounts for 1.1% of all ectopic pregnancies. Since it is a condition with high maternal and fetal morbidity and mortality, early diagnosis using transvaginal ultrasound, magnetic resonance imaging and laparoscopy is essential. It is a condition that

can be treated readily by laparoscopy if this is done early and if the pregnancy does not involve vascular structures that can cause uncontrollable bleeding. In the case of abdominal pregnancy with a live fetus, the approach must be by laparotomy.

6.0 Methotrexate

In selected cases, medical treatment with methotrexate can be as effective as laparoscopic surgery. However, the possible side effects associated with methotrexate therapy can adversely affect patient compliance to a higher degree than the surgical treatment option. As regards infertility, the prognosis after ectopic pregnancy does not appear to correlate with the characteristics of the extrauterine pregnancy but rather with the patient's age and medical history. Medical treatment is to be preferred in patients with

previous surgery, diffuse adhesions, contraindications to anesthesia, cornual pregnancy or failure of surgical treatment. Medical treatment is indicated if the levels of beta HCG are between 5000 and 10000 mU/ml and the diameter of the adnexal swelling is less than 4 cm. Methotrexate should be administered locally or systemically by intramuscular injection of 1 mg/kg or 50 mg/m². Patients with a hematocrit < 35% should take ferrous sulfate 325 mg twice daily.

7.0 Postoperative Follow-up Care

Patients may be discharged a few hours after the surgery. The bladder catheter is removed at the end of the operation. Antibiotic medication should be administered postoperatively. The first serum beta-HCG test is performed on the second day and the reduction compared to the preoperative value should be at least 70%. The test is repeated after seven days

to exclude the persistence of trophoblastic tissue. If the level is not below 20 mU/ml, the test is repeated two weeks later and if it is still positive, the patient should undergo further medical or surgical treatment. Persistent trophoblastic tissue can be treated successfully with methotrexate, ensuring that any anemia present is treated preventively.

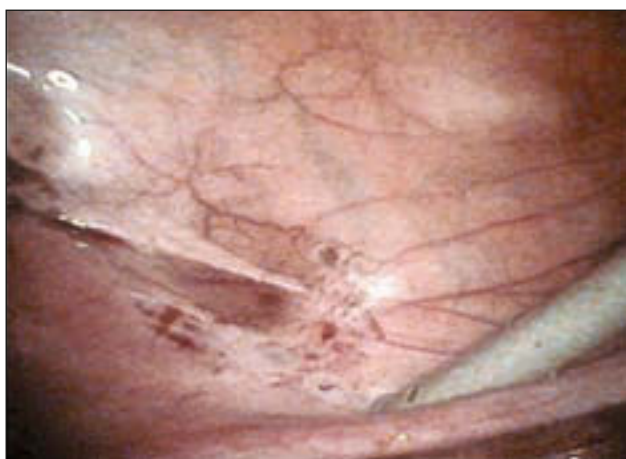Chapter X

Laparoscopic Surgery for Symptomatic Endometriosis

Luca Mencaglia¹, Arnaud Wattiez² and Sabina Consigli¹

¹Centro Oncologico Fiorentino, Florence, Italy

²Department of Gynecology and Obstetrics,
Strasbourg University Hospital, Strasbourg, France



1.0 Laparoscopic Surgery for Symptomatic Endometriosis

Introduction

Endometriosis is the presence of endometrial glands and stroma in an heterotopic location. Endometriosis is a progressive, debilitating disease that affects 10–15% of women during their reproductive years. Among gynecological disorders, endometriosis is second only after uterine myomas in frequency, and accounts for 25% of all laparotomies performed by gynecologists. In the planning of

treatment, many variables must be considered, such as age of the patients, extent of disease, degree of symptoms, and desire for immediate or deferred fertility. In most instances the indications for therapy include pain or infertility or both, and the treatment may be surgical or medical, or a combination of both.

2.0 Preoperative Assessment

The diagnosis of endometrioma is revealed by the presence of ovarian cyst fluid that can be suspected by transvaginal and transabdominal ultrasound (TU) and physical examination. The most common symptoms are infertility and/or pelvic pain which should facilitate establishing the final diagnosis. However, the diagnosis of peritoneal endometriosis is confirmed only by direct visualization with

the aid of laparoscopy and histological examination of biopsy specimens. Unfortunately, blood serum levels of anti-endometrial antibodies, placental proteins PP 14 and CA 125 marker do not have sufficient sensibility or specificity to be routinely used for diagnostic evaluation. Diagnostic preoperative examination must include in all patients a thorough history-taking, physical examination and TU.

3.0 Patient Positioning

Classical gynecological laparoscopic position, with intra-uterine manipulator. Two accessory 6 mm trocars should be used, one in either quadrant, medial to the umbilical

artery ligament. If a third accessory trocar is needed, this is placed in the midline, suprapubically.

4.0 Instrumentation

- Laparoscope and video camera
- 5 mm grasping forceps
- Scissors
- Bipolar or unipolar HF electrosurgery unit or laser system
- 6 mm trocars
- Suction-irrigation system for hydrodissection

5.0 Technique

The surgical treatment options for endometriosis are radical or conservative surgery. The aims of conservative surgery are:

- removal of both typical and atypical endometriotic implants;
- complete removal of endometriotic cysts (endometrioma)

- complete adhesiolysis, with restoration of normal tuboovarian relationship to enhance fertility potential;
- relief of pain;
- minimize the risk of disease recurrence.

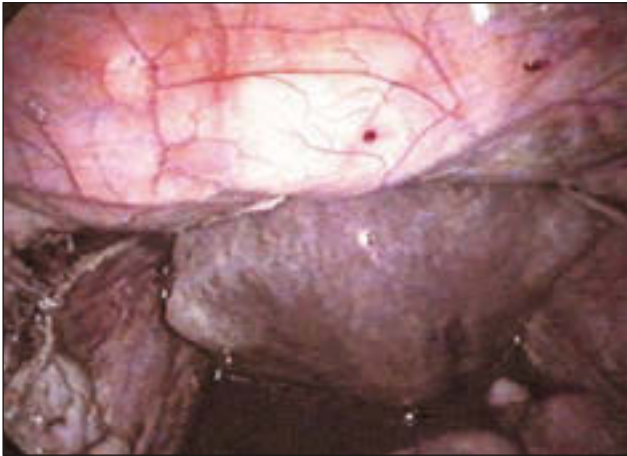


Fig. 1
Typical red spot of peritoneal endometriosis.

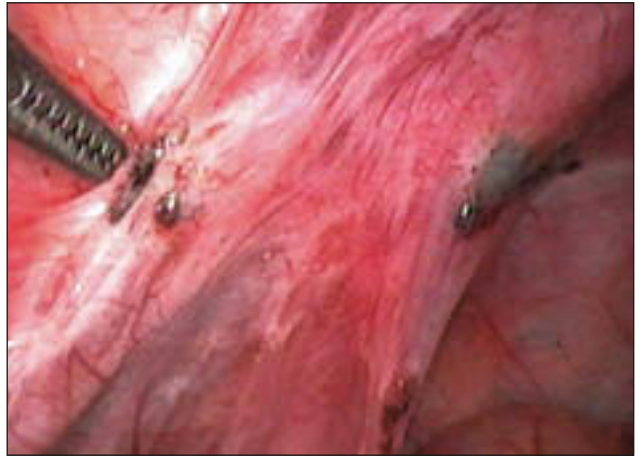


Fig. 2
Black spots of peritoneal endometriosis.

6.0 Laparoscopy

6.1 Diagnostic Laparoscopy

The first stage of the procedure involves exploring the pelvic anatomy and mapping out the extent of disease and the location and boundaries of the bladder, ureter, colon, rectum, utero sacral ligaments and major blood vessels.

6.2 Operative Laparoscopy

Peritoneal implants may be coagulated using unipolar or bipolar electrosurgery, vaporized by laser application or may be excised (**Figs. 1–2**).

The hydrodissection technique permits treatment of endometriotic implants on the ureter or major vessels without causing any damage to these structures (**Figs. 3–5**).

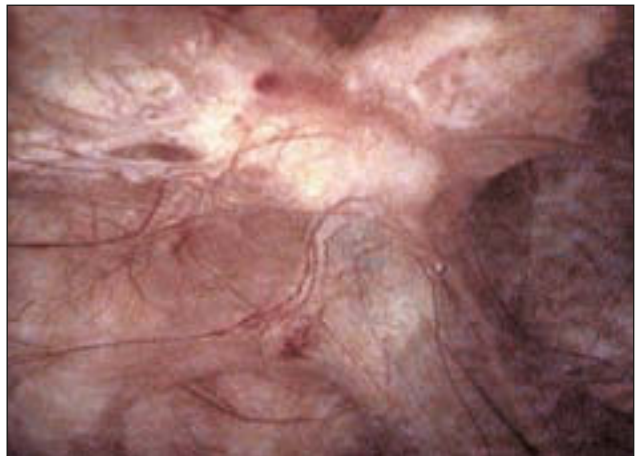

Fig. 3
Atypical peritoneal endometriosis.

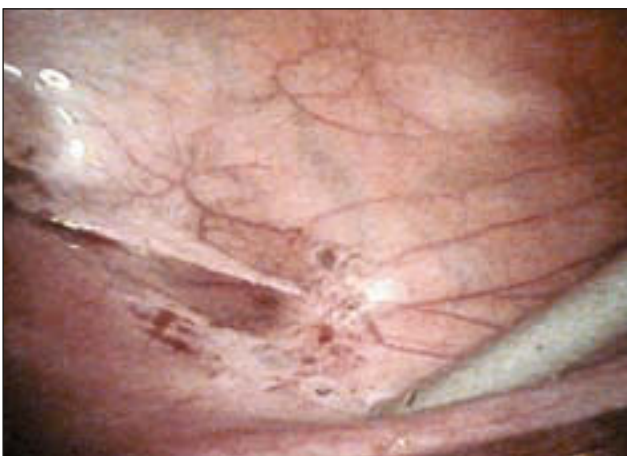

Fig. 4
Atypical peritoneal endometriosis.

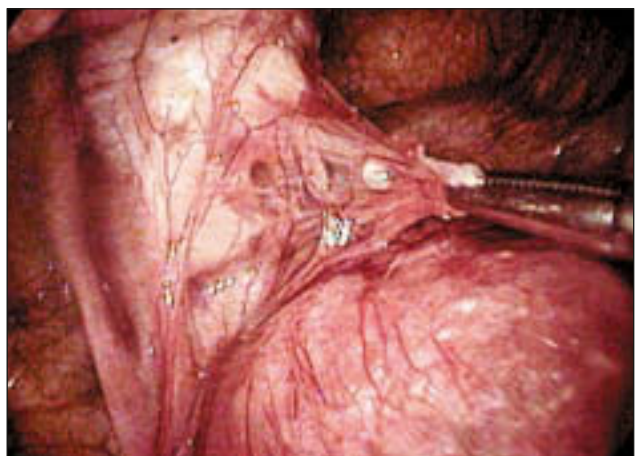

Fig. 5
Atypical peritoneal endometriosis.

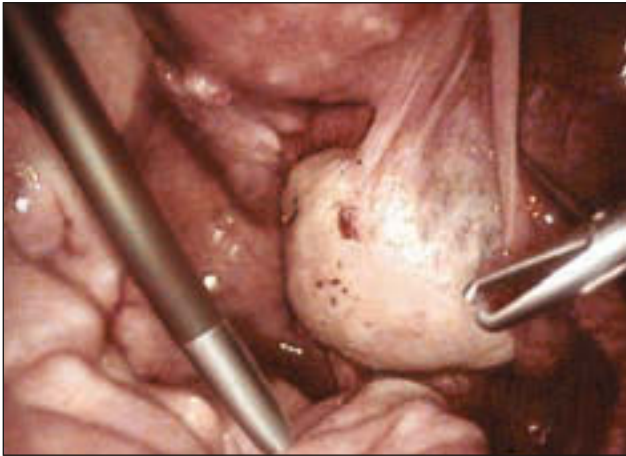


Fig. 6
Ovarian implants of endometriosis.

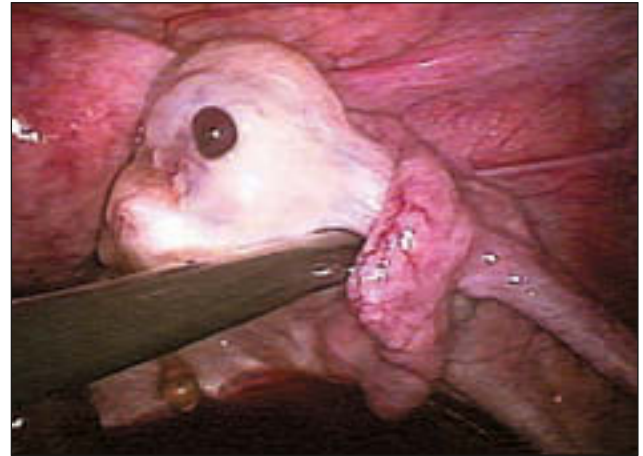


Fig. 7
Small ovarian endometrioma.

Initially, a small port is made into the retroperitoneum using either the laser or scissors. Ringer's lactate or saline solution is injected next to the lesion to create a protective cushion of fluid between the lesion to be excised and the underlying ureter, bladder or blood vessels. Excision of large endometriotic implants is superior to coagulation or vaporization because the technique is not associated with problems related to contamination by smoke and combustion residues. An additional advantage is, that it allows for the collection of specimen for histological diagnosis.

Ovarian Endometriosis

Ovarian implants of endometriosis or small endometrioma of less than 2 cm in diameter may be cauterized, resected by laser application or excised using scissors, biopsy forceps or electrodes (**Figs. 6–7**).

For endometrioma larger than 2 cm in diameter, the first step of the procedure involves adhesiolysis of the ovary on the posterior leaf of the broad ligament. In most cases, the cyst is ruptured during this step, which requires that the liquid be aspirated immediately to prevent pelvic contamination.

The cystic cavity is repeatedly irrigated with a suction-irrigation tube (**Figs. 8–9**).

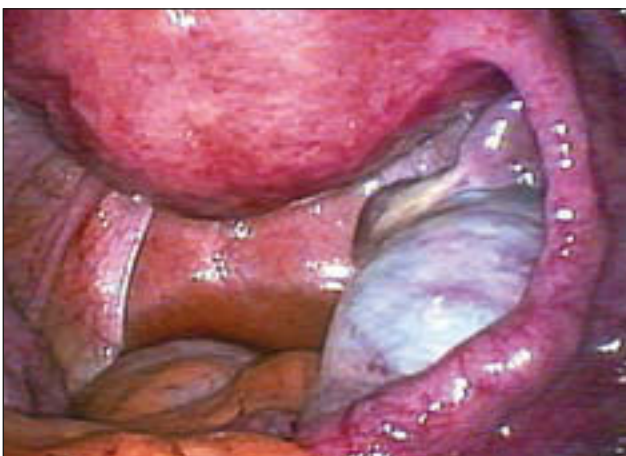


Fig. 8
Large ovarian endometrioma.

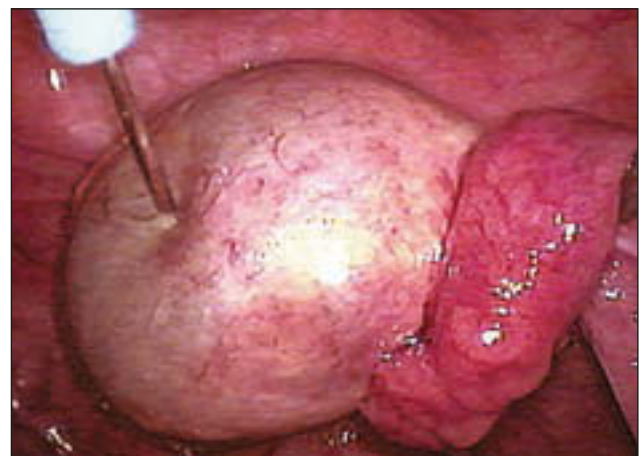


Fig. 9
Aspiration of ovarian endometrioma.

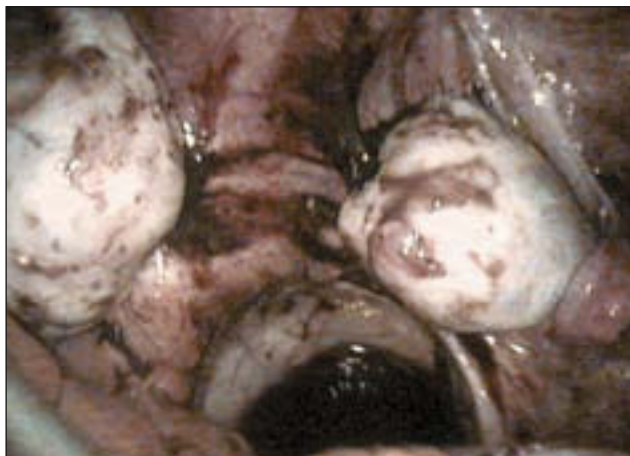

Fig. 10
Bilateral ovarian endometriomas.

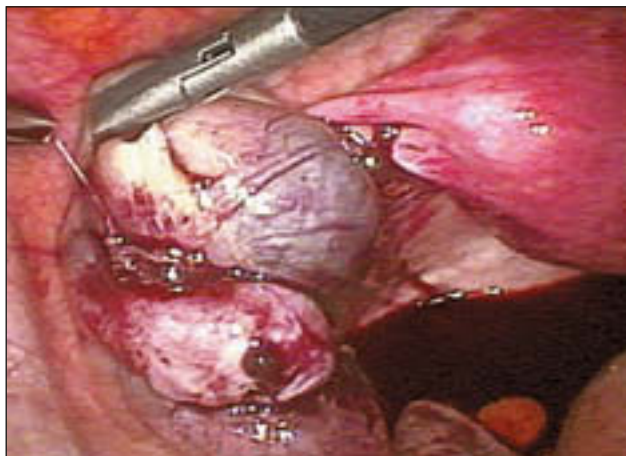


Fig. 11
Right ovarian endometrioma.

Examine the cystic wall for malignant lesions. Drainage of the cyst must be followed by removal of the capsule to prevent recurrences. The capsule of the cyst must be separated from the surrounding ovarian stroma and removed by grasping its base with forceps and pulling it away from and out of the ovarian capsule (**Figs. 10–13**).

Exposure of the right plane will permit blunt dissection by applying contralateral traction with two 5 mm-forceps. If stripping of the capsule is incomplete or difficult to accomplish, the residual part must be eradicated by laser application or electrocoagulation.

Presurgical treatment with GnRH analogues is useless in ovarian endometriomas, because it is not effective in reducing the size and volume of cysts and not even in facilitating the surgery.

Adnexectomy

Adnexectomy could be necessary even in fertile patients when endometriosis has infiltrated most of the parenchyma. After coagulation with a bipolar forceps, the proximal portion of the tube and of the uteroovarian ligament must be dissected with scissors. In addition, the infundibulo-pelvic ligament is coagulated and dissected applying traction to the ovary with grasping forceps. Therefore, the mesosalpinx should be completely dissected, after coagulation, to liberate the adnexa and to extract it by use of a disposable bag.

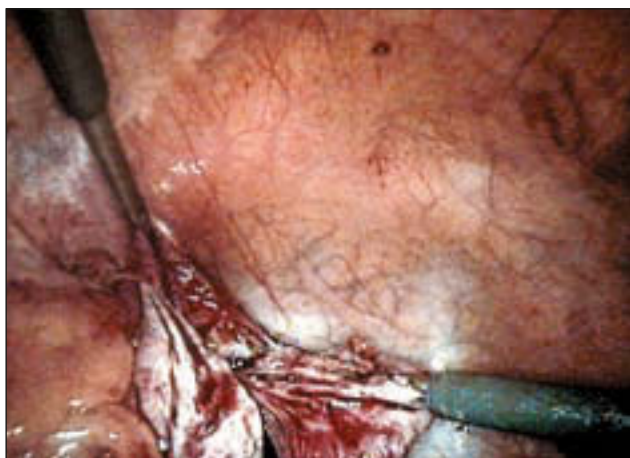

Fig. 12
Stripping of the endometriotic capsule.

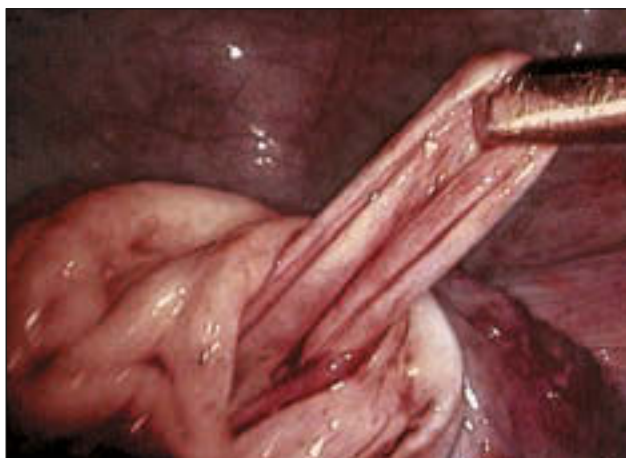

Fig. 13
Blunt dissection of the endometriotic capsule.

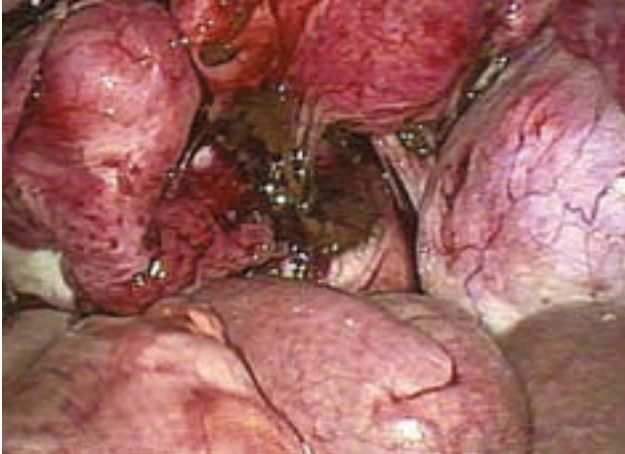


Fig. 14
Severe endometriosis with adhesions.

Adhesiolysis

Adhesiolysis may be performed using hydrodissection, scissors, CO₂ laser or atraumatic forceps. Before cutting the tissue it is important to mobilize and identify the relevant anatomical structures. Mechanical dissection with forceps or hydrodissection is not associated with any thermal effect, therefore this technique should be preferred.

Cul-de-sac obliteration is an important problem. It suggests rectovaginal involvement, with deep endometriosis and dense adhesions, and significant distortion of the regional anatomy involving bowel, vaginal apex, posterior cervix, ureter, and major blood vessels (**Fig. 14**).

To facilitate localization of anatomic landmarks and identification of tissue planes, we usually place a loaded sponge forceps in the posterior fornix, and, if necessary, insert a rectal probe. In difficult cases, ureteral probes can be placed preoperatively (**Figs. 15–16**).

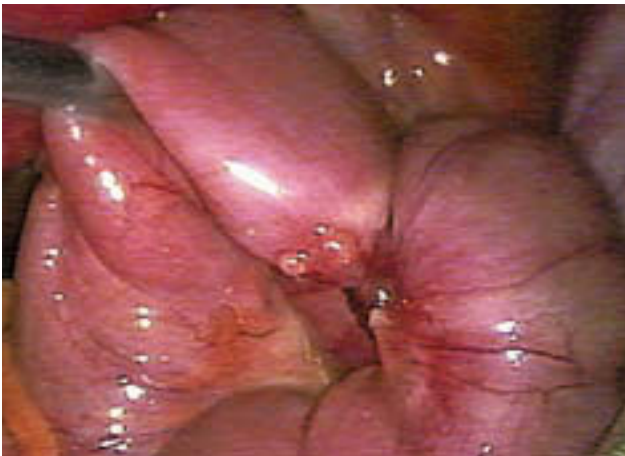

Fig. 15
Intestinal endometriotic nodule.

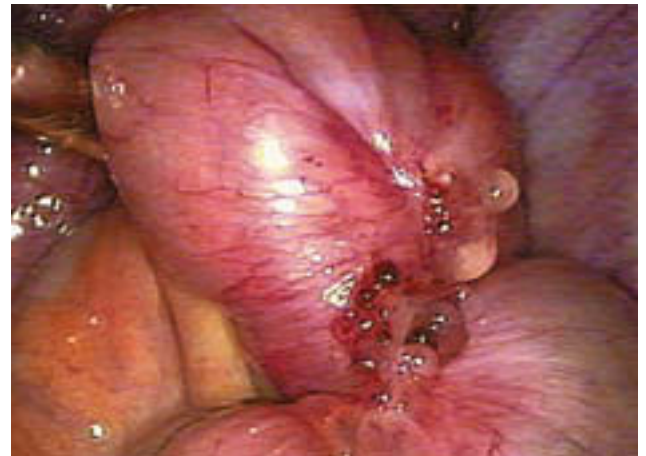

Fig. 16
Intestinal endometriotic nodule with stenosis.

7.0 Postoperative Care

According to the difficulties encountered during surgery, patients should be discharged 24 to 48 hours after surgery. Mild narcotic analgetics are usually sufficient to control postoperative pain. Postoperative therapy may include

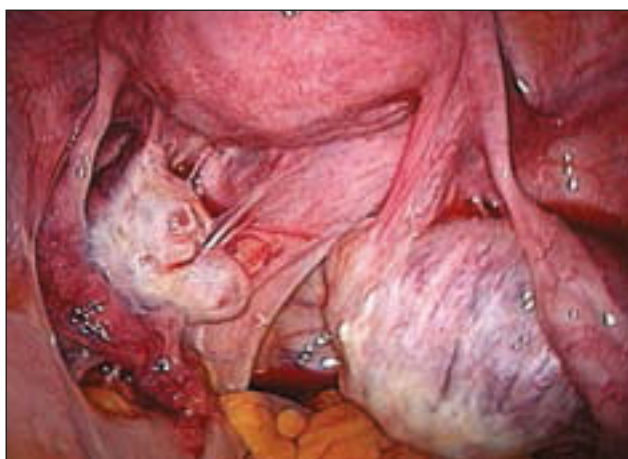
administration of GnRH analogues, Danazol or Gestrinone to prevent recurrences, to reduce pelvic pain and to facilitate subsequent induction of ovulation in infertile patients.

Chapter XI

Laparoscopic Management of Deep Endometriosis

Luca Minelli and Stefano Landi

Department of Gynecology and Obstetrics
“Sacro Cuore” General Hospital, Negrar, Italy



1.0 Introduction

Endometriosis is a highly debilitating disease that affects mainly women of childbearing age, characterized by symptoms such as pelvic pain, dysmenorrhea, painful defecation, dysuria and infertility. To date, all medical treatment options directed toward suppression of the disease and the pain associated with endometriosis have had similar effects in terms of symptom alleviation. None of them have proven long-term efficacy. Interruption of medical treatment is associated with a high risk of recurrence. However, evidence-based data suggest that complete laparoscopic excision of the endometriosis offers good long-term results with regard to the degree of regression, especially in those patients with severe and debilitating symptoms. *“The surgical treatment of endometriosis should aim at removing all visible areas of endometriosis with margins free from disease as*

is the case in oncologic surgery ... better with excision en bloc” (Redwine) and restoration of the anatomy, removal of adhesions.

Although it is difficult to know the real incidence of deeply infiltrating endometriosis, in a study on 132 patients, covering the predefined depth of endometriotic infiltration, we found deeply infiltrating lesions in 33%. Involvement of the gastrointestinal tract is present in about 3–36% of women affected by endometriosis and 50% of these are affected by severe disease. The gastrointestinal predilection sites are the rectum and sigmoid, accounting for 72–85% of cases. This means that to ensure complete removal of the disease and thus improve the outcome in terms of quality of life, surgery on the bowel with or without bowel resection can be necessary.

2.0 Instrumentation

- 10-mm laparoscope with 3 CCD videocamera
- One 11-mm trocar
- Two 6-mm trocars
- One 11/6 mm reducer
- Bipolar forceps

- Bipolar scissors with electrosurgical unit
- Suction and irrigation system
- Dissecting forceps (Schnaider)
- Grasping forceps (Dorsey)
- Maxon sutures with straight needle

3.0 Preoperative Assessment

Pre-operative assessment of endometrial implants plays a key role in the decision-making on the most effective strategy planning, possibly with the assistance of a general surgeon or urologist. Our pre-operative assessment comprises a questionnaire, physical work-up, instrument-aided investigations and serum markers. Particular attention is paid to the patient's history and symptoms, such as dysmenorrhea, pelvic pain, dyspareunia, painful defecation, covered by a specific questionnaire and assessed on a 10-point analog scale: 0 = absent 10 = unbearable. In addition, rectal and vaginal examinations are performed. Rectal examination allows the physician to reach 2.5 cm into the pelvis and assess a good portion of the rectal mucosa (about 7–8 cm of the rectum's length of 11 cm), palpate any masses and assess the thickness of the recto-vaginal septum and the nodular structure of the uterosacral ligaments. Rectal examination has a failure rate of 17–64% and is not sufficient on its own to diagnose deep endometriosis. Factors that can influence the diagnosis are the type of lesion, the depth of infiltration, the dimensions and the site of the lesion. Even if the examination is performed under general anesthesia, the sensitivity remains very low; its function as a screening test is limited and always requires another test for confirmation. Accurate data regarding co-involvement of the bladder and bowel cannot be obtained with a simple rectal and vaginal examination and a negative examination does not rule out involvement of these organs. The validity of the examination may be improved if performed during menstruation.

Instrument-aided investigations are essential: transvaginal ultrasound, ultrasound of the bladder and ureters, double-contrast enema, CA 125 and CA 199. As an alternative to the contrast enema, transrectal ultrasound can be performed but this requires specific instruments.

All patients should have stopped treatment with progestogens, GnRH agonists or the contraceptive pill 3–4 months before surgery. If intestinal involvement is suspected, specific preoperative preparation is necessary.

Preparation begins 24 hours beforehand. When intestinal surgery is highly likely, the patient must take 40 ml of Phosfo-Lax orally, diluted in a glass of water, followed by 1 liter of water at 2 p.m. and then at 4 p.m., or else 2 liters of Selg-Esse 1000 in the morning and 2 liters in the afternoon and 40 Mylicon tablets at once. Antibiotic prophylaxis consists of 2g of cefazoline at induction of anesthesia followed by 1g 3 times a day and metronidazole 500 mg 3 times a day for 3 days. If intestinal involvement and thus intestinal surgery are ruled out, an enema is administered on the day prior to surgery and 2g of cefazoline are given with induction of anesthesia as antibiotic prophylaxis. A Foley catheter is left in the bladder throughout surgery and until the patient is able to reach the toilet independently (usually on day 1 after surgery). After spontaneous urination, the post-voiding residual urine is measured until it is less than 100 cc in two successive measurements. If the post-voiding residual urine remains significant for more than 3–4 days after surgery, the patient is discharged after being instructed in self-catheterization.

Before starting the operation, the patient usually has a second vaginal and rectal examination under anesthesia.

Laparoscopy begins with the creation of a pneumoperitoneum using a Veress needle through the umbilicus, insertion of the 11-mm umbilical trocar for the laparoscope and placement of two accessory 6-mm ports lateral to the inferior epigastric vessels bilaterally and a third 6-mm suprapubic port. Complete resection of endometriotic lesions is achieved by use of bipolar scissors. In general, if bowel surgery is required, this is performed by a general surgeon specialist assisted by one of the two gynecological surgeons. At the end of the operation, copious lavage of the peritoneal cavity is performed with 500–1000 ml of Ringer's lactate solution and 4% icodextrin solution is left in the abdomen for adhesion

prevention. In these cases, a drain is left in place close to the anastomosis for 8–12 hours. The drain is usually removed after the first bowel movement. In general, a nasogastric tube is not required. During postoperative day 1, the patient is given continuous epidural analgesia through an elastomeric pump, after which analgesia is replaced by 100 mg of ketoprofen and 100 mg of tramadol i.m. or 0.3 mg of buprenorphine s.c., as required. Intravenous fluids are administered on the day of the operation and the next day patients can start to take food orally with a gradual increase in diet. The patients are discharged without a special diet. Prior to surgery, the patients are informed of the potential risks and benefits of the procedure by a written informed consent form.

4.0 The Surgical Technique

The type of surgery depends on the depth of invasion and the topographic distribution of endometriosis. The "classical" steps of the technique are as follows:

The laparoscopic procedure begins with laparoscopic inspection of the pelvic anatomy and systematic mapping of the endometriotic lesions (**Figs. 1–3**).

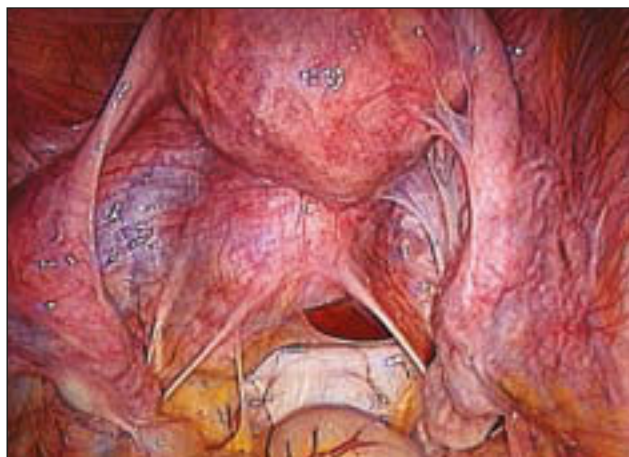

Fig. 1
Mapping of adhesions and endometriotic lesions.

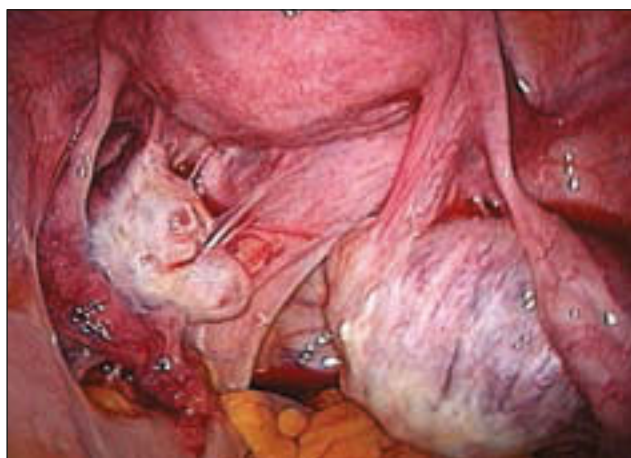


Fig. 2
Endometrioma with diffuse adhesions and lesions.

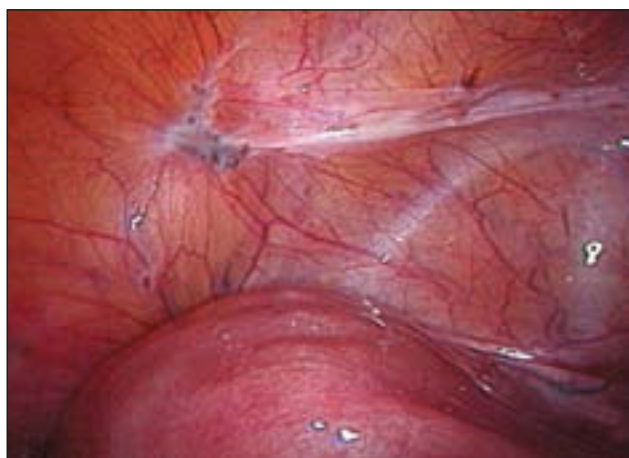

Fig. 3
Endometriotic lesions on the peritoneum.

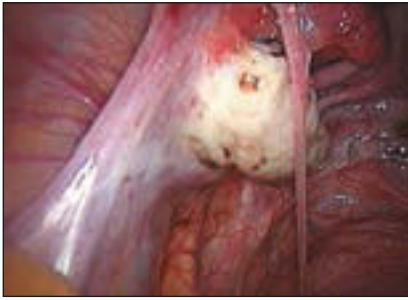

Fig. 4
Adhesions involving the ovary and the tube.

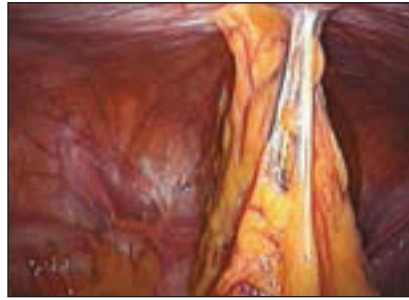


Fig. 5
Adhesions to the pelvic wall.

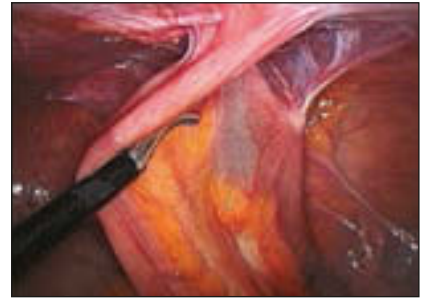

Fig. 6
Adhesions between the abdominal wall and intestine.

The caecum must always be inspected for the presence of endometriotic implants which could not be confirmed by preoperative double-contrast enema.

The operation proceeds with adhesiolysis, drainage and stripping of endometriomas, excision of endometriotic implants and other parietal implants, making sure that adequate healthy margins of retroperitoneal tissue are

included. Our standard method is to remove endometriomas completely without coagulating or vaporizing superficial peritoneal implants to be sure that there is no deep endometriosis.

Adhesions can be removed with various techniques but we prefer to use mechanical dissection with cold or bipolar scissors (**Figs. 4–6**).

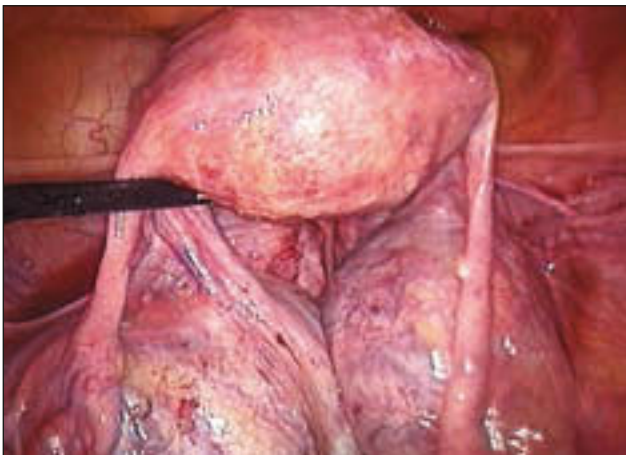


Fig. 7
Bilateral endometrioma.

Traction and blunt dissection can assist greatly in mobilizing and localizing structures that must be separated. We recommend avoiding hydrodissection and use of liquids because lavage of the peritoneum is much more difficult when distended with CO₂. In case of hemorrhage, application of a suction tube or a dry gauze pledget is recommended.

Very small endometriomas can be coagulated but in general, the “stripping” technique is preferred to avoid recurrence (**Figs. 7–11**).

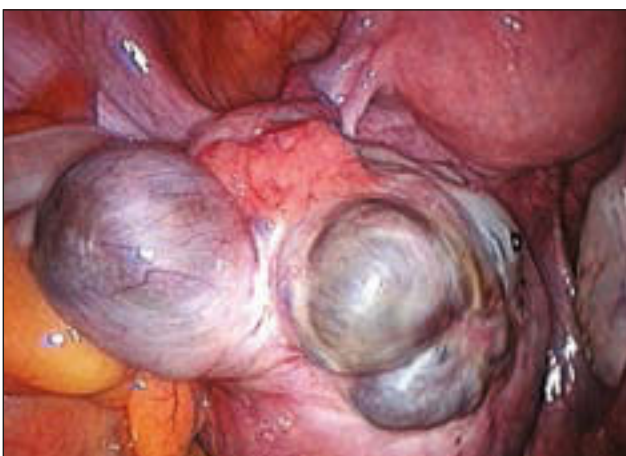

Fig. 8
Endometrioma of multilobular appearance.

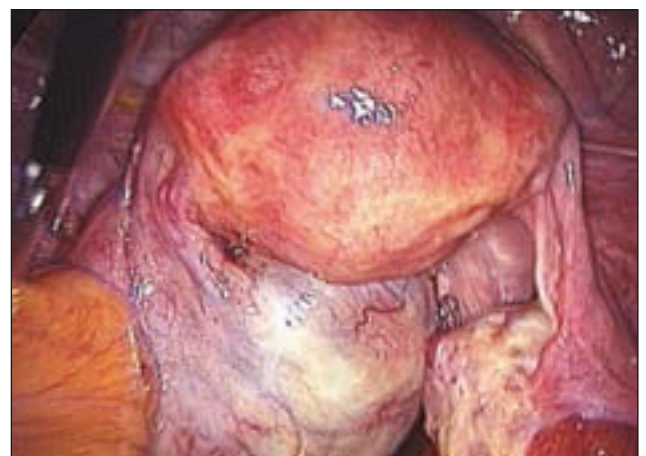

Fig. 9
Ovarian endometrioma with adhesions.

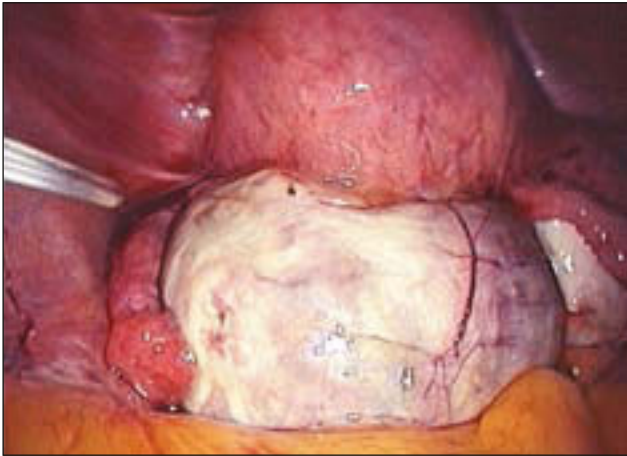

Fig. 10
Giant endometrioma.

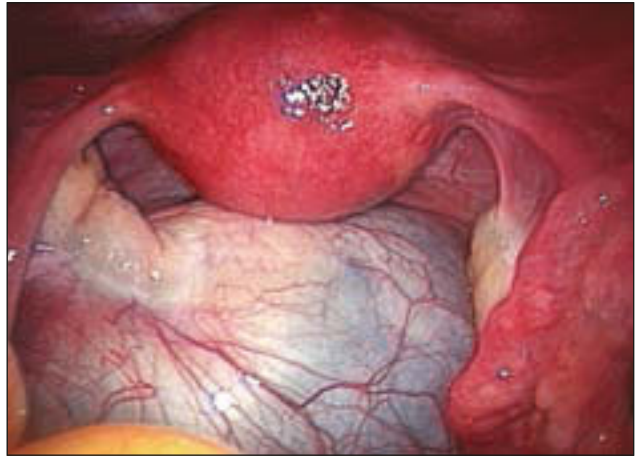


Fig. 11
Giant endometrioma of the right ovary.

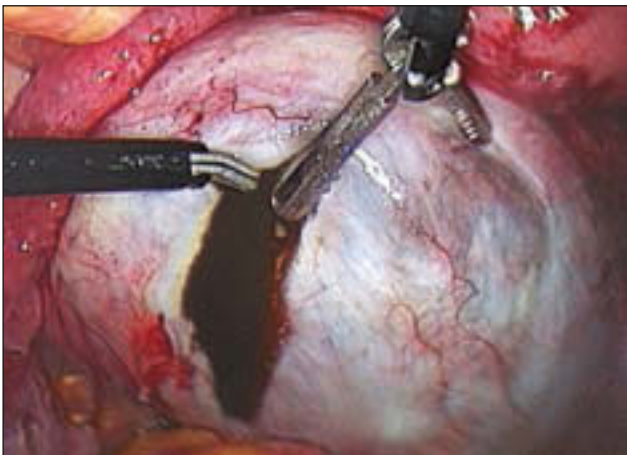


Fig. 12
Appearance of the endometrioma capsule.

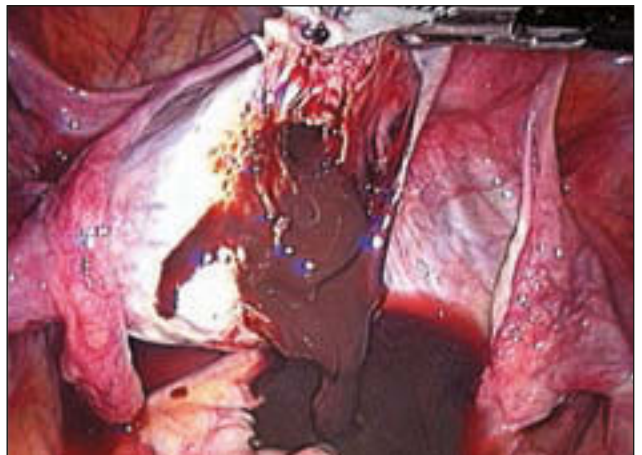


Fig. 13
Following incision, the contents are aspirated and the cavity of the cyst is irrigated.

The first step is to mobilize the ovary from the posterior leaf of the broad ligament to which it frequently forms dense adhesions. In the majority of cases, the cyst ruptures during this maneuver, which requires, that the chocolate-colored fluid be aspirated promptly. Ensuingly, the cavity of the cyst is irrigated several times. The cyst capsule is removed by grasping the margin of the fenestration and stripped off from the ovarian stroma to which counter-traction is applied with a 5-mm forceps. The correct plane of dissection is chosen when the capsule appears white or slightly yellow without red streaks; this allows bloodless dissection without any hemorrhage (**Figs. 12–14**).

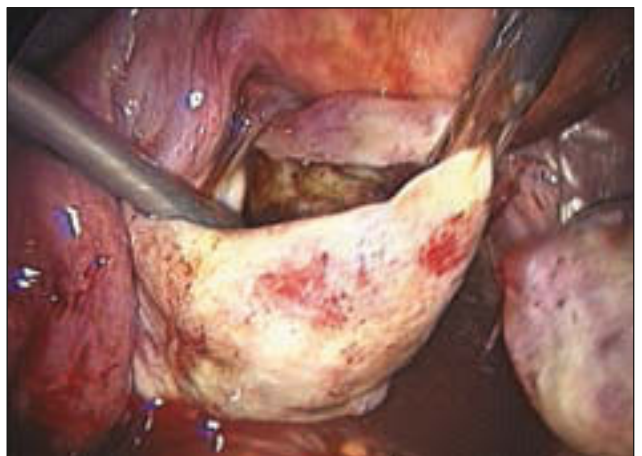

Fig. 14
The adjacent cyst capsule is removed by stripping.

Following stripping, meticulous and highly selective coagulation is required, holding the ovary with a forceps and visualizing each bleeding site by dripping saline on the base of the cyst. The capsule is extracted by use of a disposable bag. Very often, the ovary adheres to the pelvic wall and the peritoneum underneath can obscure additional endometriotic implants. These lesions must also be excised. It must be taken into account that the retroperitoneal fibrosis caused by the overlying adhesions frequently involves the ureter which often necessitates careful ureterolysis. Many endometriotic cysts are fixed to the ipsilateral uterosacral ligament by dense adhesions so the entire adhesion area between the cyst wall and the uterosacral ligament is removed en bloc.

In rare cases, adnexectomy is required. It is usually possible to maintain to some extent the ovarian follicular reserve and function. When surgery is performed on the ovaries, they are suspended temporarily at the end of the operation using non-absorbable 2/0 polypropylene sutures that are removed on the third postoperative day, as described by *Abuzeid*. This procedure allows better access to the pouch of Douglas and prevents formation of adnexal adhesions to sites of the pelvic cavity that were denuded of peritoneum (**Fig. 15**).

Starting from the pelvic area, the ureters and large vessels are localized and the ureter is then exposed down to the muscle wall following its course in the pelvis until healthy tissue is reached. If endometriosis extends deeply and laterally in the uterosacral cardinal ligament, it is sometimes necessary to sacrifice branches of the internal iliac artery, usually the uterine artery, or expose it as far as the intersection with the ureter. In extreme cases, the ureteric muscularis can be invaded by endometriosis, leading to partial constriction. In these cases, resection of the involved segment of the ureter may become necessary, followed by reanastomosis.

The basic principle is to liberate the obliterated cul-de-sac by en-bloc excision of the deep pelvic endometriosis.

The line of resection in healthy non-fibrosed peritoneum starts laterally and runs parallel to the base of the uterosacral ligament. The area is then exposed by blunt dissection. A transverse incision is made at the uterine isthmus superior to the point of adherence to the bowel, and is carried downwards along the posterior cervical wall with intrafascial dissection. The plane of dissection is continued caudally as far as the rectovaginal septum so that the healthy rectal wall can be liberated from the endometriotic nodule. The uterosacral ligaments are resected at the site of insertion in the cervix. As it is often difficult to find the correct planes of dissection, it is necessary to operate behind the nodule.

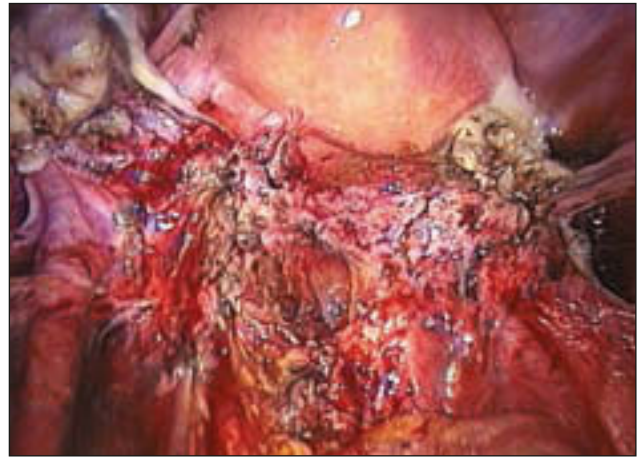

Fig. 15

At the end of the surgery, the pelvic cavity is completely denuded of peritoneum.

Every adhesion of fibrous or fat tissue between the rectum and the lateral pelvic wall is gradually divided until the bowel has been sufficiently mobilized.

In this way, the entire endometriotic nodule remains adherent to the anterior wall of the bowel forming a single mass with the uterosacral ligaments and obliterated cul-de-sac. Where the disease invades the posterior vaginal fornix, the vagina is opened. In the case of endometriotic infiltration of the vaginal mucosa itself, a vaginal approach can be useful to delineate and mobilize the nodule by digital dissection prior to initiating laparoscopic dissection; this follows the posterior lip of the cervix first and then the vaginal incision, making sure that all of the vaginal lesion is included in the mass adherent to the bowel.

Bowel surgery is performed at this point and can involve superficial, partial thickness, full thickness or segmental resection. Given the frequent involvement of the submucosal layer, to ensure complete excision of the endometriosis we recommend full thickness or segmental intestinal resection. We consider superficial "peeling" or peeling of the mucosa only in selected cases.

Even if full thickness bowel resection can be performed stepwise while the nodule is excised from the bowel and sutured in double layers, we consider the use of a linear stapler positioned perpendicular to the bowel axis is extremely safe and, beyond that, not expensive (**Figs. 16–20**).

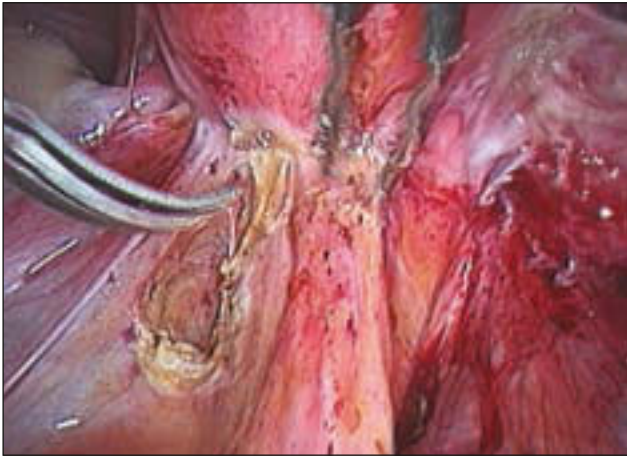


Fig. 16
The rectum is densely adherent to the uterine corpus obliterating the cul-de-sac.

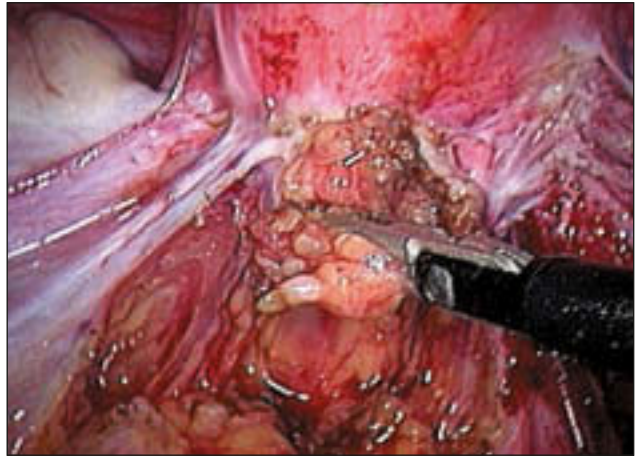


Fig. 17
Adhesiolysis and exposure of the deep rectovaginal endometriotic nodule.

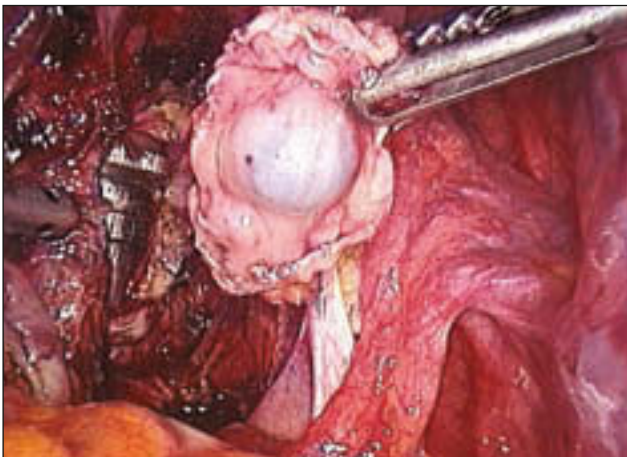


Fig. 18
The nodule is completely excised.

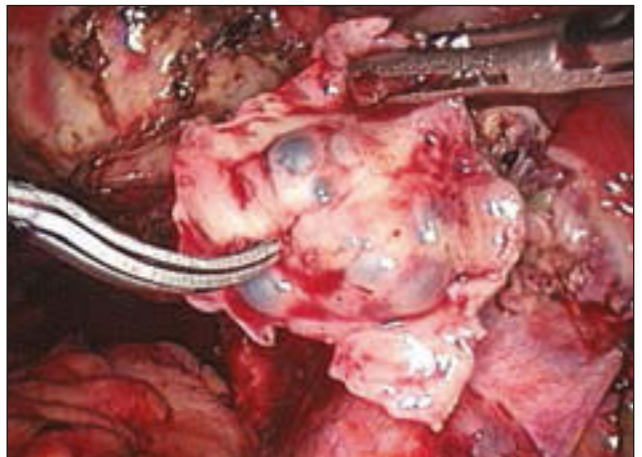

Fig. 19
En bloc excision of the endometriotic lesion.

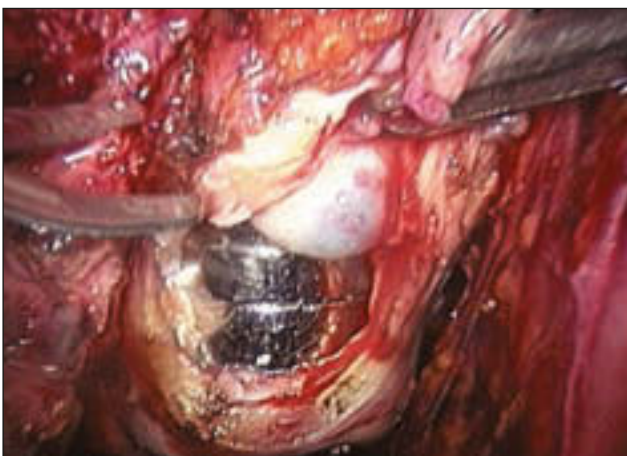

Fig. 20
Bowel resection with introduction of a transanal stapler.

The bowel segment invaded by the endometriotic nodule is grasped with a forceps while positioning a linear stapler and firing precisely below the nodule. The technique is limited in that it can be used only for small-sized lesions (< 3 cm) and if the reduction in bowel lumen is less than 50%. To completely remove an anterior rectal lesion smaller than 3 cm, which would require an ultralow resection (up to 6 cm from the anal sphincter), we suggest the use of a circular stapler (CEEA) as described by *H. Reich*. The nodule is trans-fixed perpendicular to the bowel axis in such a way that it can be pushed between the anvil and the body of the circular stapler which has been inserted through the anal canal.

When transanal resection is planned, after placing a fourth trocar in the right upper outer quadrant, the bowel is mobilized laparoscopically using an ultrasonic scalpel (Ultracision).

The involved bowel segment is exposed, safeguarding the mesentery and the vessels close to the intestinal wall. The fat is stripped away from the healthy distal bowel segment, exposing the intact muscularis propria through 360 degrees so that the sutures for colorectal anastomosis can be placed very safely with the circular stapler using the Knight-Griffen technique. A linear endoscopic stapler is then applied with a safety margin of 1 cm away from the nodule in the healthy distal bowel. Then, the proximal segment of rectosigmoid colon with the endometriotic nodule at its stapled end is extracted through the suprapubic port, which is prophylactically extended. The bowel segment involved is transected at about 1 cm proximal to the endometriotic mass. The anvil of the circular stapler is secured with a purse string suture to the distal bowel opening and reintroduced into the abdominal cavity. Next, a 28 or 32 mm circular end-to-end anastomosis (CEEA) stapling

device is introduced transanally to complete the procedure. Occasionally, for rectosigmoid lesions, a segmental bowel resection through a Pfannenstiel minilaparotomy with end-to-end hand-sewn anastomosis is performed under direct visual control.

Alternatively, the proximal bowel segment can be exteriorized transvaginally, resected and placed in the anvil of the circular stapler. After completing the end-to-end anastomosis the vagina is closed laparoscopically and an omental flap is created and interposed between vagina and colon to prevent the two sutures from getting into contact. The integrity of the anastomosis is tested by filling the pelvic cavity with saline and insufflating air into the rectum while the more proximal part of the sigmoid is occluded mechanically with forceps.

In our experience of 600 cases of complete excision of advanced endometriosis, we have found negative effects on the bladder, rectum and sexual activity. In this respect, the results of studies recently published by *Thomassin* and *Darai*, do not correspond with our own. There may be various rationales for this inconsistency. However, all authors agree on the significance of sparing the pelvic nerve plexuses.

The autonomic pelvic nerves in fact provide neurogenic control of the rectum, bladder and sexual area (vaginal lubrication and sweating). Among position-related iatrogenic nerve injuries, the inferior hypogastric plexus is most often affected during excision of endometriotic nodules from the uterosacral ligaments and the lateral adjacent area. To reduce to a minimum the risk of inadvertent nerve injury at this level the best safeguard is to observe certain rules that will be described below.

4.1 Protection of the Sympathetic Mesorectum Nerve Fibers; Superior Hypogastric Plexus, Hypogastric Nerves and Lumbosacral Sympathetic Trunk

The superior hypogastric plexus is formed by sympathetic nerve fibers lying in the presacral space at the level of the promontory, covered by peritoneum and by the anterior layer of the visceral pelvic fascia. The right and left hypogastric nerves originate from this plexus and descend 8–10 cm lateral to the mesorectum in the visceral pelvic fascia following the cranio-caudal course of the ureter. These nerves can be localized by opening the peritoneum at the level of the sacral promontory to gain access to the presacral space. Blunt dissection of the loose adipose tissue in the rectosacral space as far as the rectosacral fascia allows identification of the superior hypogastric plexus and the hypogastric nerves close to the sacrum and distant from the mesorectum, which is drawn ventrally and caudally with the rectum. If this is done, innervation is preserved completely during dissection of the upper part of the mesorectum. To mobilize the rectosigmoid

fully and reach the inferior part of the mesorectum as far as the rectal wings, the pararectal fossae must be unified in the retrorectal space by blunt dissection as far as the space known as “*The Holy Plane of Heald*” located in the midline; when this has been identified, the posterior and lateral mesorectal fascia is preserved by dissecting the loose and relatively avascular connective tissue between the visceral mesorectal fascia and the parietal endopelvic fascia. The medial and distal segments of the hypogastric nerves adhere to the mesorectum fascia at this level and can be injured if they are not exposed. Dissection is continued as far as the floor of the pararectal spaces, always staying close to the rectum to preserve the superior hypogastric plexus and the hypogastric nerves medially and cranially, and the ganglia and lumbosacral sympathetic trunks laterally and dorsally, close to the sacrum.

4.2 Protection of the Sympathetic Fibers of the Inferior Mesorectum: the Inferior-most Aspect of the Hypogastric Nerves and the Proximal Aspect of the Inferior Hypogastric Plexus

It is extremely important to localize and lateralize the hypogastric nerves and their connections to the proximal part of the inferior hypogastric plexus. After opening the retroperitoneum of the presacral space and prior to initiating dissection of the uterosacral ligaments and rectal pillars, the thin and delicate lateral part of the visceral presacral pelvic fascia between the prerectal space and the pararectal space is mobilized and lateralized carefully. This lateral part is crossed by the hypogastric nerves, the anterior branches of the sacral sympathetic trunks, the parasympathetic pelvic splanchnic nerves and more ventrally and caudally

by the proximal aspect of the inferior hypogastric plexus. It is not always easy to identify the hypogastric nerves in the presacral space because their thickness varies greatly (4–7 mm), they are completely surrounded by fatty tissue and they sometimes give off multiple nerve fibers. However, clear identification, exposure and preservation of these nerves are feasible through laparoscopy and should always be attempted.

At this level, they run from lateral to medial in a cranio-caudal direction approximately 20 mm to 5 mm inferior to the ureter.

4.3 Protection of the Splanchnic Nerves and of the Medial and Inferior Aspects of the Hypogastric Plexus in the Inferior Mesorectal Spaces

The parasympathetic innervation of the pelvic organs, rectosigmoid and anal canal is provided by the splanchnic nerves which originate from the S2–S4 sacral roots. 3–5 branches originate from the pelvic splanchnic nerves 3–4 and 1–2 cm laterally and inferior to the pouch of Douglas; they perforate the endopelvic fascia, cross the ventral aspect of the piriformis muscle and then converge with the terminal branches of the ipsilateral hypogastric nerve about 1 cm ventral to the inferior hypogastric plexus. The plexus is located bilaterally in the presacral aspect of the endopelvic fascia between the posterior vaginal fornix and the rectum in the ventral part of the lateral rectal ligaments. When the inferior-most aspect of the posterolateral parametrium is involved by endometriosis, it is resected sparing the dense connective tissue and the fatty tissue surrounding the nerve fibers of the cranial and medial aspect of the inferior hypogastric plexus. Ideally, the plane of dissection should not enter the space, similar to the keel of a boat, which is located between the anterolateral planes of the mesorectum and the rectal wings. A surgical anatomical reference point that we use to separate the lateral parametrium and the vascular part (ventral and cranial) of the nerve (dorsal and caudal) is the deep uterine vein.

The lateral ligaments of the rectum run close to the splanchnic nerves in 30% of cases, cross the pelvic plexus and then

continue with the medial efferent bundle of the pelvic plexus up to the lateral or anterolateral surface of the rectum. In a recent study, *Ercoli* showed, that the pelvic splanchnic nerves are at high position-related risk of iatrogenic injury because they are in close proximity to these ligaments in 70% of cases. Proper identification of the splanchnic nerves at their origin from the sacral roots allows safe dissection of the rectal wings and the inferior mesorectal planes.

Always keeping the parasympathetic nerves under vision allows the nerve fibers to be kept distant from the debulking planes.

Moreover, by following their course until they converge with the hypogastric nerves it is possible to localize the origin of the pelvic plexus, caudal to the course of the deep uterine vein, particularly the efferent branches and the visceral afferent branches of the uterus, vagina and bladder. During bowel resection, after excision of the mesosigmoid with sparing of the innervation described above, only selective neuroablation of a small quantity of nerve fibers of the medial efferent bundle of the pelvic plexus is performed, directed medially towards the rectum and traversing the mesorectum. In fact, only the rectal fibers of the resected segment of bowel are transected, minimizing rectal denervation.

4.4 Protection of the Caudal Aspect of the Inferior Hypogastric Plexus

The distal aspect of the inferior hypogastric plexus is located in the posterior part of the vesico-uterine ligament, lateral and caudal to the distal ureter. To preserve it, after preparing the ureteric tunnel and the so-called space of Morrow medial and central to the ureter, the lateral aspect of the nerves and the medial vascular part of the vesico-uterine ligament are

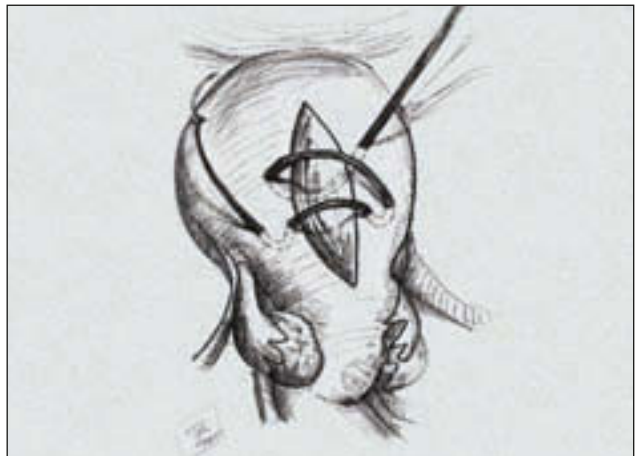
dissected. It is necessary to divide the pubocervical fascia consisting of the cranial and caudal part of the vesico-uterine and vesico-vaginal ligaments at the point where its reflection will form the ureteric tunnel. In this way, the surgeon gains safe access to the paravaginal space.

Chapter XII

Technique of Laparoscopic Myomectomy

Stefano Landi and Luca Minelli

Department of Gynecology and Obstetrics
"Sacro Cuore" General Hospital, Negrar, Italy



1.0 Introduction

The traditional criteria for the surgical management of uterine fibroids are infertility, recurrent abortions, obstetric complications, abnormal contour of the abdominal wall, abdominal and pelvic pain, abnormal uterine bleeding and menorrhagia attributable to fibroids. In addition, women who reject hysterectomy because they wish to maintain fertility potential can choose this type of surgery.

There are still no clear indications with regard to the laparoscopic approach but laparoscopic myomectomy (LM) has been broadly accepted recently.

The technique of LM does not differ from that of laparotomy.

As regards its benefits and the low risk of complications, LM can be considered a valid alternative to myomectomy via laparotomy even though it remains a challenging technique. In expert hands, LM appears to provide the same results as myomectomy via a laparotomy approach in terms of fertility and pregnancy and has a definite advantage with regard to the risk of postoperative adhesions. Regarding recurrence evaluation, the results are unclear but it is probably similar with both techniques.

Certainly, there are technical limitations in LM so preoperative assessment of the patients is extremely important.

2.0 Patient Selection Criteria

Analysis of the largest series published in the literature so far shows that LM is used in cases of one or two myomas about 5 cm in diameter. The controversy about the number and size of myomas that can be managed by laparoscopy has not yet been resolved. The generally considered limits are 3 myomas and a diameter of 8 cm or a uterus corresponding in size to a 16 weeks gestation and a myoma measuring 12 cm. In the literature, *Nezhat* reported on a myomectomy 15 cm in diameter. In our view, patient selection largely depends on the experience of the surgical team. As a matter of course, we decide not to perform LM in the presence of a large number of myomas (more than 5–10) because the procedure would become extremely long, small myomas may be missed and there may not be sufficient space for suturing the uterine walls if the organ has been subjected to multiple incisions. In our experience, the size is secondary to the number of myomas when deciding on whether a patient meets the selection criteria of LM.

In a retrospective study of 426 women, four independent factors were found to correlate with the risk of conversion to an open procedure: myoma size larger than 5 cm, intramural myoma, anterior location and preoperative use of GnRH agonists. No mention was made on the number of myomas which could represent a bias in the selection of patients. Although this predictive model, which uses ultrasound for three of the four criteria, has not been validated, it allows us to state that preoperative ultrasound assessment can be of instrumental value. In our department, patients are accepted for LM only after detailed ultrasound examination in the early proliferative phase.

It has been suggested that intramural fibroids that reach the uterine cavity can be a contraindication to LM because of intra- and postoperative bleeding and inadequate multilayer closure of the endometrium/myometrium. However, other studies have demonstrated the safety of this procedure even in the case of intramural myomas.

3.0 Preoperative Use of GnRH Analogs

There are many reasons for avoiding the preoperative use of GnRH analogs:

- possible delay in the diagnosis of leiomyosarcoma
- increase in hyalinization phenomena
- prolongation of operation times
- difficulty in localizing the cleavage planes
- obliteration of the myoma-myometrium boundary
- increased incidence of conversions

However, there is a prospective study by *Zullo* in 1998, which found that the use of analogs for two months prior to surgery produced low blood loss, shorter operating time, an increase in red blood cells, hemoglobin and postoperative iron in all cases except markedly hypo-echogenic fibroids where there was an increase in operating times. The same author states

that use of tibolone as add-back therapy does not change the efficacy in terms of operation times and rate of blood loss compared to the GnRH analog alone.

Preoperative use of GnRH analogs in patients undergoing myomectomy would appear to increase the risk of recurrence and a recent study by *Rossetti* confirms the negative effect on recurrence. A possible explanation was given by *Fedele* who reported an increase in recurrence rate for small myomas (< 1.5 cm) after GnRH analog treatment, stating that the reason is probably to be found in the simple fact that they were missed during myomectomy rather than recurrence as such.

A reduction in the size of the myomas has also been reported with preoperative administration of GnRH antagonists and of mifepristone (progesterone antagonist).

4.0 Instrumentation

- 1 x 10 mm-laparoscope with 3 CCD or **IMAGE 1™** camera
 - 2 x 11 mm-trocars
 - 2 x 6 mm-trocars
 - 1 x 15 or 20-mm trocar
 - 1 x 15/10 mm reducer
 - 1 x 10/5 mm reducer
 - 1 x laparoscopy needle
 - 1 x 60 cc syringe
- Vasoconstrictive agent
 - Unipolar hook electrode
 - Bipolar forceps with electrosurgical unit
 - Suction and irrigation system
 - Myoma or helicoidal forceps
 - Suturing instruments
 - Suture material, 27 or 36 needles
 - Morcellator

5.0 Technique

Under general endotracheal anesthesia, the patient is placed supine in Trendelenburg position with her arms by her sides. A Foley catheter is placed in the bladder.

Before starting the laparoscopic procedure, a diagnostic hysteroscopy is always performed while intraoperative hysteroscopy is performed only in the case of submucous myomas.

The cervix is grasped with a tenaculum and the manipulator is inserted in the uterus for manipulation.

The abdomen is insufflated with CO₂ up to a pressure of 12–13 mmHg through a Veress needle inserted through the umbilicus. An 11-mm trocar port is at umbilical level, two ancillary 6-mm ports are placed under direct vision lateral to the inferior epigastric vessels and a 11-mm port is inserted suprapubically at the level of the posterior wall of the uterus and then replaced by a 15 or 20 mm trocar to facilitate suturing and morcellation. In the case of a myoma with a diameter of more than 10 cm, the primary port is created 3–4 cm above the transverse umbilical line and moved slightly to the right whereas the suprapubic port is introduced at umbilical level.

The bowel and omentum are displaced to the upper part of the abdomen. It can sometimes be difficult to localize small myomas deeply embedded in the myometrium. In these cases, a laparoscopic ultrasound probe can be useful (**Fig. 1**).

Before initiating the myomectomy, all of the pelvis and the upper abdomen are endoscopically examined and if any pathology is detected, this is treated first.

Transcervical chromopertubation must be performed prior to myomectomy because later the methylene blue would drain preferentially through the myometrial incisions.

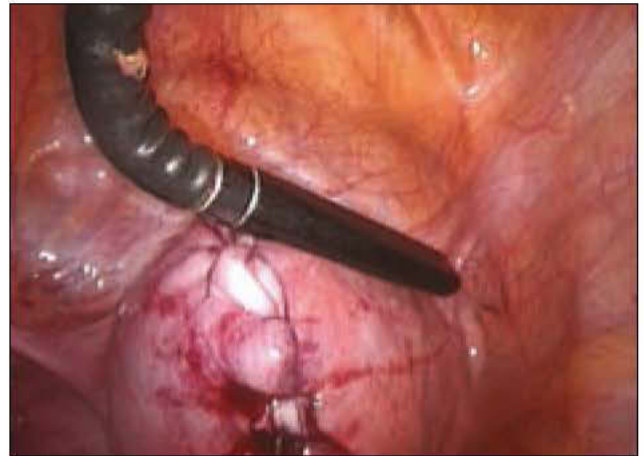


Fig. 1 Use of the laparoscopic ultrasound probe allows accurate localization of a small anterolateral intramural myoma following removal of a fibroid from the uterine fundus.

5.1 Injection of up to 40 ml of 9-arginine Vasopressin at a Concentration of 0.6 U/ml in Saline into the Pedicle or Body of Each Myoma

The use of vasoconstrictive agents has been shown to be as effective in laparoscopy as in laparotomy. They allow faster and easier enucleation with occasional use of bipolar electrosurgery for hemostasis, and above all, they reduce blood loss and thus the need for transfusions. In our experience, the real advantage is that they provide a clear view of the operative field. Unfortunately, the use of vasoconstrictors is not permitted in many European countries. Traditionally, Por-8 (8-ornithine vasopressin), a synthetic derivative of vasopressin, a strong vasoconstrictor with weak antidiuretic effects, has been used for many years but is no longer commercially available. Subsequently, some authors suggested using glypressin (triglycyl-lysine vasopressin, triglycyl-vasopressin), which is usually employed to treat bleeding esophageal varices. It is an analog of antidiuretic hormone with about 3% of the antidiuretic effect of vasopressin. The theoretical advantage is that it does not cause constriction of the coronary arteries as it is a pharmacologically inactive drug precursor that must be biotransformed to lysopressin (40–60 minutes) by endo- and exopeptidases in the liver and kidney.

Pitressin (8-arginine vasopressin), a derivative of vasopressin, is used widely in the United States. In the past, it was used in different concentrations, even up to 20 U in

20 ml of saline. Its period of activity is 20–30 minutes and should be metabolized before the end of surgery. Use of the vasoconstrictor is often not well tolerated and cases of bronchoconstriction, urticaria, anaphylactic reaction and myocardial infarction have been reported. When used, this must be under the strict control of the anesthetists.

During laparoscopic myomectomy, one case of hypertension followed by hypotension after 3–5 ml at 0.6 U/ml, one case of pulmonary edema after 10 ml at 0.5 U/ml and one case of transitory hypertension after 70 ml at 0.05 U/l of Por-8 have been reported.

Recently, use of bupivacaine hydrochloride 0.25% + 0.5 ml of epinephrine (1/2 ampoule of 1 mg/ml) has been shown to be effective and safe in reducing hemorrhage, operating time and time required for myoma enucleation. The problem is that the constrictive effect lasts for 5–6 hours so there is a hypothetical risk of not obtaining accurate hemostasis with delayed postoperative bleeding and tissue damage due to the prolonged hypo-oxygenation. The hypothesis that bupivacaine produces compensatory vasodilatation has yet to be demonstrated. Methylergometrine maleate and sulprostone should be used only in study protocols as their safety and efficacy in gynecologic surgery have yet to be demonstrated.

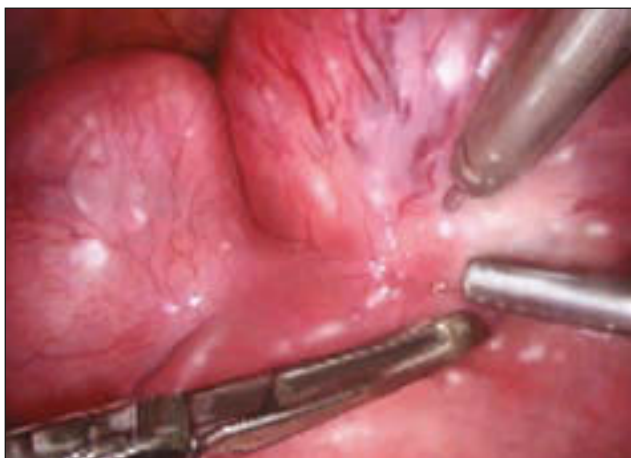

Fig. 2
Injection of up to 40 ml of 9-arginine vasopressin at a concentration of 0.6 U/ml in saline into the myoma pedicle. Remember always to aspirate prior to administration of the vasoconstrictive agent to make sure that it is not injected in a blood vessel.

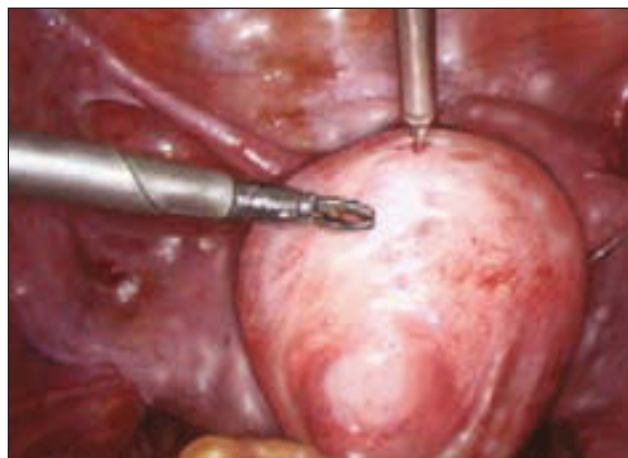


Fig. 3
Injection of up to 40 ml of 9-arginine vasopressin at a concentration of 0.6 U/ml in saline into the body of a myoma.

One to three injections per myoma may be necessary (**Figs. 2, 3**). A few seconds after injection, the myometrium begins to turn pale. If excessive resistance is encountered during injection it is better to draw back the needle until the resistance disappears, which signifies that the needle is

between the myoma and pseudocapsule; hydrodissection can also be useful. If the liquid escapes through a previously made needle opening, this confirms that the hydrodissection cannula is in the proper cleavage plane.

5.2 Myometrial Incision with Unipolar Hook Electrode or Scissors Using Pure High-Power Cutting Current

A linear or elliptical incision (**Fig. 4**) for very large or pedunculated myomas should be made over the myoma. The standard incision is vertical (oblique in the case of an anterior myoma) at the level of the most prominent part of the myometrium and is carried down to the surrounding pseudocapsule until the pearly structure of the myoma is exposed (**Fig. 5**). Even if the arteries and arterioles of the myometrium have a transverse course, a vertical incision is preferred because suturing is more effective and easier to accomplish. Reduced blood loss has been reported with transverse incision of the uterus.

Koh suggests ultralateral placement of the ports with two working trocars, both on the right side. With the traditional set-up of the sites of trocar insertion, the incision should be oblique in the case of anterior myoma in line with the needle holder located in the lateral port. In the case of fundal or posterior myoma, the incision must be vertical in line with the needle holder, which in this case will be in the suprapubic port so that the needle can be passed deeply in the myometrium (**Figs. 6–7**).

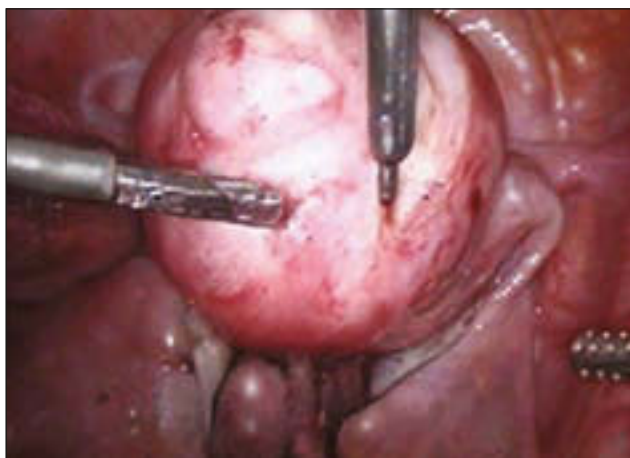

Fig. 4 Elliptical incision in a pedunculated myoma by use of a unipolar hook electrode (60-watt cutting current). An elliptical incision is advantageous because the very thin myometrium would be too difficult to suture.

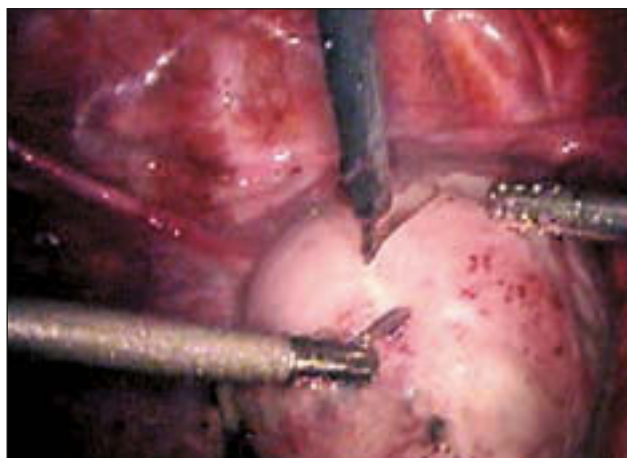

Fig. 5 Myometrial incision at the level of the most prominent part of the myometrium with a unipolar hook electrode using a 60-watt cutting current. The assistant is using a suction cannula to aspirate and maintain clear vision of the operating field.

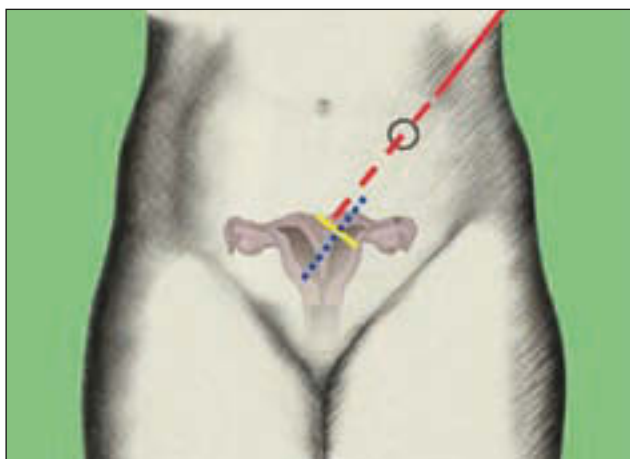


Fig. 6 Anterior myoma: the line of incision should be aligned on-axis with the needle holder placed in the lateral port.

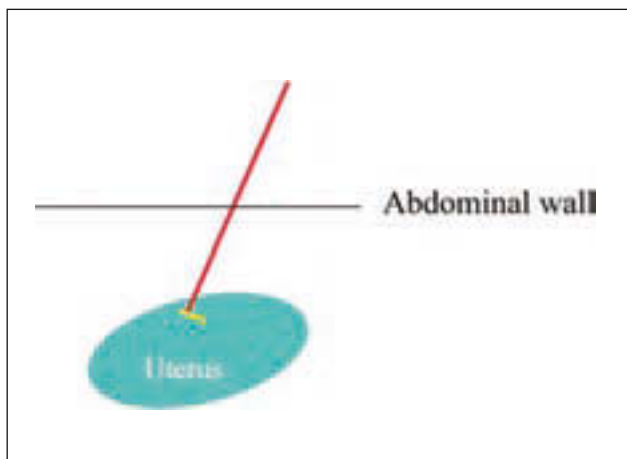


Fig. 7 Anterior myoma (lateral view): the incision cannot be aligned on-axis with the needle holder in the suprapubic port because the needle would not be able to penetrate deeply into the myometrium.

When placing the myometrial incision, the surgeon must limit the use of electrocautery. Many cases of uterine rupture after leiomyoma coagulation or simple unipolar cauterization have been reported. Bipolar electrosurgery may be applied selectively to the blood vessels. Hemostasis must be achieved preferably by means of endoscopic suture and the use of vasoconstrictive agents. The ultrasonic scalpel is used by some surgeons. *Stringer* was the first to use it for LM and its use for uterine incision appears to be as effective as the knife electrode; however, it appears to produce greater tissue damage compared to the unipolar mode using 35 watt for cutting and 30 watt for coagulation. We prefer to use a 30–60 watt unipolar hook electrode with unblended cutting current

producing a sharp and clean cut with minimal lateral diffusion of energy. In theory, the ideal choice would be a cold surgical knife. In the case of intraligamentary myomas, the first step is to incise the broad ligament to assist in spontaneous protrusion.

Pedunculated myomas are resected with unipolar scissors and then sutured like intramural or subserous myomas. An endloop positioned around the myoma pedicle can help to reduce bleeding before starting to suture.

However, we advise against only using two endloops because they slip off the pedicle easily, producing major secondary bleeding.

5.3 Enucleation of the Myoma

After identification of the cleavage plane, the myoma is enucleated, pulling it with a 10 mm tenaculum or spiral-tipped fixation instrument inserted through the suprapubic port, exerting countertraction and performing dissection with a sturdy forceps and with a suction cannula (**Figs. 8, 9**). Given proper identification and exposure of the cleavage planes, the myoma can be removed without any bleeding vessels. Traction should allow the myoma to be rotated toward the anterior abdominal wall (in the case of anterior myoma) so that the point of insertion of the fixation instrument should be as low as possible in the fibroid. Only significant bleeding is

coagulated with the bipolar forceps; hemostasis should be achieved by suture and vasoconstrictive agents. An effort must be made not to enter the endometrial cavity to avoid the formation of synechiae or iatrogenic adenomyosis. We do not recommend suture of the endometrial cavity to prevent adenomyosis as reported by *Koh*, but antibiotic prophylactic cover for two days and diagnostic hysteroscopy at the end of the operation are worthwhile. Small adjacent myomas can be enucleated by tunnelling through the previous incision (**Figs. 10, 11**) making sure that formation of hematomas is not facilitated.

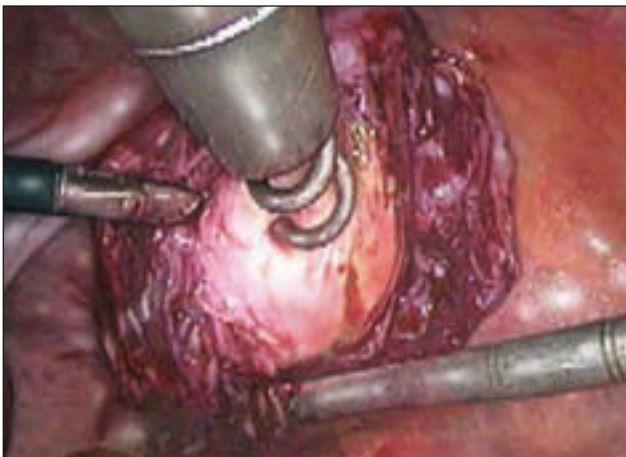


Fig. 8
Enucleation of the myoma. The myoma is enucleated by pulling and rotating the fibroid with a spiral-tipped fixation instrument inserted through the suprapubic port, applying countertraction and using blunt dissection with a strong forceps and a suction cannula. In the case of major bleeding, the surgeon may use the bipolar forceps.

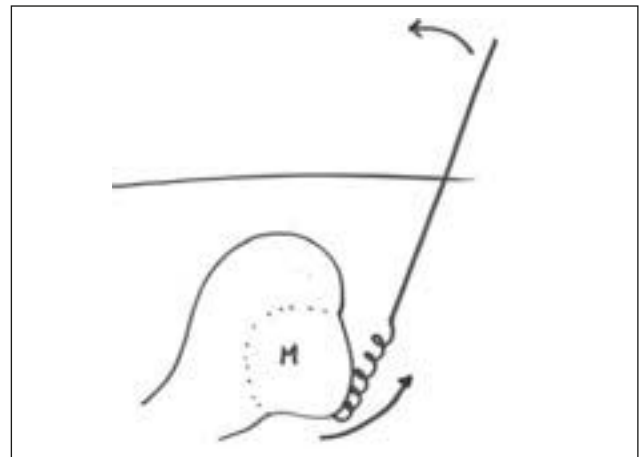
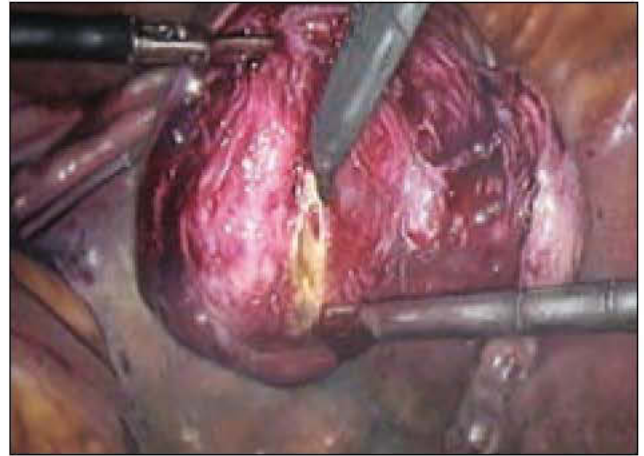
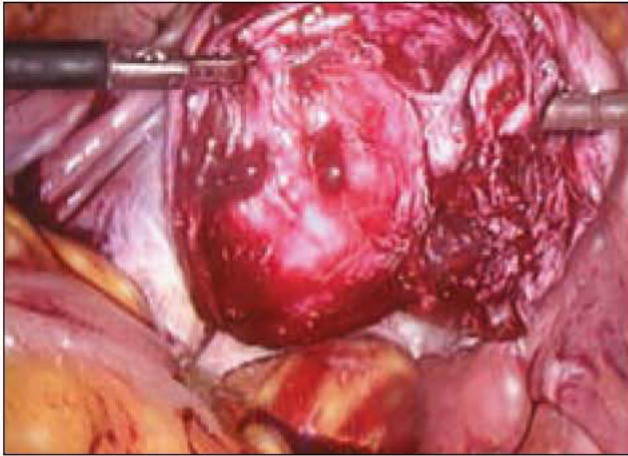


Fig. 9
The handle of the spiral-tipped fixation instrument is pulled towards the patient's feet along an imaginary arc so as to apply traction to the myoma.

**Figs. 10, 11**

A second myoma localized on the left side after removal of the first posterior intramural myoma. The pseudocapsule is incised in

the usual way and the myoma is enucleated with tunnelling through the previous incision.

5.4 Laparoscopic Suture

Continuous sutures, interrupted sutures, intracorporeal or extracorporeal knots can be used. We prefer to use 0 or 2/0 coated polyglycolic acid (Serafit) for large myomas because it is a suture that holds well with little memory compared to other braided synthetic sutures and is also coated and smooth without getting wet like a monofilament. However, for small myomas or to approximate the serosa a continuous PDS 0 or 2/0 suture may be used. The type of suture greatly influences the formation of postoperative adhesions. Fine and subserous sutures appear to be associated with a

lower incidence of adhesions. Data obtained from animal experiments suggest the need to invert the edges of the myometrial incision. The suture may consist of one to four layers to avoid hematoma formation inside the myometrium. During LM it is of great importance that good uterine integrity be restored to reduce to a minimum the risk of uterine rupture during delivery (**Tab. 1**), so accurate suture of the uterine defect is indispensable even in the case of superficial myomectomy (**Fig. 12**, p. 146).

References	Myoma Type	Myoma Size	Myoma Location	Hysterotomy Suture	Uterine Cavity Opened	Gestational Age	Vaginal Delivery	Pregnancy Outcome
<i>Harris '92</i>	NR	30	Posterior	Yes	NR	34	No	Good
<i>Dubuisson '95</i>	IM	30	Posterior	Yes	No	32	No	Good
<i>Mecke '95</i>	IM	NR	NR	NR	Yes	30	No	Good
<i>Friedman '96</i>	IM	50	Fundal	NR	Yes	28	No	Good
<i>Pelosi '97</i>	SS	50	Fundal	No	No	33	No	Death
<i>Foucher '00</i>	SS	3 x (3, 2, 1 cm)	Fundal	No	No	31	No (contractions)	Death
<i>Oktem '01</i>	SS	30x40	Cornual region	No	No	17	No	Death
<i>Hasbargen '02</i>	SS	2 x (0.7 x 1.2)	Posterior	No	No	29	No	Good
<i>Lieng '04</i>	Ped	4 cm	Posterior	No	No	35.5	No	Good

Tab. 1.

Published cases of uterine rupture after laparoscopic myomectomy.

Legend: NR = not reported; SS = subserous; IM = intramural; Ped = pedunculated

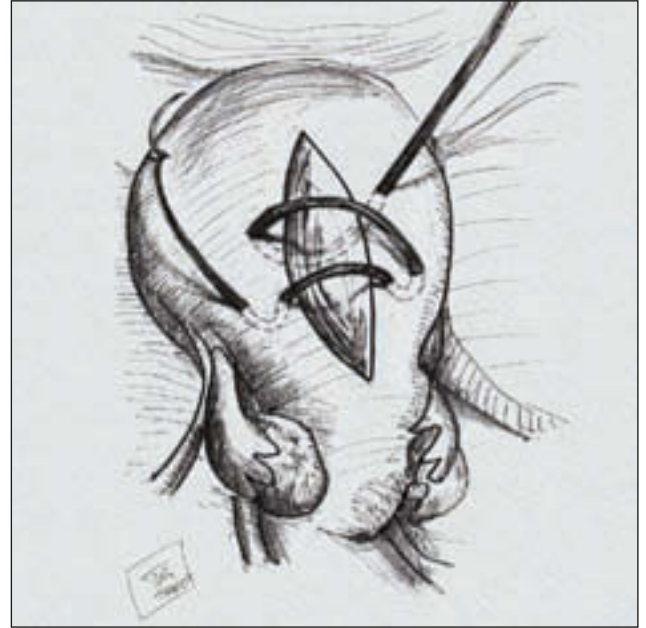
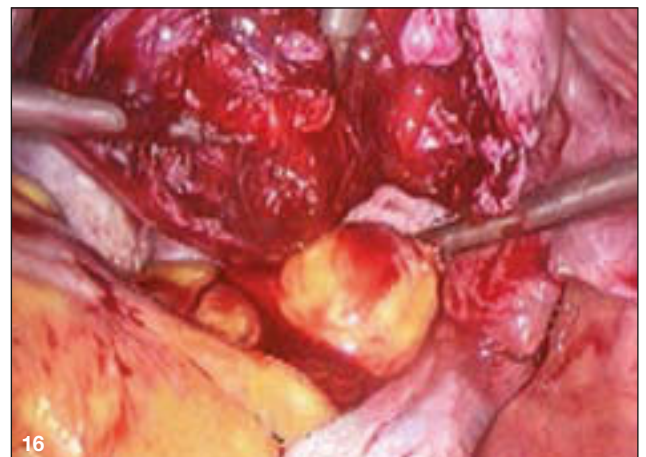
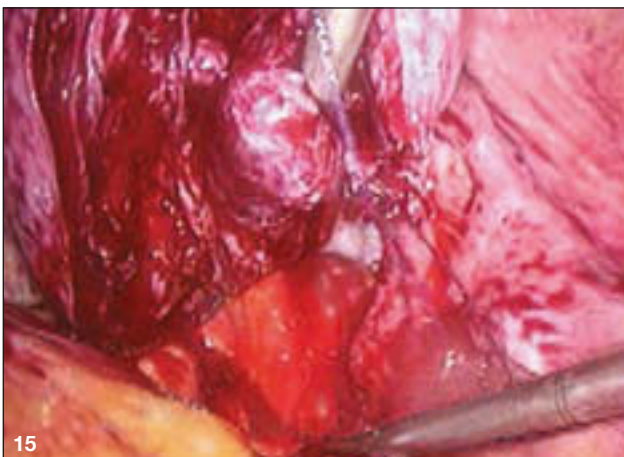
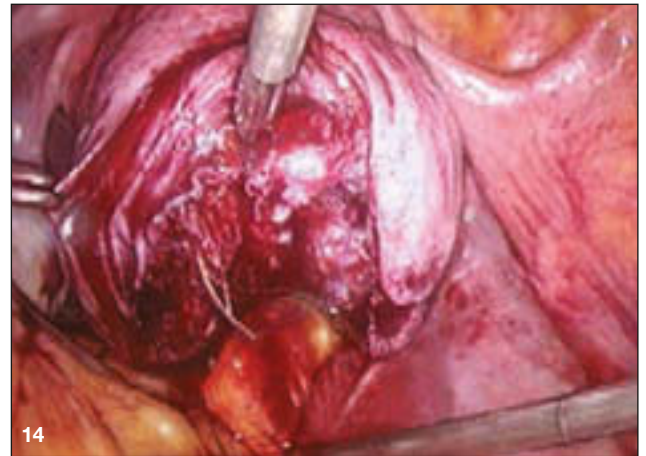
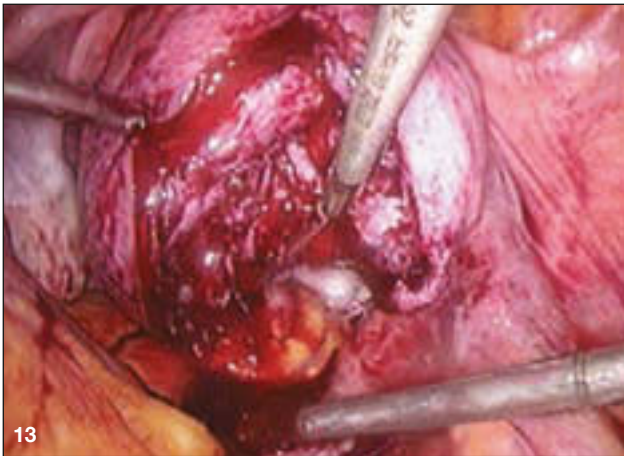


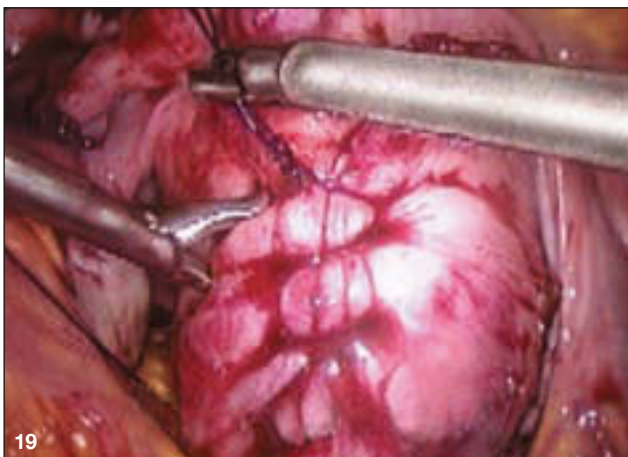
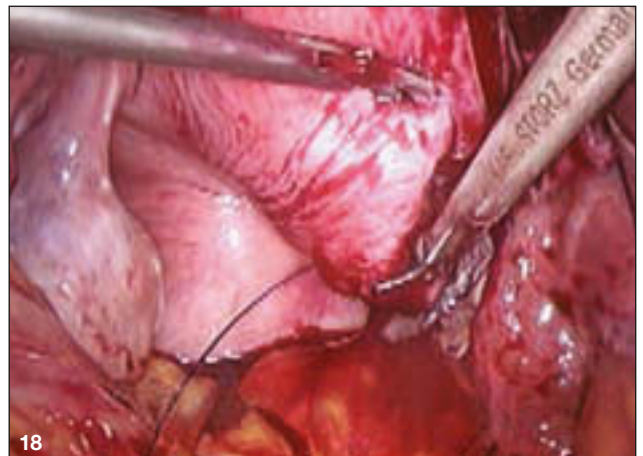
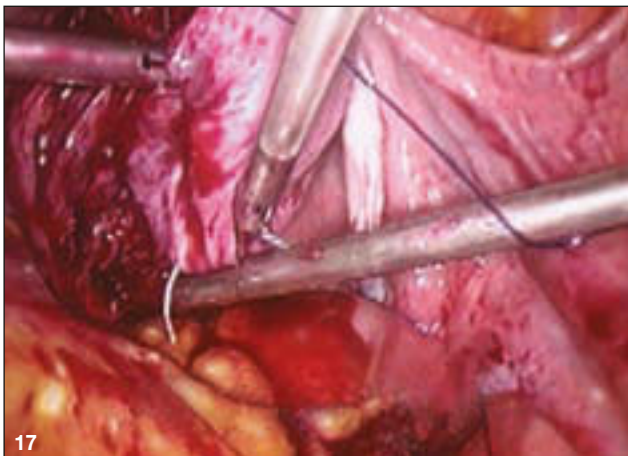
Fig. 12
Schematic drawing of a figure-of-eight zigzag suture that has proven effective and safe in our series. The suture line is usually placed with an intracorporeal knot.



Figs. 13–16
Interrupted figure of eight sutures with Serafit 0 are used to obliterate the bed of the myoma and ensure hemostasis.

As shown, each individual suture requires four steps starting from the right side and is then tied intracorporeally.

We use interrupted figure of eight sutures to approximate the bed of the myoma and ensure correct hemostasis (Figs. 13–16). The serosa is closed with a continuous inverting suture (Figs. 17–19) or interrupted inverting sutures. The sutures are placed with a 36 needle slightly straightened (maximum size of needle that can be introduced through a 15 mm trocar) or with a size 27 curved needle. If there is abundant myometrium, it is possible before closure to trim the excess to allow normal reconstruction of the uterus. However, since involution of the hypertrophic myometrium takes place spontaneously in the first weeks post myomectomy it is advisable to avoid removing myometrial tissue as much as possible.



Figs. 17–19

The superficial layer is approximated with a continuous inverting PDS 0 or 2/0 suture.

- inverting suture on the right side of the incision
- inverting suture on the left side
- final result

The assistant cuts the suture and the surgeon can remove the needle from the abdomen via the 15 mm subprapubic trocar.

5.5 Morcellation

Use of an electromechanical morcellator to remove the myomas is obligatory. We recommend activating the blade of the morcellator inside a trocar with an oblique end (Figs. 20, 21). In this way, with simple traction the myoma is “peeled” like an orange into a few or even no fragments.

This technique should prevent the “Swiss cheese” effect of perforating the myoma with a number of holes, loss of the fragments in the pelvis, repeated grasping of the myoma with forceps and thus loss of time.

5.6 End of the Procedure

The peritoneal cavity must be irrigated copiously with Ringer lactate to obtain correct hemostasis and remove all the fragments; leaving a small piece of myoma can cause

intestinal obstruction following formation of adhesions. A device to avoid the formation of adhesions is to suture the suprapubic fascial defect under vision.

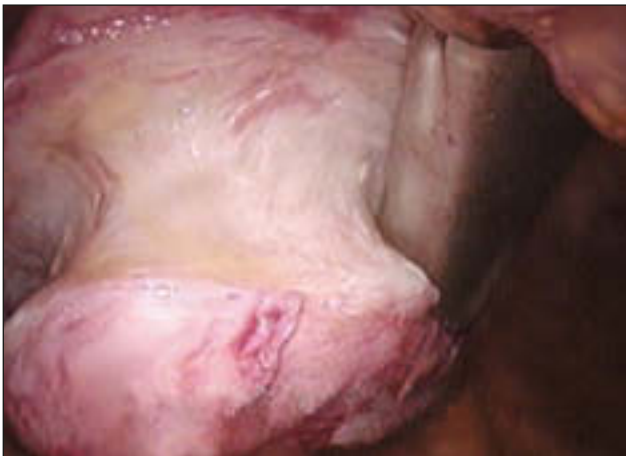

Fig. 20
Activation of the blade of the morcellator inside a trocar with an oblique end: the myoma is rotated and “peeled” like an orange without the aid of the assistant and with the production of very few fragments.

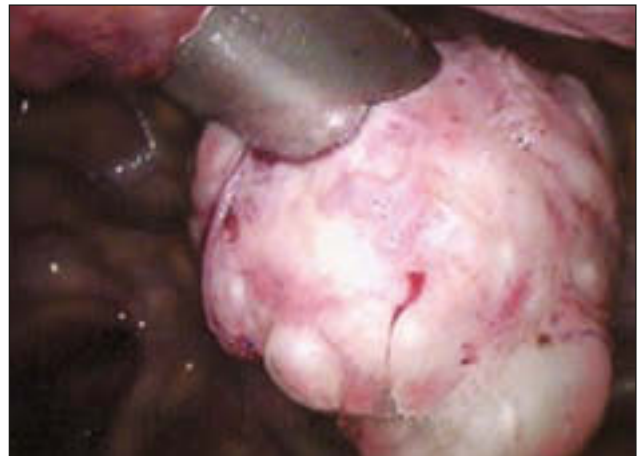

Fig. 21
Correct position of the blade relative to the end of the trocar: the blade must be in about the middle of the oblique part of the trocar.

Recommended Reading

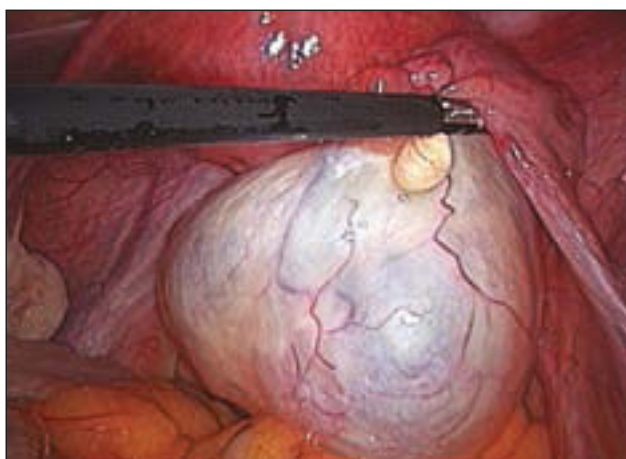
- ACIEN P, QUEREDA F: Abdominal myomectomy: Results of a simple operative technique. *Fertil Steril* 65:41-51, 1996
- ARCANGELI S, PASQUARETTE MM.: Gravid uterine rupture after myolysis. *Obstet Gynecol*. May;89 (5 Pt 2):857, 1997.
- BEYTH Y: Gonadotropin-releasing hormone analog treatment should not precede conservative myomectomy. *Fertil Steril* 53:187-188, 1990
- BULLETTI C, POLLI V, NEGRINI V, GIACOMUCCI E, FLAMIGNI C: Adhesion formation after laparoscopic myomectomy. *J Am Assoc Gynecol Laparosc*. Aug;3(4): 533-6, 1996.
- CAMPO S, GARCEA N: Laparoscopic myomectomy in premenopausal women with and without preoperative treatment using gonadotrophin-releasing hormone analogues. *Hum Reprod* 14(1):44-48, 1999
- COHEN D, MAZUR MT, JOZEFczyk MA, et al: Hyalinization and cellular changes in uterine leiomyomata after gonadotropin-releasing hormone against therapy. *J Reprod Med* 39:377-380, 1994
- DARAI E, DECHAUD H, BENIFLA JL, ET AL: Fertility after laparoscopic myomectomy: Preliminary results *Hum Reprod* 12(9):1931-1934, 1997
- DELIGDISCH L, HIRSCHMANN S, ALTCHek A: Pathologic changes in gonadotropin releasing hormone agonist analogue treated uterine leiomyomata. *Fertil Steril* 67:837-841, 1997
- DUBUISSON JB, CHAPRON C, CHAVET X, et al: Fertility after laparoscopic myomectomy of large intramural myomas, preliminary results. *Hum Reprod* 11(3):518-522, 1996
- DUBUISSON JB, CHAVET X, CHAPRON C, et al: Uterine rupture during pregnancy after laparoscopic myomectomy. *Hum Reprod* 10:1475-1477, 1995
- DUBUISSON JB, FAUCONNIER A, CHAPRON C, KREIKER G, NORGAARD C.: Second look after laparoscopic myomectomy. *Hum Reprod*. Aug; 13 (8):2102-6, 1998.
- DUNNIHOO DR, OTTERSON WN, MAILHES JB, LEWIS DF JR, GRAFTON WD, BROWN CC.: An evaluation of uterine scar integrity after cesarean section in rabbits. *Obstet Gynecol*. Mar;73(3 Pt 1):390-4, 1989.
- FELBERBAUM RE, KUPKER W, KRAPP M, GEHL B, LUDWIG M, DIEDRICH K: Preoperative reduction of uterine fibroids in only 16 days by administration of a gonadotrophin-releasing hormone antagonist (Cetrotide). *Reprod Biomed Online*.;3(1):14-18, 2001.
- FREDERICK J, FLETCHER H, SIMEON D, MULLINGS A, HARDIE M: Intramyometrial vasopressin as a haemostatic agent during myomectomy. *Br J Obstet Gynaecol*. May;101(5):435-7, 1994.
- FRIEDMAN W, MAIER RF, LUTTKUS A, et al: Uterine rupture after laparoscopic myomectomy. *Acta Obstet Gynecol Scand* 75:683-684, 1996
- GEORGAKOPULOS PA, BERCI G: Sigmoido-uterine rupture in pregnancy after multiple myomectomy. *Int Surg* 66:367-368, 1981
- HARRIS WJ: Uterine dehiscence following laparoscopic myomectomy. *Obstet Gynecol* 80:545-546, 1992
- HASSON HM, ROTMAN C, RANA N, SISTOS F, DMOWSKI WP: Laparoscopic myomectomy. *Obstet Gynecol*. Nov;80(5):884-8, 1992.
- IGARASHI M: Value of myomectomy in the treatment of infertility. *Fertil Steril*. Jun;59(6):1331-2, 1993
- KIMURA T, KUSUI C, MATSUMURA Y, OGITA K, ISAKA S, NAKAJIMA A, OHASHI K, KOYAMA M, AZUMA C, MURATA Y: Effectiveness of hormonal tourniquet by vasopressin during myomectomy through vasopressin V1a receptor ubiquitously expressed in myometrium. *Gynecol Obstet Invest*. 54(3):125-31, 2002.
- KOH C, JANIK G: Laparoscopic myomectomy: the current status *Curr Opin Obstet Gynecol*, 15:295-301, 2003
- KWOK A, NEVELL D, FERRIER A, GRAF N, LAM A, FORD R: Comparison of tissue injury between laparoscopic coagulating shears and electrosurgical scissors in the sheep model. *J Am Assoc Gynecol Laparosc*. Aug;8(3):378-84, 2001.
- LETHABY A, VOLLENHOVEN B, SOWTER M: Pre-operative GnRH analogue therapy before hysterectomy or myomectomy for uterine fibroids. *Cochrane Database Syst Rev*. (2):CD000547, 2000.
- LIN PC, THYER A, SOULES MR.: Intraoperative ultrasound during a laparoscopic myomectomy. *Fertil Steril* Jun;81(6):1671-4, 2004.
- LOONG EPL, WONG FWS: Uterine leiomyosarcoma diagnosed during treatment with an agonist of luteinizing hormone-releasing hormone for presumed uterine fibroid. *Fertil Steril* 54:530-531, 1990
- MAIS V, AJOSSA S, GUERRIERO S, et al: Laparoscopic versus abdominal myomectomy: A prospective, randomized trial to evaluate benefits in early outcome. *Am J Obstet Gynecol* 174:654-658, 1996
- NEZHAT C, NEZHAT F, SILFEN SL, SCHAFFER N, EVANS D: Laparoscopic myomectomy. *Int J Fertil* 36:275-280, 1991
- NEZHAT CH, NEZHAT F, ROEMISCH M, et al: Pregnancy following laparoscopic myomectomy: Preliminary results. *Hum Reprod* 14(5):1219-1221, 1999
- NEZHAT F, ROEMISCH M, NEZHAT CH, et al: Recurrence rate after laparoscopic myomectomy. *J Am Assoc Gynecol Laparosc* 5(3):237-240, 1998
- NEZHAT F, SEIDMAN DS, NEZHAT C, et al: Laparoscopic myomectomy today: Why, when and for whom? *Hum Reprod* 11(5):933-937, 1996

31. NKEMAYIM DC, HAMMADEH ME, HIPACH M, MINK D, SCHMIDT W: Uterine rupture in pregnancy subsequent to previous laparoscopic electromyolysis. Case report and review of the literature. *Arch Gynecol Obstet.* Nov;264(3):154-6, 2000.
32. OSTRZENSKI A.: Uterine leiomyoma particle growing in an abdominal-wall incision after laparoscopic retrieval. *Obstet Gynecol.* May;89(5 Pt 2):853-4, 1997.
33. OU CS, HARPER A, LIU YH, ROWBOTHAM R: Laparoscopic myomectomy technique. Use of colpotomy and the harmonic scalpel. *J Reprod Med.* Oct;47(10):849-53, 2002.
34. PALOMBA S, PELLICANO M, AFFINITO P, DI CARLO C, ZULLO F, NAPPI C: Effectiveness of short-term administration of tibolone plus gonadotropin-releasing hormone analogue on the surgical outcome of laparoscopic myomectomy. *Fertil Steril.* Feb;75(2): 429-33, 2001.
35. PELERME GR, FRIEDMAN EA: Rupture of the gravid uterus in the third trimester. *Am J Obstet Gynecol* 94:571-576, 1996
36. PELOSI MAIII, PELOSI MA: Spontaneous uterine rupture at thirty-three weeks subsequent to previous superficial laparoscopic myomectomy. *Am J Obstet Gynecol* 177:1547-1549, 1997
37. RIBEIRO SC, REICH H, ROSENBERG J, GUGLIELMINETTI E, VIDALI A.: Laparoscopic myomectomy and pregnancy outcome in infertile patients. *Fertil Steril.* 1999 Mar;71(3):571-4.
38. ROSSETTI A, PACCOSI M, SIZZI O, ZULLI S, MANCUSO S, LANZONE A: Dilute ornitin vasopressin and a myoma drill for laparoscopic myomectomy. *J Am Assoc Gynecol Laparosc.* May;6(2):189-93, 1999.
39. ROSSETTI A, SIZZI O, SORANNA L, CUCINELLI F, MANCUSO S, LANZONE A: Long-term results of laparoscopic myomectomy: recurrence rate in comparison with abdominal myomectomy. *Hum Reprod.* Apr;16(4):770-4, 2001.
40. ROSSETTI A, SIZZI O, SORANNA L, MANCUSO S, LANZONE A: Fertility outcome: long-term results after laparoscopic myomectomy. *Gynecol Endocrinol.* Apr;15(2):129-34, 2001
41. LANDI S, FIACCAVENTO A, ZACCOLETTI R, BARBIERI F, SYED R, MINELLI L: Pregnancy Outcomes and Deliveries after Laparoscopic Myomectomy. *J Am Assoc Gynecol Laparosc* 10(2):177-181, 2003
42. S. LANDI, R. ZACCOLETTI, L. FERRARI, L. MINELLI: Laparoscopic Myomectomy: Technique, Complications, and Ultrasound Scan Evaluations. *J Am Assoc Gynecol Laparosc* 8(2):231-240, 2001
43. SEINERA P, ARISIO R, DECKO A, et al: Laparoscopic myomectomy: Indications, surgical technique and complications. *Hum Reprod* 12:1927-1930, 1997
44. SEINERA P, GAGLIOTI P, VOLPI E, et al: Ultrasound evaluation of uterine wound healing following laparoscopic myomectomy: Preliminary results. *Hum Reprod* 14(10):2460-2463, 1999
45. SERACCHIOLI R, ROSSI S, GOVONI F, ROSSI E, VENTUROLI S, BULLETTI C, FLAMIGNI C: Fertility and obstetric outcome after laparoscopic myomectomy of large myomata: a randomized comparison with abdominal myomectomy. *Hum Reprod.* Dec; 15(12): 2663-8, 2000.
46. SORIANO D, DESSOLLE L, PONCELET C, BENIFLA JL, MADELENAT P, DARAI E: Pregnancy outcome after laparoscopic and laparoconverted myomectomy. *Eur J Obstet Gynecol Reprod Biol.* Jun 10; 108(2): 194-8, 2003.
47. STEINAUER J, PRITTS E, JACKSON R, JACOBY A: Systematic review of Mifeprisone for the treatment of uterine myoma. *Obstet Gynecol,* 10: 1331-6, 2004
48. STRINGER NH, WALKER JC, MEYER PM: Comparison of 49 laparoscopic myomectomies with 49 open myomectomies. *J Am Assoc Gynecol Laparosc.* Aug; 4(4):457-64, 1997.
49. SWEETEN KM, GRAVES WK, ATHANASSIOU A.: Spontaneous rupture of the unscarred uterus. *Am J Obstet Gynecol.* Jun;172(6):1851-5, 1995
50. TAKEUCHI H, KINOSHITA K: Evaluation of adhesion formation after laparoscopic myomectomy by systematic second-look microlaparoscopy. *J Am Assoc Gynecol Laparosc* 9:442-446, 2002
51. TULANDI T, BEIQUE F, KIMIA M: Pulmonary edema: A complication of local injection of vasopressin at laparoscopy. *Fertil Steril* 66:478-480, 1996
52. VILOS GA, DALY LJ, TSE BM: Pregnancy outcome after laparoscopic electromyolysis. *J Am Assoc Gynecol Laparosc* 5: 289-292, 1998
53. ZIMBRIS L, HEDON B, LAFRARGUE F: Myomectomie par coelioscopie. *J Obstet Gynecol* 2:219-223, 1994
54. ZULLO F, PALOMBA S, COREA D, PELLICANO M, RUSSO T, FALBO A, BARLETTA E, SARACO P, DOLDO P, ZUPI E: Bupivacaine plus epinephrine for laparoscopic myomectomy: a randomized placebo-controlled trial. *Obstet Gynecol.* Aug;104(2):243-9, 2004
55. ZULLO F, PELLICANO M, DE STEFANO R, et al: A prospective randomized study to evaluate leuprolide acetate treatment before laparoscopic myomectomy: Efficacy and ultrasonographic predictors. *Am J Obste Gynecol* 178:108-112, 1998

Chapter XIII

Laparoscopic Treatment of Adnexal Masses

Mario Malzoni and Fabio Imperato
Malzoni Medical Center “Villa dei Platani”
Avellino, Italy



1.0 Introduction

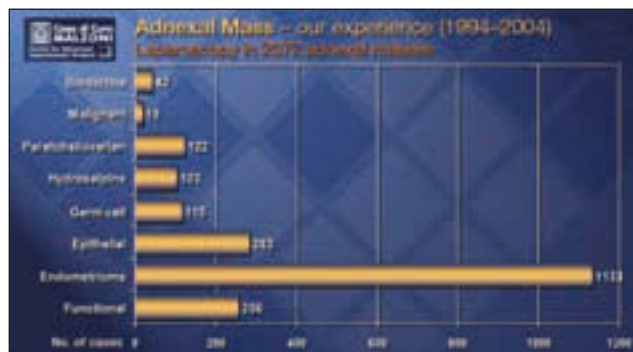In recent years, minimally invasive laparoscopic surgery has changed the therapeutic management of adnexal masses to such an extent, that it can be considered the standard therapeutic option.

Despite several very promising publications suggesting the increasing diagnostic value of ultrasonography and color Doppler, the preoperative diagnosis of malignant lesions provides too many false-positive results. Laparoscopy is of significant value in the diagnostic assessment of adnexal masses in that it allows for elective biopsy and histopathologic evaluation including the option of ovarian tumor removal.

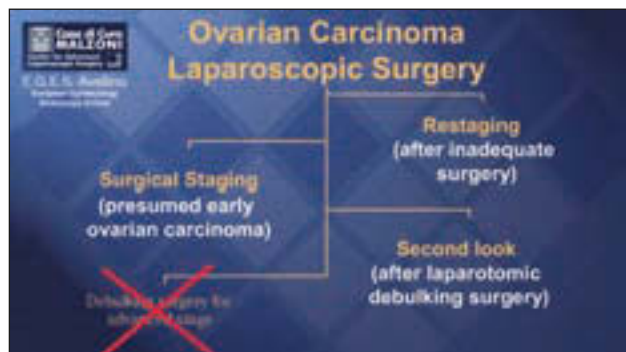However, the rate of confirmed malignancy in patients with adnexal masses ranges from 0.3 to 1.2% (**Tab. 1**) and the publication of case histories describing undetected ovarian cancers treated via laparoscopy has given rise to criticism

of this type of procedure. In fact, accidental rupture of the thin ovarian cyst capsule in patients with missed diagnosis of proven malignancy can involve intraoperative spillage of tumor cells. The objection to laparoscopic surgery for ovarian tumors is based on the hypothesis, that a missed stage IA ovarian cancer could transform into a stage IC tumor (FIGO classification) which would require adjunctive chemotherapy.

However, does the incidence of intraoperative spillage constitute a prognostic risk factor that could adversely affect the patient's survival? In patients with stage I ovarian cancer, some authors consider that this risk factor is not significant compared to others, e.g., the histological tumor type. According to other authors, spillage does not seem to adversely affect the patient's prognosis provided that copious lavage is performed and the patient is treated by surgery within a week of the laparoscopy.



Tab. 1
Diagram showing the experience of the authors with laparoscopic management of adnexal masses.



Tab. 2
Laparoscopic management of ovarian cancer.

2.0 Indications

It is very difficult to define the limits of laparoscopic surgery. A few authors state that laparoscopic management is indicated only for adnexal masses that present without any signs of malignancy, while for other study groups, this can include ovarian cancer at an early stage. An expert laparoscopist, after diagnosing that the lesion is malignant, could stage the

tumor laparoscopically completely without compromising the extent (**Tab. 2**).

In our experience, nearly all adnexal masses can be treated laparoscopically. This is because of the method's dual role: diagnostic and therapeutic.

2.1 Functional Ovarian Cysts

Functional ovarian cysts tend to undergo spontaneous or drug-induced remission (suppressive hormonal therapy) within 8 weeks. Persistence of the cysts is an indication for laparoscopy.

Follicular Cysts

These develop because of accumulation of follicular liquid following distention of a Graafian follicle. They vary in size up to a diameter of 5–6 cm (< 10 cm) and are unilateral, unilocular and thin-walled. They are characterized by a smooth outer surface, which is translucent and whitish-gray in color (**Fig. 1**). The contents are lemon yellow in color. The internal surface is smooth and shiny and greyish in color.

Corpus luteum Cysts

These are due to fluid collection inside the corpus luteum at the end of ovulation (**Fig. 2**). They are roundish cystic swellings, which rarely exceed 4 cm in diameter. The outer surface is yellowish in color. The serous-hemorrhagic contents vary in color from brownish red, if recent, to serous when they are older. The internal surface is smooth, sometimes with remnants of adherent fibrous blood clots. They nearly always undergo spontaneous regression. In these cases, a corpus albicans cyst can be seen on the surface of the ovary, consisting of fibrous collagen.

2.2 Epithelial Cysts

Serous Cysts

These are the most frequent of all benign ovarian cysts, and are predominantly unilateral and unilocular with thin, smooth walls. Their diameter is usually less than 15 cm. The outer translucent surface is covered with a fine vascular network (Fig. 3). The internal surface can appear smooth and shiny (simple cystadenoma) or projecting as papillary structure (papillary cystadenoma). Sometimes, the outer surface also has numerous papillary proliferations (surface papilloma of the ovary). If the serous epithelium has an abundant stromal component, that is, at least a quarter of the tumor mass is solid and fibromatous, this is called a cystadenofibroma.

Mucinous Cysts

Less frequent than the previous ones, they are usually unilateral, pedunculated and thus very mobile with a diameter that can reach 30–50 cm or even more (giant cystadenomas). They are usually multilocular with cystic cavities of varying sizes, separated by fine fibrous septa, complete and incomplete (Fig. 4). The contents are usually fluid, mucinous, clear and fibrous.

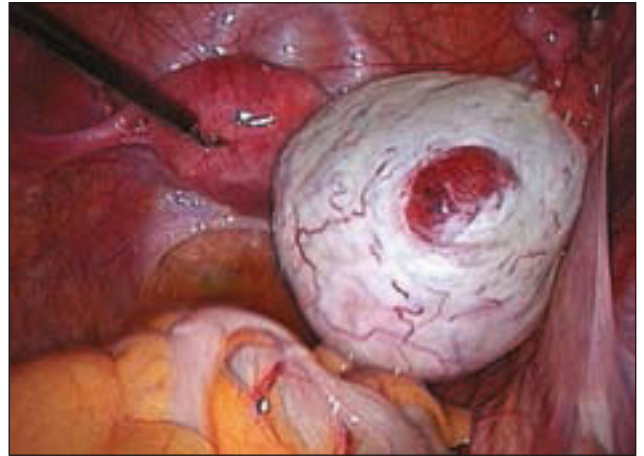

Fig. 1
Functional ovarian cyst.

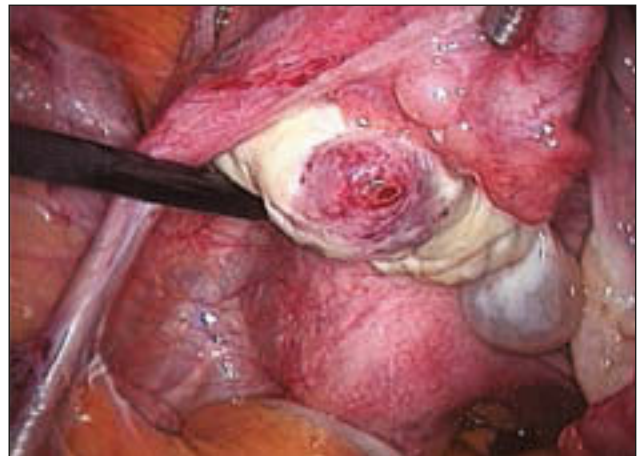


Fig. 2
Corpus luteum.

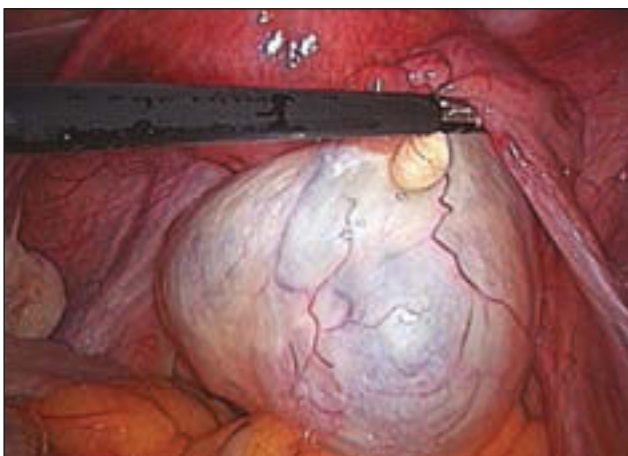


Fig. 3
Serous ovarian cyst.

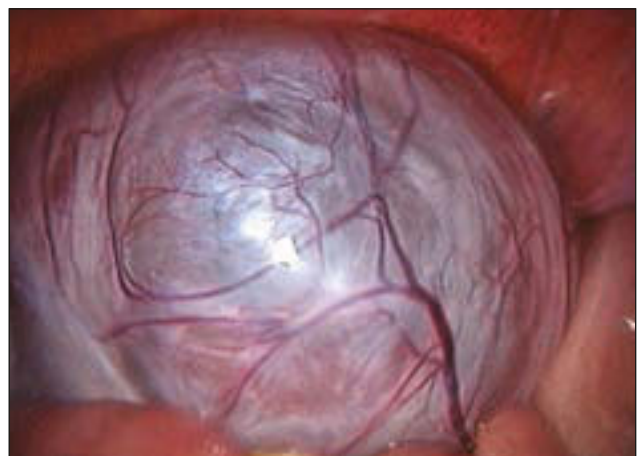

Fig. 4
Mucinous ovarian cyst.

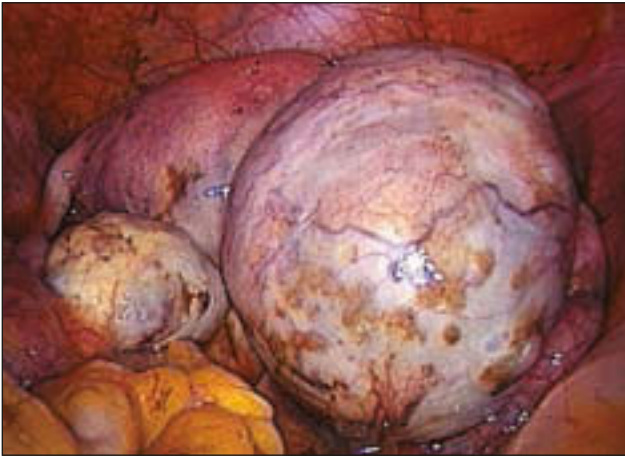

Fig. 5
Endometrioma.

Endometriomas

These are due to endometriosis located on the ovary; please refer to the specific chapter regarding management. The outer surface is irregular and yellowish white with numerous areas of dark brown (**Fig. 5**). The bloody contents make them difficult to distinguish from functional hemorrhagic cysts.

2.3 Germinal Cysts

Dermoid Cysts

Typically, they are found with a higher frequency in young women presenting as cystic swellings with a doughy consistency, yellowish white in color and opaque. They are filled with fatty, semisolid, sebaceous material mingled with hairs and/or skin, bone, cartilage, and all tissues deriving from the three embryonic (ectodermal, mesodermal and endodermal) layers can be present. They are usually thick-walled and 6–10 cm in diameter, but can reach 15 cm (**Fig. 6**). Dissection of dermoid cysts is usually attempted while preserving the integrity of the cystic capsule. If accidental rupture and ensuing spillage of the cyst contents into the peritoneal cavity occurs, it is necessary to remove the spilled material carefully (sebum, hairs, etc.) to prevent the incidence of chemical peritonitis.

Ovarian Struma

These are usually unilateral and multilocular, with a diameter of 6–8 cm. The contents are colloidal. They consist of highly specialized mature thyroid tissue.

2.4 Inclusion Cysts

Parovarian / Tubal Cysts

These intraligamentous cysts, which develop between the leaves of the broad ligament, can reach a considerable size and can deform the adjacent tube. On the other hand, the ovary appears healthy. They usually arise from embryonic remnants of the mesonephric or wolffian system (primitive kidney), present in the thickness of the broad ligament. More specifically, they derive in the majority of cases from the cranial part of the mesonephric system close to the ovarian hilum (epoophoron or parovarium), rarely from the caudal part of the mesonephric system immediately below the point of insertion of the utero-ovarian ligament (paroophoron). They appear as cystic unilateral and unilocular thin-walled swellings, ovoid or roundish in shape, sometimes of considerable size, containing clear fluid (**Fig. 7**).

Their removal requires careful dissection to avoid iatrogenic injuries to the ureter and uterine pedicle, which may have been displaced by the cyst and have an atypical course. It is therefore advisable to identify both structures.

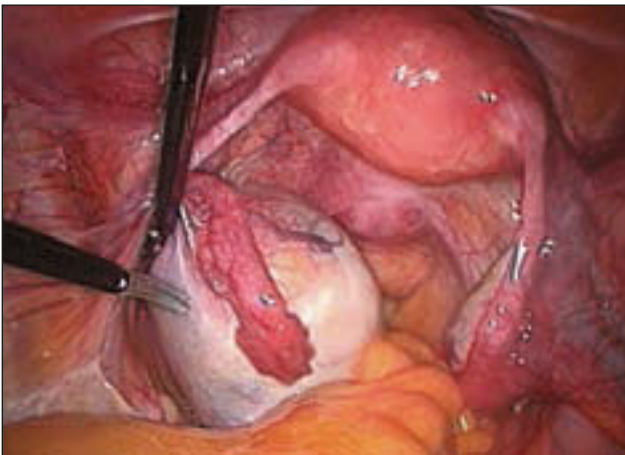


Fig. 6
Ovarian dermoid cyst or mature teratoma.

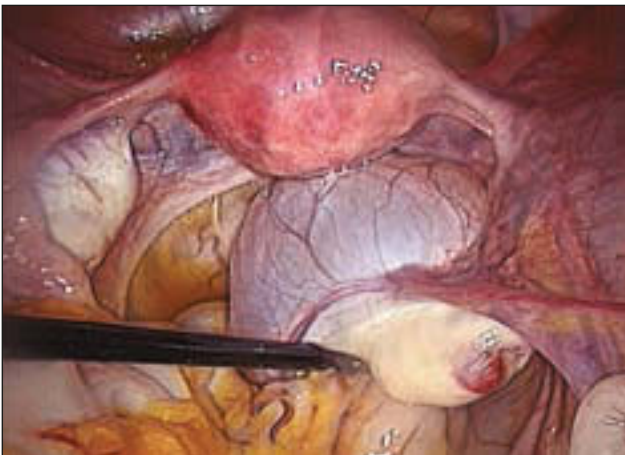


Fig. 7
Parovarian cyst.

The peritoneum is incised with Metzenbaum scissors in an area distant from the tube (**Fig. 8**). The margin of the peritoneal incision is grasped with a fine grasping forceps and the layer of cleavage between the peritoneum and the cyst is identified. Then, the cyst is dissected bluntly from the loose connective tissue with the scissors by opening and closing the blades.

2.5 Inflammatory Cysts

Pyosalpinx

This is a collection of purulent exudate in the lumen of the uterine tube due to complete occlusion of its ostium as a result of purulent salpingitis. The tube appears considerably distended, full of a thick creamy exudate that is greenish yellow in color. The tubal wall is usually thickened and closely adherent to adjacent organs.

Hydrosalpinx

This is a collection of serous fluid in the lumen of the uterine tube because of complete occlusion of its distal ostium as a result of a weak and/or chronic inflammatory tubal process. The tube appears distended and full of clear fluid, 2–5 cm in diameter, with a smooth pinkish white surface and thin, transparent walls (**Fig. 9**). In the presence of hydrosalpinx, the outcomes of reconstructive surgery performed by laparoscopic approach are not encouraging in terms of pregnancy rate. Therefore, in these cases, an assisted reproduction technology (ART) program is the method of choice. In fact, in the decision-making process, whether or not to refer the patient to an ART program, some authors suggest removing the affected tube as a prophylactic measure, performing salpingectomy (**Fig. 10**) or alternatively, cauterizing the intramural and isthmic tubal portion.

Tubo-Ovarian Abscess (TOA)

The infectious process presents with a collection of purulent exudate involving the tube and nearby ovary as a result of salpingo-oophoritis. It usually originates from chronic and advanced stages of salpingitis. In patients with TOA, the adnexae assume the appearance of a complex mass, in which it is no longer possible to distinguish the two adjacent organs, which is why a single swelling, irregularly elongated and red-brown in color (**Fig. 11**) is visible at laparoscopy.

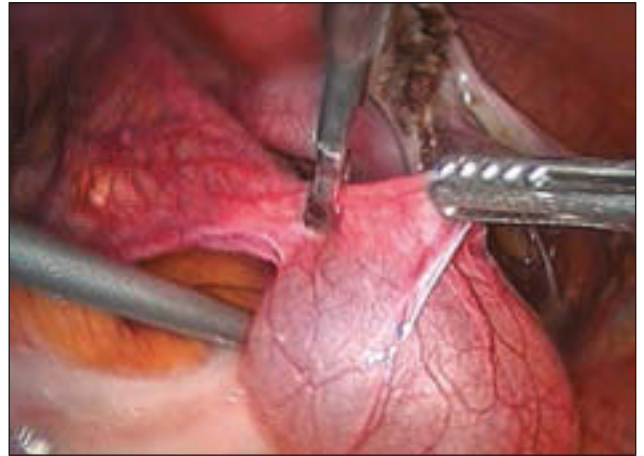


Fig. 8
Visualization of the peritoneum to be incised for removal of the paratubal cyst.

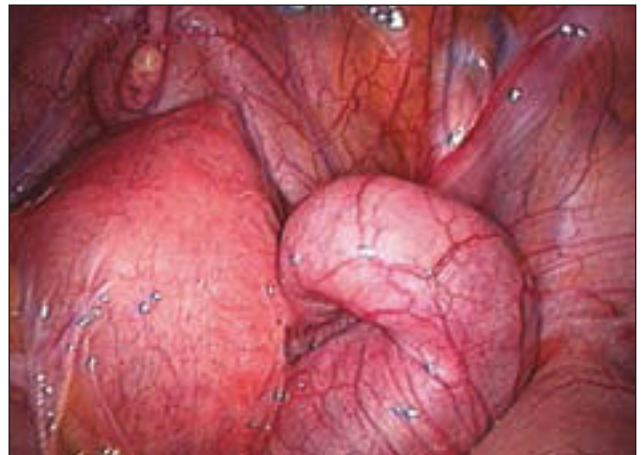


Fig. 9
Hydrosalpinx.

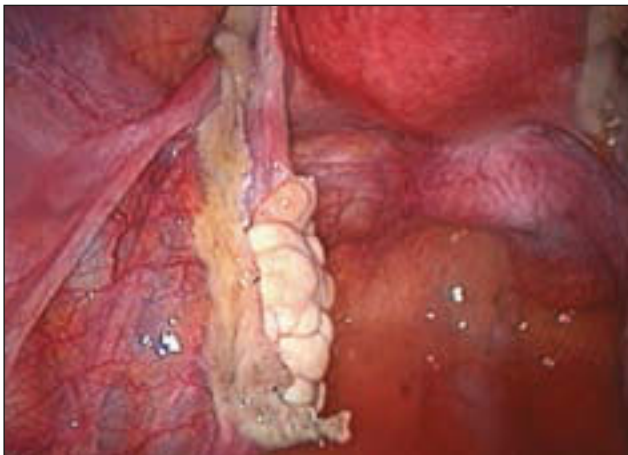

Fig. 10
Left salpingectomy.

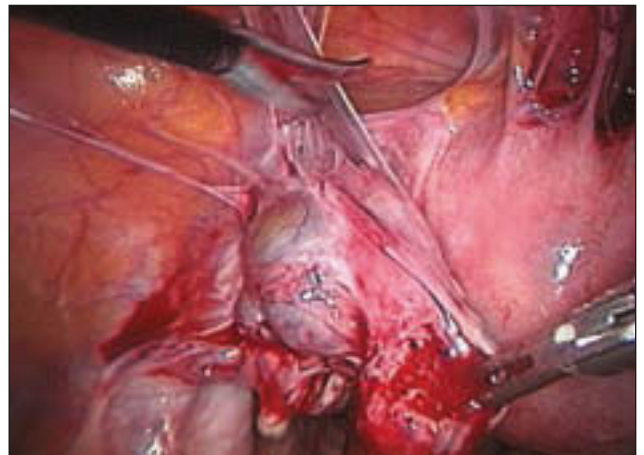


Fig. 11
Tubo-ovarian abscess.

Laparoscopic management of TOA involves aspiration and drainage of all purulent collections of the mass. A sample of the material is sent for bacteriological work-up. Next, the abdominal and pelvic cavities are carefully irrigated with saline. Adhesiolysis is performed to release the reproductive organs from the inflammatory process. At this point, the case is evaluated clinically and a decision is made on how to proceed. At times, it is sufficient simply to eliminate the source of infection, but other times an organ-preserving approach is not feasible. In this case, it is mandatory that adnexectomy be performed. Finally, intraperitoneal tube drains are placed.

2.6 Solid Ovarian Masses

Ovarian Fibroma

This is the most frequent connective-tissue tumor (5%) growing from the ovarian cortex. It affects mainly women over 40 years of age, with a mean of 55 years. Generally unilateral, it appears as a solid or mixed solid-cystic mass and is mobile and sometimes pedunculated. The outer surface can be both smooth and nodular and appears brownish white in color. It is often associated with ascites or ascites and pleural effusion (Demos-Meigs syndrome) which regresses after surgical removal.

3.0 Diagnosis

Before a patient undergoes laparoscopic surgical treatment of an adnexal mass, it is necessary to exclude the presence of cancer. Nonetheless, laparoscopic inspection alone of the adnexae often allows the surgeon to make a benign-malignant differentiation (Fig. 12).

3.1 History

The physician must ask the woman about any menstrual irregularities and the presence of any urinary or bowel disturbances.

Pelvic pain is the most frequent symptom although asymptomatic patients are not rare. In fact, it is only when the cysts reach a considerable size and produce pain in the ipsilateral iliac fossa that they become apparent and spur the patient to consult a doctor.

Rarely, the pelvic pain can present as an acute abdomen, secondary to rupture of a cyst or ovarian torsion.

3.2 Clinical Examination

Before the procedure, a local physical examination is carried out. The adnexa or adnexae may be tender to both superficial and deep palpation. Deep palpation reveals the outline, consistency, increased volume and mobility of the adnexal mass.

3.3 Transvaginal Ultrasound

Transvaginal ultrasound contributes greatly to the preoperative assessment of an adnexal mass.

Ovarian Torsion

Torsion of the adnexa at the site of its pedicle is a surgical emergency. It is more frequently found in an ovary with concomitant cyst formation. In patients with suspected ovarian torsion, and if diagnostic confirmation can be provided promptly, the immediate therapeutic management involves detorsion of the pedicle for restoration of normal anatomical conditions. After surgical detorsion, the ovary is inspected to confirm that blood flow has been re-established and the organ has regained its normal color.

Benign Brenner Tumor

This surface epithelial-stromal tumor of transitional cells (resembling urinary bladder epithelium) is of very rare occurrence; it affects mainly women in the fifth and sixth decade. Usually unilateral, it appears as a solid, hard and encapsulated mass. The outer surface is greyish white in color. Complete surgical excision of the benign Brenner tumor appears to be curative.

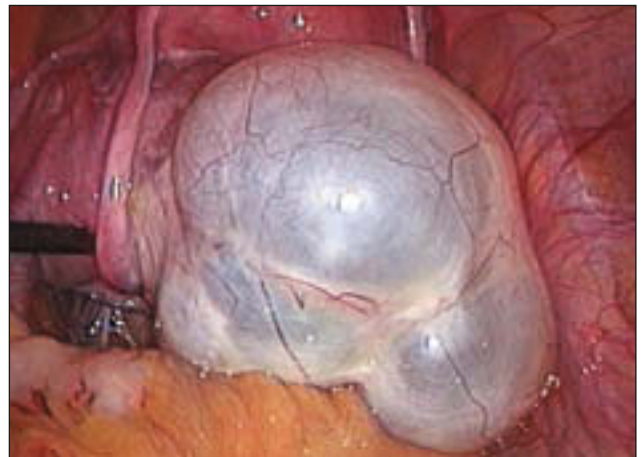


Fig. 12
Multilocular ovarian cyst.

In advanced malignant disease, patients complain of abdominal distension, swelling, constipation, nausea and anorexia.

Benign Adnexal Mass

It can be considered benign when a unilateral, mobile swelling with a smooth surface is found on examination.

Adnexal Mass Suspicious for Malignancy

A fixed mass with irregular margins, possibly bilateral, raises the suspicion of a malignant ovarian neoplasm.

Benign Adnexal Mass

The ultrasonic characteristics that suggest a benign nature of the lesion include: size < 6 cm, unilocular structure, homogeneous contents, absence of internal proliferations and

septa (possibly thin ones, < 2-3 mm), presence of smooth walls and well-defined margins. Dermoid cysts can contain hyperechogenic structures such as bone and cartilage. Hemorrhagic cysts can contain internal echoes of variable intensity, both focal and diffuse.

3.4 Color Doppler

Recently, use of color Doppler has made it possible to visualize the vascular patterns of adnexal masses based on the pathophysiological reasoning that malignant tumors are characterized by rapid growth and contain new vessels. The muscle layer of the walls of these vessels is reduced so resistance to blood flow is low. Quantification of the blood flow impedance and the presence, distribution and architecture of neovascularization inside the adnexal mass can be utilized in the differential diagnosis of these lesions. However, color Doppler studies can give false-negative results due, for example, to areas of avascular necrosis in malignant tumors. Conversely, complex adnexal masses with a solid and vascularized part (dermoid cysts, Brenner tumors) can give false-positive results.

3.5 Tumor Markers

Prior to the surgical procedure, specific tumor markers should be measured: CEA, CA 19-9, CA 125, aFP. Because of their low specificity and sensitivity, the tumor markers may only be used as an adjunct measure for predictive purposes that can help to differentiate benign from malignant adnexal masses.

3.6 CT and MRI

Adjunctive imaging modalities are often used in an attempt to improve diagnosis. However, measurement of CA 125 serum levels, transvaginal ultrasound and color Doppler have an acceptable sensitivity and specificity, so that additional

3.7 Intra-operative Assessment

Laparoscopic findings suspicious for malignancy are papillary and/or solid lesions on the outer surface of the

Adnexal Mass Suspicious for Malignancy

The presence of bilateral masses with irregular margins, multiple thick intracyst septa (> 4 mm), papillary projections, solid areas and the presence of ascites raise the suspicion of a malignant ovarian neoplasm.

Benign Adnexal Mass

Benign lesions tend to be less vascularized, with isolated vessels, mainly located peripherally, which have an increased blood flow impedance (RI >0.55).

Adnexal Mass Suspicious for Malignancy

A lesion can be considered malignant when there is a new vasculature network centrally at the level of the septa, and proliferations, arranged anarchically and abnormal in form (dilated vessels, arteriovenous shunts) with reduced flow impedance (RI <0.45).

The most widely available tumor marker test is measurement of CA 125. Levels greater than 35 U/ml are arbitrarily regarded as positive. However, specificity is lower in women of child-bearing age, since some adnexal or peritoneal conditions (PID, endometriosis) and menstruation increase the levels.

instrumental investigations are not necessary. Sometimes, MRI is indicated to assess tumor infiltration and abdominopelvic CT for lymph node assessment.

ovary (**Fig. 13**) and the presence of suspicious peritoneal implants (**Fig. 14**).

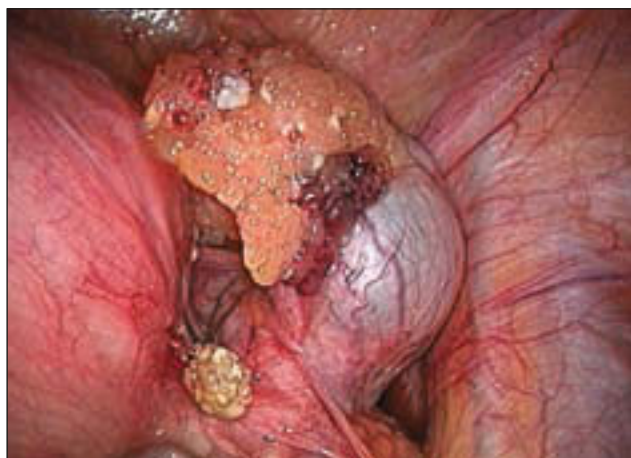

Fig. 13
Laparoscopic appearance of ovarian cancer on intra-operative inspection.

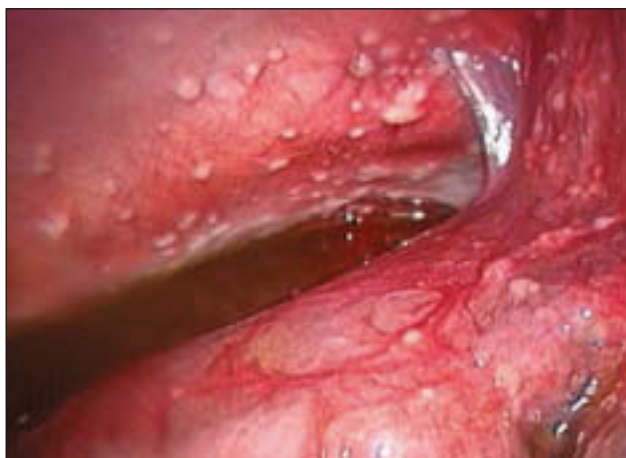

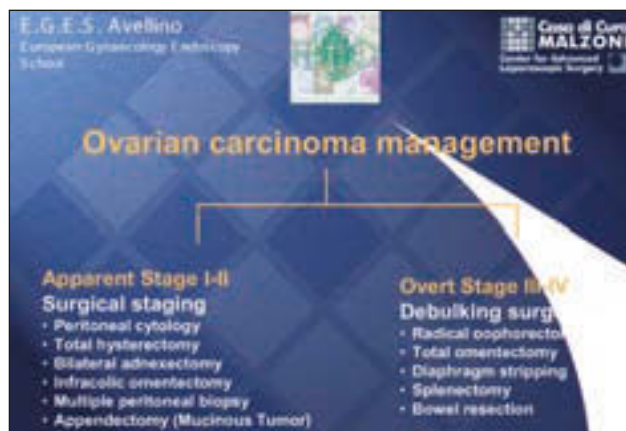Fig. 14
Peritoneal implants suspicious for malignancy.

4.0 Surgical Therapy

Faced with this type of disease, the choice must not be between laparoscopy and laparotomy but between conservative and non-conservative treatment. Surgical therapy must thus be tailored to the individual case, applying the basic principle of preserving as much ovarian tissue as possible.

The advantages of laparoscopy are obvious when applied to establish a differential diagnosis in terms of the benign/malignant nature of the adnexal mass. In young women who wish to preserve their fertility, laparoscopy allows intraoperative biopsies to be taken from the ovarian surface without causing rupture of the cyst. The histological result will decide the definite surgical therapy.

In the presence of a suspicious adnexal mass, intraoperative laparoscopic assessment may assist in choosing the type of abdominal incision, which should extend from the xiphoid process to the pubic symphysis in the presence of a malignant neoplasm. Both accurate tumor staging and debulking surgery (**Tab. 3**) require a midline incision. This pathology should be treated only in tertiary centers where oncologic surgery is performed as a matter of routine, and where adequate treatment can be ensured. In fact, two thirds



Tab. 3
Surgical management of ovarian cancer.

of ovarian cancers are stage III and IV when diagnosed and require conversion to laparotomy to allow adequate debulking.

4.1 Aspiration

General Principles

Simple puncture and aspiration of the cyst should be avoided since this is associated with an increase in recurrence rate. Aspiration is recommended only for dysfunctional cysts.

Aspiration is often performed prior to cystectomy. En-bloc enucleation of an endometrioma, a mucinous cyst or ovarian lesion larger than 10 cm is very difficult to manage laparoscopically. Under the aforementioned conditions, it is preferable to perform controlled prophylactic aspiration rather than risk accidental spillage of the cyst contents due

to rupture, which occurs frequently (**Fig. 15**). Above all, cyst aspiration facilitates cystectomy by reducing the tension of the cyst and allows inspection of its internal walls.

The suction cannula is introduced directly into the cyst on the antimesenteric side after immobilizing the ovary, grasping the ovarian ligament with an endoclinc grasping forceps (**Fig. 16**). It is sometimes sufficient to compress the ovary against the uterus. After removing the cyst contents with a suction cannula, the cyst cavity is lavaged. It is then possible to introduce the laparoscope through the opening to assess the inner surface.

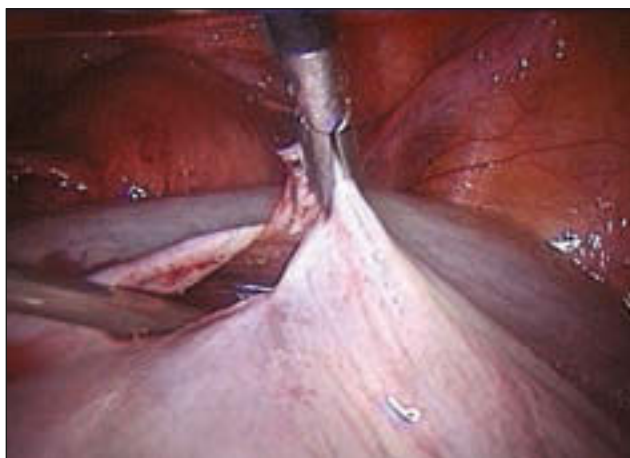


Fig. 15
Prophylactic aspiration of a giant ovarian cyst.

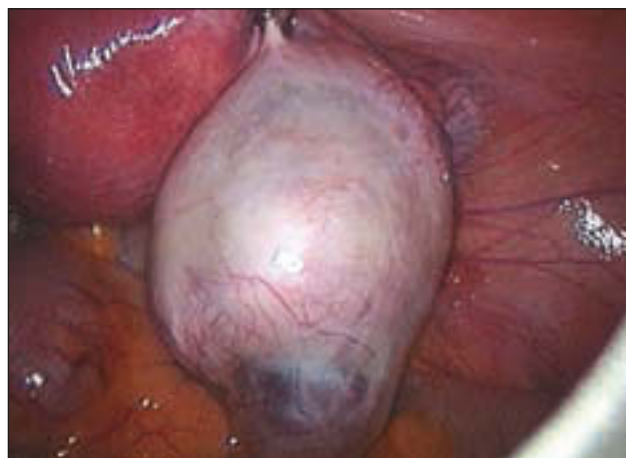

Fig. 16
Grasping the ovarian ligament with an endoclinc forceps and exposure of the antimesenteric margin.

4.2 Cystectomy

General Principles

Complete enucleation of the cyst with minor trauma to the residual ovarian parenchyma is advised in young patients of fertile age with epithelial, germinal and inclusion cysts. In addition, cystectomy allows full histological examination. It is surprising how often it is possible even with large cysts to preserve sufficient ovarian tissue around the hilum to restore ovarian anatomy satisfactorily. If an adequate blood supply can be ensured, full recovery of organ function can be anticipated.

Technique in brief

To improve exposure of the adnexae, a uterine manipulator must be applied. The ovary is then mobilized by lysis of the parapsycho-physiological adhesions to the rectosigmoid. Using a suction-irrigation cannula, the ovary is released from the posterior leaf of the broad ligament (ovarian fossa). The utero-ovarian ligament is then grasped with an endoclinc forceps to elevate and rotate the ovary.

To enucleate the cyst with the capsule intact, a small incision is made with unipolar scissors contralateral to the ovarian hilum until the wall of the cyst is reached (**Fig. 17**). From the incision margin, the ovarian cortex together with the very thin stroma is grasped using an atraumatic Dorsey or Matkowitz grasping forceps. The plane of cleavage between the capsule and ovary is identified by opening and closing the blades of the round-ended curved scissors (**Fig. 18**). The fibrous adhesions between the wall of the cyst and the ovarian tissue are dissected (**Fig. 19**). The blood vessels supplying the cyst are coagulated with bipolar forceps. Detachment is completed using the blunt tip of the suction/irrigation cannula. The incision in the ovarian cortex is then extended to allow removal of the intact cyst (**Fig. 20**).

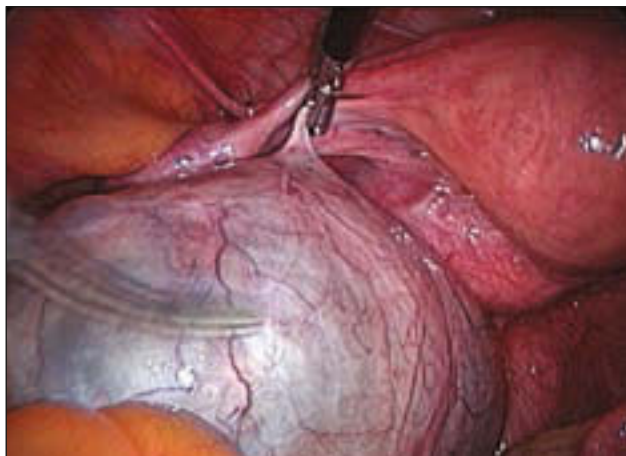


Fig. 17
The utero-ovarian ligament is grasped, the ovary is elevated and the ovarian cortex is then incised.

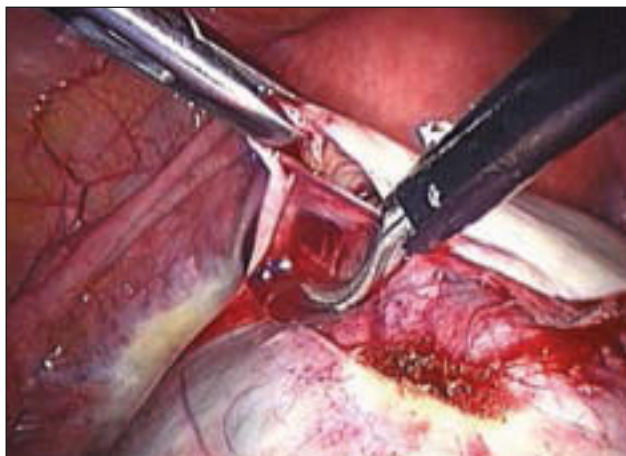


Fig. 18
Identification of the plane of cleavage by opening and closing the blades of the round-ended scissors.

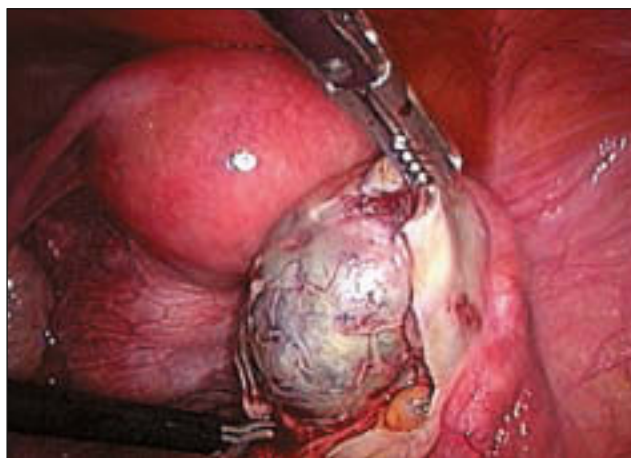


Fig. 19
Dissection of fibrous adhesions between the cyst capsule and the ovary.

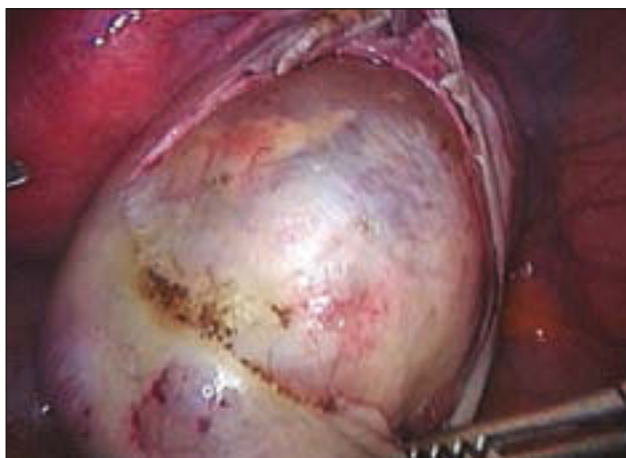


Fig. 20
Adequate incision of the ovarian cortex allows removal of the intact cyst.

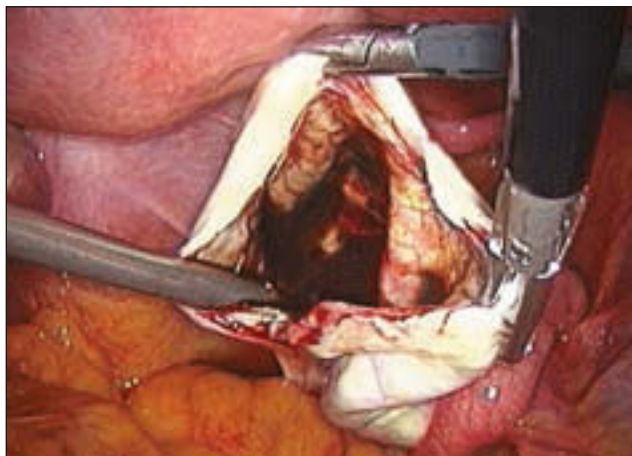


Fig. 21
Identification of the proper cleavage plane for enucleation of the endometrioma.

In other cases (endometrioma, mucinous cyst), enucleation of the cyst is preceded by “controlled prophylactic aspiration” of the cyst contents. After this step, it is useful to incise the cyst capsule and ovarian cortex with cold scissors. Two atraumatic grasping forceps are used to exert traction and countertraction to the incision margins. In this way it is possible to discriminate the proper cleavage plane located between the aforementioned structures (**Fig. 21**). The cyst capsule is then detached from the ovarian parenchyma by stripping (**Fig. 22**). This part of the operation is performed with the aid of two instruments, a Manhes forceps for a deep firm grip of the cyst and a toothed atraumatic forceps for the ovarian tissue, which must not be damaged. Hemostasis of the ovarian bed is obtained with a bipolar coagulation electrode (**Fig. 23**).

Protruding ovarian tissue is coagulated with bipolar forceps to invert the margins of the cortex and reduce the potential risk of adhesion formation. If the ovarian margins overlap, this is usually left to heal by primary intention without the need for suturing so that it closes spontaneously. In this way, the incidence of postoperative adhesions can be limited (**Fig. 24**). If the ovarian cortex does not tend to reapproximate spontaneously, one or two absorbable monofilament sutures can be placed to reconstruct the cortex. The sutures are transfixated and tied inside the ovary. This is followed by repeated irrigation with saline for full peritoneal toilet.

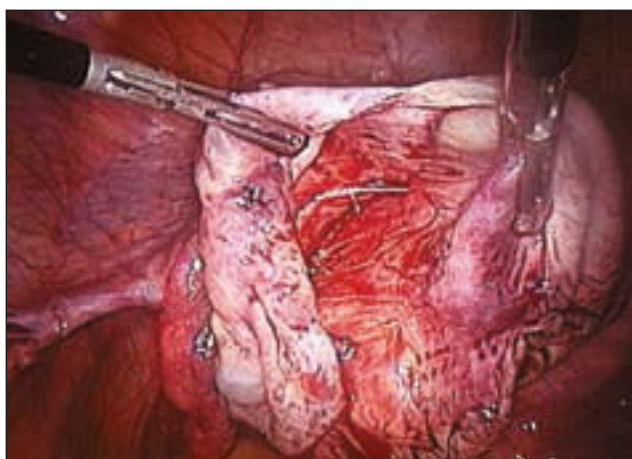


Fig. 22
Cystectomy with the stripping technique.

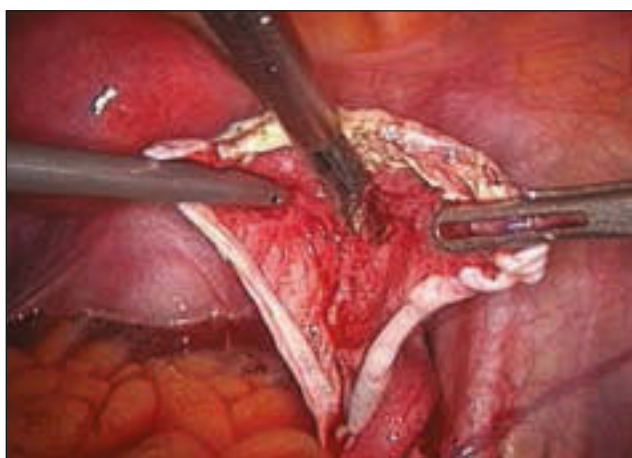


Fig. 23
Hemostasis of the ovarian bed using a bipolar coagulation electrode.

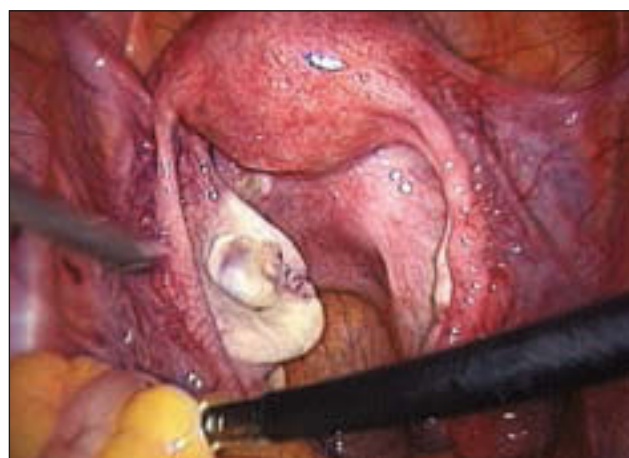


Fig. 24
Overlapping ovarian margins.

4.3 Oophorectomy

General Principles

Oophorectomy is indicated in young patients only if a conservative approach is not feasible due to insufficient residual ovarian tissue.

Technique in brief

After mobilizing the ovary, the ovarian pedicle is first coagulated and then divided. To achieve coagulation of larger vascular pedicles, it is preferable to use bipolar forceps with adequately wide jaws. The mesovarium and mesosalpinx are then coagulated and divided starting at the uterine side and proceeding toward the fimbrial tubal portion. The tube, which should be preserved, must be protected from iatrogenic injury.

4.4 Adnexectomy

General Principles

Adnexectomy is reserved for postmenopausal patients. In addition, the decision to remove the tube together with the ovary is indicated where the tube is also infiltrated by the pathology. However, removal of the entire adnexa is frequently performed because it is easier.

Technique in brief

The adnexa is elevated with a certain degree of traction. This avoids accidental injury to the lateral walls of the pelvis and to the underlying retroperitoneal structures.

The course of the ureter should always be identified. The ovarian vessels and common iliac vessels cross the ureter at its junction with the superior pelvic aperture. Descending in the pelvis, it runs inside the broad ligament just beside the uterosacral ligament. If it is not possible to identify the ureter clearly through the peritoneum, it is necessary to incise the peritoneum to access the retroperitoneal space and expose it (**Fig. 25**).

The next step involves fenestration of the posterior leaf of the broad ligament to mobilize the ureter away from the infundibulo-pelvic ligament. Next, the infundibulo-pelvic ligament is coagulated with the aid of bipolar forceps and transected by use of a cold knife. This can be accomplished more effectively if preceded by adequate vascular pedicle skeletonization (**Fig. 26**). The utero-ovarian ligament and the tubal isthmus are then coagulated and divided (**Fig. 27**).

The uterine vascular pedicles should always be inspected at the end of surgery as they can bleed when the hemostatic effect of positive intra-abdominal pressure has subsided.

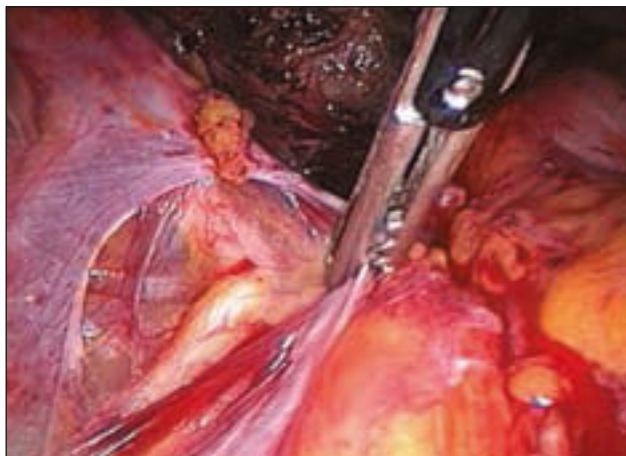


Fig. 25
Exposure of the ureter.

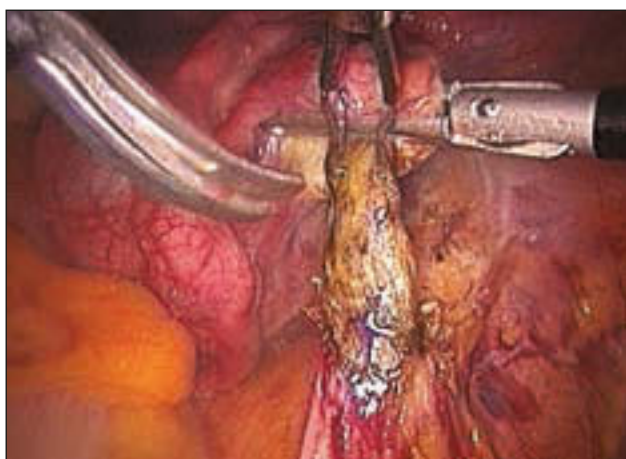


Fig. 26
Skeletonization of the infundibulo-pelvic ligament.

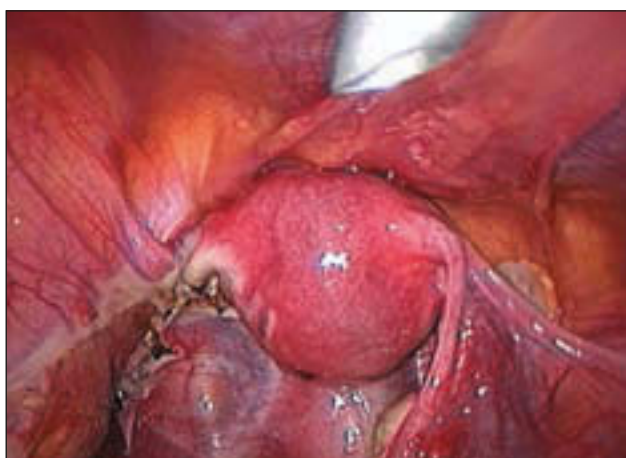

Fig. 27
Left adnexectomy.

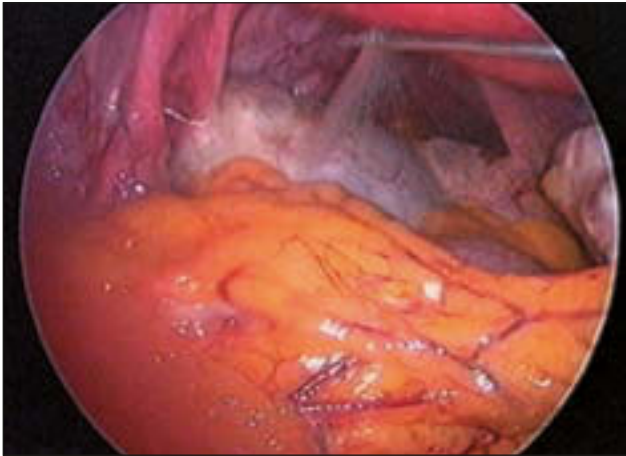


Fig. 28
Intraperitoneal washing for cytology testing.

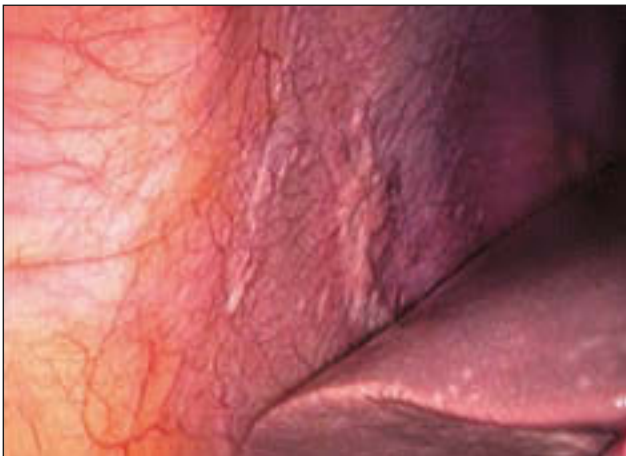

Fig. 29
Inspection of the peritoneal cavity.

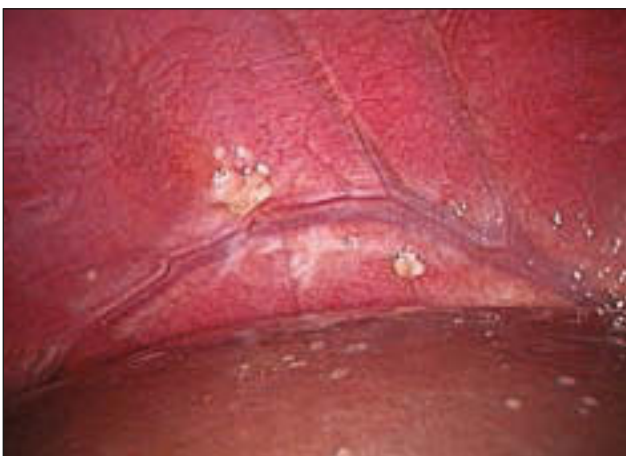

Fig. 30
Neoplastic lesions suspected for malignancy.

5.0 Guidelines for the Management of Suspicious Adnexal Masses

The standard approach in the laparoscopic management of suspicious adnexal masses includes cytology testing of peritoneal fluid, inspection of the abdominal and pelvic cavity combined with peritoneal biopsy, adnexectomy avoiding rupture of the capsule, extraction of the operative specimen with the aid of an endobag without morcellation of solid areas, and frozen section.

5.1 Cytology Testing

General Principles

To distinguish benign from malignant lesions, cytology testing of the peritoneal fluid is performed. The cytology samples of peritoneal fluid are taken with a suction needle attached to a syringe at the start of the procedure when the peritoneal fluid is free from blood. If the peritoneal fluid is insufficient, washing is performed, that is, the pelvis and abdomen are irrigated with saline (**Fig. 28**).

5.2 Inspection of the Peritoneal Cavity and Biopsy Sampling

General principles

Inspection of the abdominal and pelvic cavity (**Fig. 29**) to look for neoplastic lesions is completed with peritoneal biopsy of suspicious areas. When the peritoneal cavity appears normal (diaphragm, liver, intestine, omentum, peritoneum) random biopsies must be taken. On the other hand, if areas suspicious for malignant neoplastic lesions are detected (**Fig. 30**), the diagnosis of ovarian carcinoma stage III can be made. The procedure is converted immediately to laparotomy.

Technique in brief

The suspicious peritoneal area is grasped with forceps to obtain a sufficient amount for histological assessment. When this fold of tissue has been grasped, the peritoneal margin is incised. This gives access to the retroperitoneal space, which is dissected bluntly. Bleeding ceases spontaneously or can be controlled with bipolar coagulation.

5.3 Endobag

General Principles

In patients with ovarian tumors, even of low malignancy, extraction of the operative specimen can favor the dissemination of malignant cells, particularly implantation at the point of trocar insertion. To reduce this risk, endoscopic bags are used with the aim of protecting the abdominal wall (**Fig. 31**). During extraction of the specimen, morcellation to reduce the size of the solid tissue and facilitate the maneuver is not advisable because of the increased risk of dissemination of malignant cells. It follows that in the presence of suspicious adnexal masses with a diameter greater than about 7–8 cm, the laparoscopic approach is contraindicated. However, despite the use of these two precautions, cases of metastasis at the point of trocar insertion have been described (port-site recurrences, PSR).

Technique in brief

To introduce the endobag, the accessory trocar (6 mm) is removed, the accessory skin incision is extended to 10 mm and the bag cannula is introduced through the parietal port. After placing the extracted material in the bag, the edges of the endobag are pulled outside the wall and clamped with two Klemmer forceps. To allow passage of the bag with its contents through the abdominal wall, it is sometimes necessary to aspirate the cyst contents.

Frozen Section

Frozen section has been reintroduced by laparoscopist to reduce the incidence of unnecessary conversions.

However, frozen section diagnosis of ovarian tumors is difficult and has a false-negative rate of 5%, with the majority due to inadequate sampling by the surgeon or pathologist. Thus, in the presence of a laparoscopically suspicious

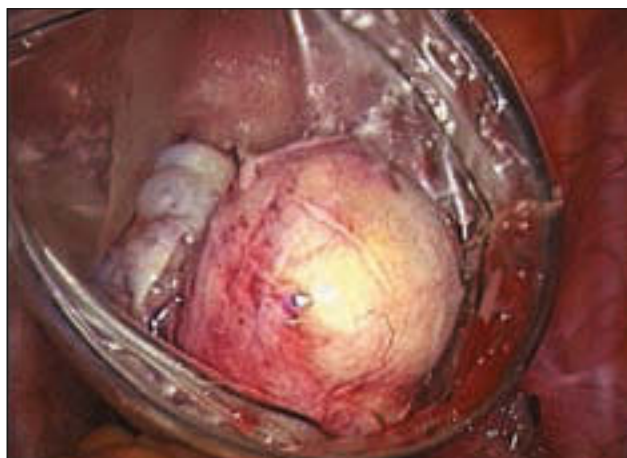

Fig. 31
Laparoscopic extraction bag.

ovarian lesion, frozen section should not be included in the criteria used for setting up the individual therapeutic strategy, whether conservative or ablative. In these cases, it is preferable to perform adnexectomy and thereby prevent the risk of neoplastic dissemination because of a false-negative frozen section result. Young patients with an adnexal mass with a small solitary lesion are an exception; these can be biopsied.

On the other hand, biopsy with frozen section is essential in re-staging and avoids reoperation which is poorly acceptable for the patient.

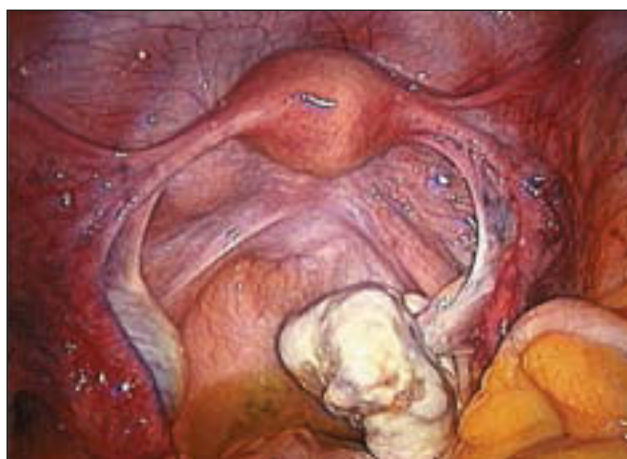Where frozen section is not available, any ovarian lesion suspected for malignancy at laparoscopy, must be removed intact by adnexectomy. The type of subsequent treatment will be decided after surgery.

Chapter XIV

**Laparoscopic Management of
Borderline Ovarian Tumors**

Paulo Ayroza and Elizabet Abdalla

Department of Gynecology and Obstetrics,
Medical School of the Santa Casa University of
São Paulo, Brazil



1.0 Introduction

Among all gynecologic diseases, the topic of ovarian tumors is perhaps one of the most controversial with regard to diagnosis, classification, and treatment modalities. Undoubtedly, this reflects the great significance of this disease among female patients. Whether benign or not, all ovarian tumors must be examined thoroughly. Functional cysts may regress within months, whether or not any medication is used. On the other hand, nonfunctional tumors tend to persist and require an accurate workup.

Since the advent of the laparoscopic technique many years ago, we have been able to identify benign cysts and subsequently treat them laparoscopically. Today, it is even possible to manage by laparoscopy some ovarian malignancies that required laparotomy until a few years back.

Nevertheless, it is not at all unusual to find statements of authors in the literature advising against laparoscopic treatment of benign ovarian cysts such as endometriomas and dermoid cysts.

There are numerous reports in the literature justifying the use of laparoscopy as a diagnostic and therapeutic tool for benign ovarian tumors. In the authors' group, use a routine diagnostic protocol is used, which requires that all patients with ovarian tumors are submitted to clinical and laboratory work-up (clinical examination, transvaginal ultrasound, and serum marker levels), followed by laparoscopy.

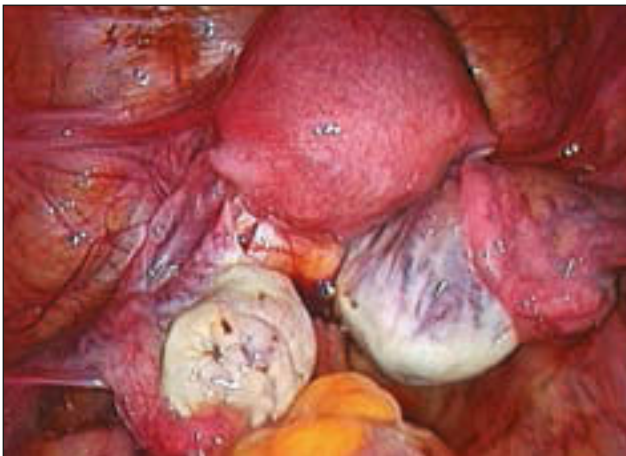

Fig. 1
Bilateral ovarian endometriotic cysts.

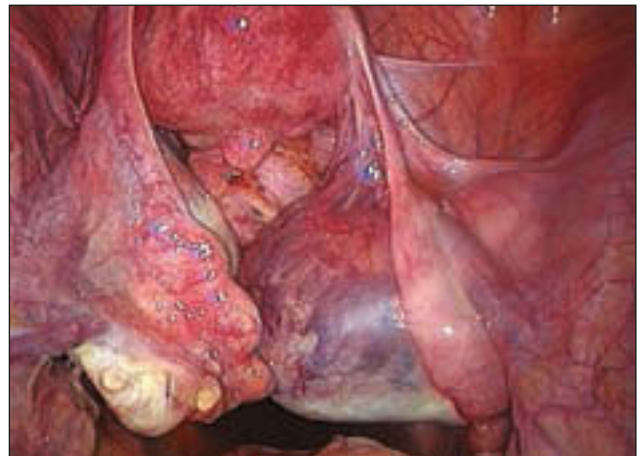

Fig. 2
Ovarian endometriotic cyst.

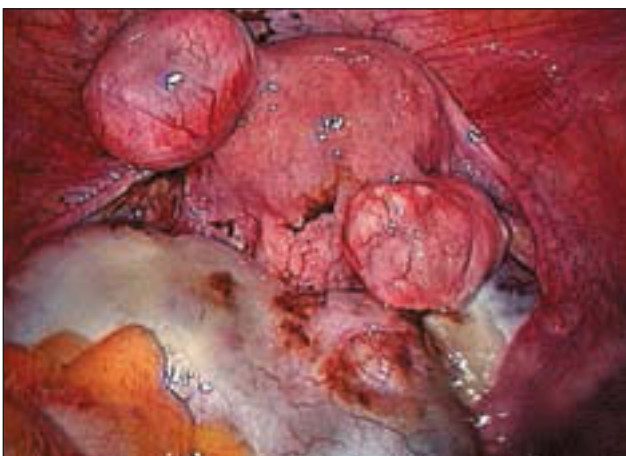


Fig. 3
Large ovarian cyst and uterine myomas.

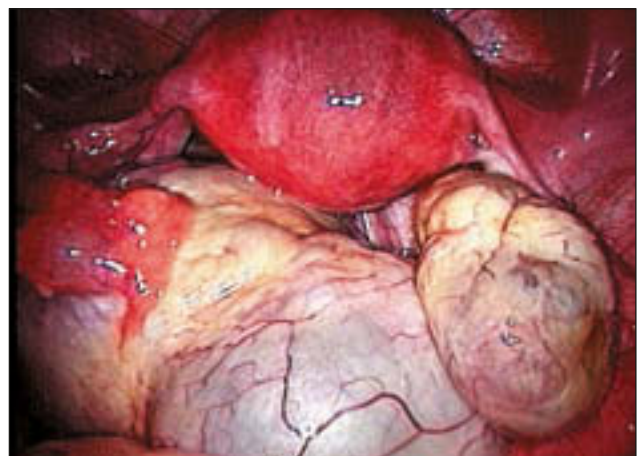


Fig. 4
Functional ovarian cyst.

During the laparoscopic procedure, we recommend that a strict protocol for the pelvic examination be observed to ensure the highest level of security. The laparoscopic appearance of ovarian cysts can be highly variable depending on their nature (endometriosis, functional, teratoma, etc.), which is why visual inspection plays a vital role in establishing a definitive diagnosis and differentiating between malignant or borderline lesions (**Figs. 1–8**).

Our routine use of this protocol over the past 15 years has resulted in a false-negative rate of 0.5%. This means, that in 99.5% of patients, the result of our clinical investigation proved to be correct. The method of laparoscopic visualization of ovarian cysts in conjunction with intraoperative histological

examination has demonstrated to be effective in the detection of all ovarian malignancies.

Laparoscopic surgery has shown to be a safe and helpful modality for both ovarian cystectomy and oophorectomy or adnexectomy in that it provides all benefits of minimally invasive surgery while at the same time preserving patient safety and fertility.

Which steps should be taken when ovarian malignancies or borderline tumors are detected is more controversial. The main question is whether these tumors may be treated laparoscopically. In this chapter, we will discuss only borderline ovarian tumors.

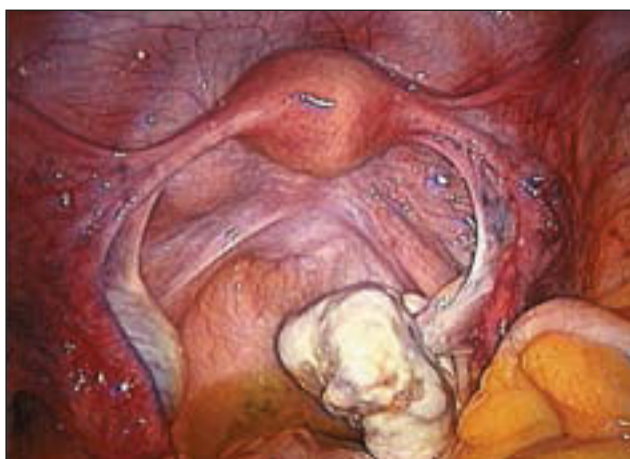

Fig. 5
Solid ovarian cyst.

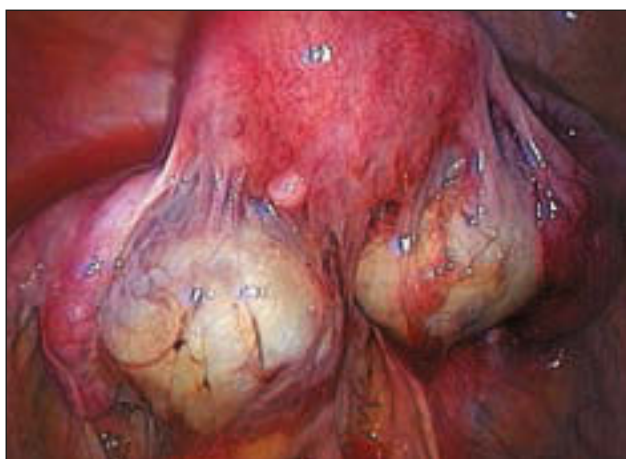

Fig. 6
Bilateral ovarian teratoma.

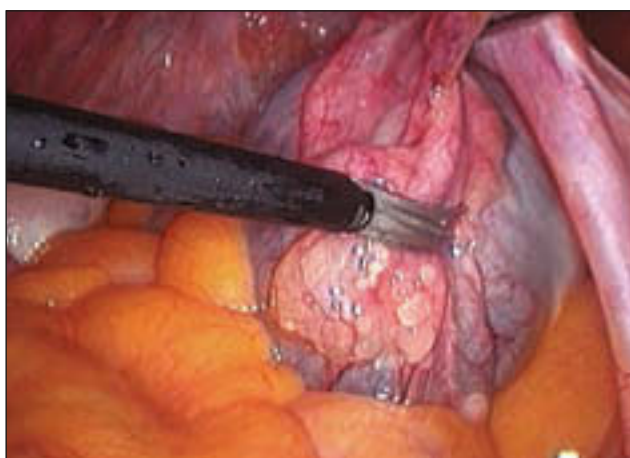


Fig. 7
Surface proliferations of an ovarian borderline tumor.

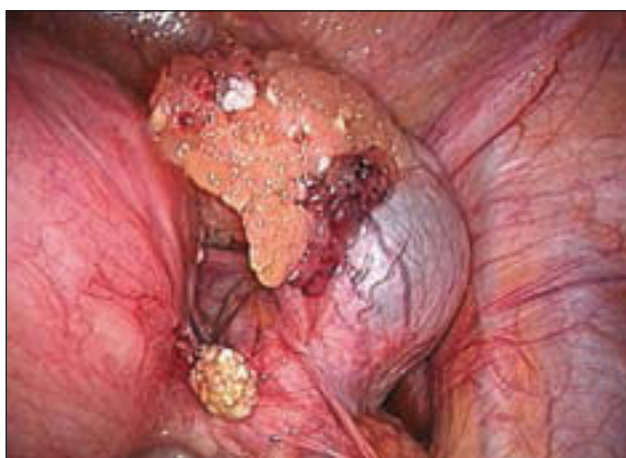

Fig. 8
Surface proliferations of an ovarian borderline tumor.

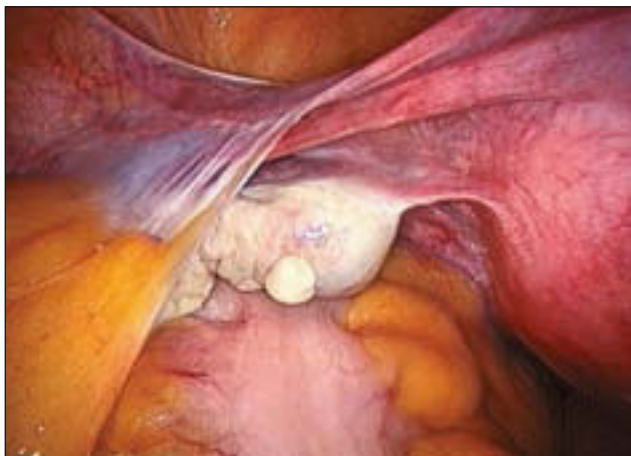

Fig. 9
Ovarian borderline lesion.

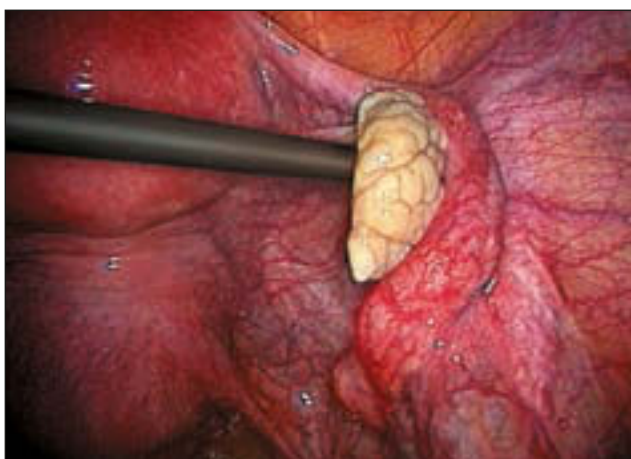

Fig. 10
Borderline tumor of cerebriform appearance.

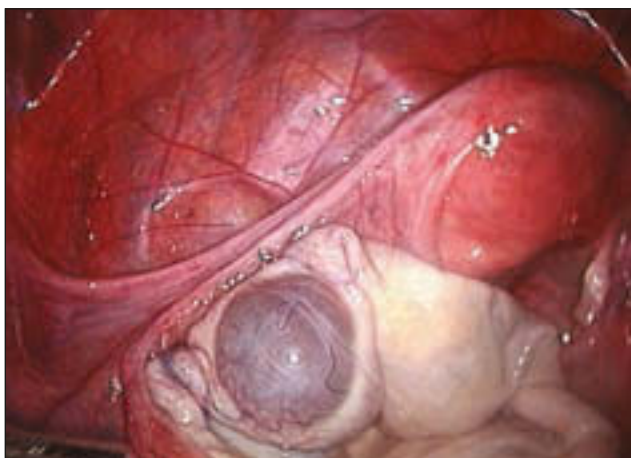


Fig. 11
Multilobulated borderline ovarian cyst.

2.0 Borderline Ovarian Tumors (Tumors of Low Malignant Potential)

“Our goal is to perform laparoscopically a good oncologic procedure”

Paulo Ayroza Ribeiro

Borderline ovarian tumors are a subset of epithelial ovarian tumors, which have a very favorable prognosis. The universally accepted treatment is surgical removal of the tumor and histological examination. However, the postoperative management protocol is highly controversial. To date, no medical therapy has been shown to clearly improve outcomes.

In 1929, *Taylor* first described a subset of ovarian tumors that he termed semi-malignant. Although these lesions had a more favorable prognosis than other ovarian cancers, it was not until the early 1970s that they were classified separately as borderline tumors.

One woman in 55 (1.8%) develops some form of ovarian cancer in her lifetime. Approximately 90% of these cancers are tumors of epithelial origin. If benign lesions are included, epithelial tumors account for 60% of all ovarian tumors.

Borderline tumors account for approximately 15% of all epithelial ovarian tumors. The mean age of occurrence is approximately 10 years below that of women with ovarian cancer of distinctly malignant nature. Predisposing factors believed to be associated with borderline tumors include oral contraceptive use, menarche, age at first pregnancy, age at first delivery, menstrual history, smoking and family history of ovarian cancer. None of these factors, however, has been shown to be statistically significant.

Borderline ovarian cancer is staged according to the FIGO classification of ovarian cancer. Many clinicians combine stages II to IV when assessing prognosis. Another common component of staging is the description of the type of implants as these have significant prognostic value.

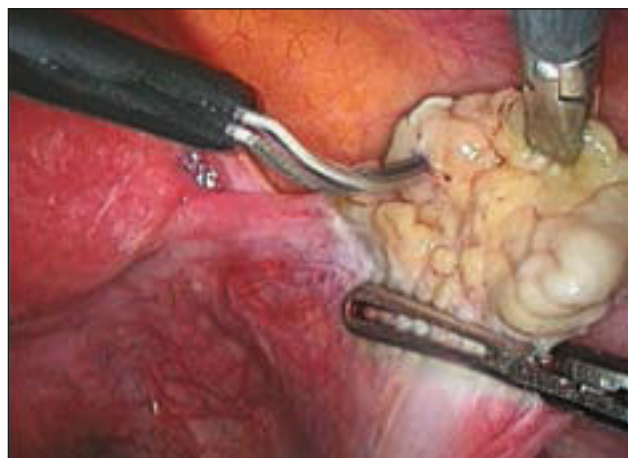


Fig. 12
Removal of a borderline tumor: coagulation of the mesovarium with a bipolar instrument.

In contrast to epithelial ovarian carcinoma, its true malignant counterpart, borderline ovarian tumors are often detected at an early stage, and this is probably one of the factors that encourage the clinician to opt for conservative treatment and also to use laparoscopy as a therapeutic tool.

The etiology of the disease remains unclear because of the small number of cases and the lack of randomized controlled studies. The two major histologic tumor subtypes are serous and mucinous, with the serous subtype being more common. Other far less common tumors include clear cell and endometrioid forms. Serous tumors are presumed to originate from the germinal epithelium. Mucinous tumors do not have a clearly defined origin. Many authors consider that borderline tumors occupy an intermediate position between their benign and frankly malignant counterparts.

These tumors, like other ovarian tumors, are difficult to detect clinically until they are advanced in size or stage. The most common presenting symptoms are abdominal pain, abdominal distension and the presence of an abdominal mass. Approximately 23% of patients are completely asymptomatic.

Surgery is always indicated when a complex ovarian mass is discovered, except in special cases when the patient has clinical contraindications to surgery. Preoperative diagnosis of borderline tumors is extremely rare, if not impossible, and they are nearly always believed to be benign or malignant ovarian masses. The use of laparoscopy as an early diagnostic tool is particularly recommended as it allows differential diagnosis between benign, malignant and borderline tumors (Figs. 9–11).

As mentioned above, preoperative diagnosis is very difficult, if not impossible. Measurement of certain parameters, such as cancer antigen 125 (CA125) is of little diagnostic value as they are not specific for borderline tumors. Imaging studies using transvaginal color Doppler ultrasound have been suggested to assess the malignant potential of ovarian masses. The detection rate from intratumoral blood flow characteristics in borderline tumors is similar to that of malignant neoplasms,

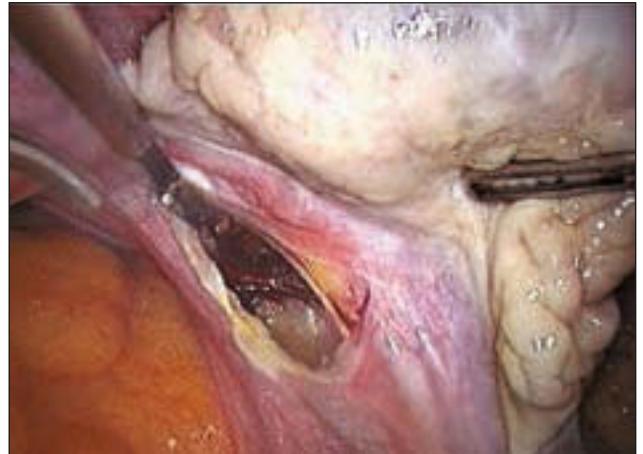

Fig. 13
Removal of a borderline tumor: division of the mesovarium.

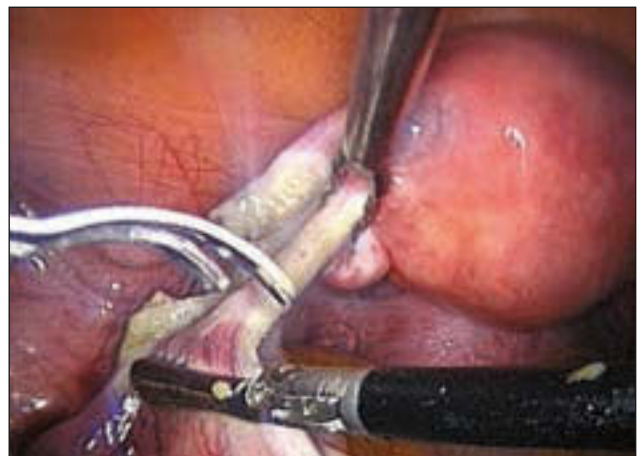

Fig. 14
Removal of borderline tumor: transection of the round ligament and tube.

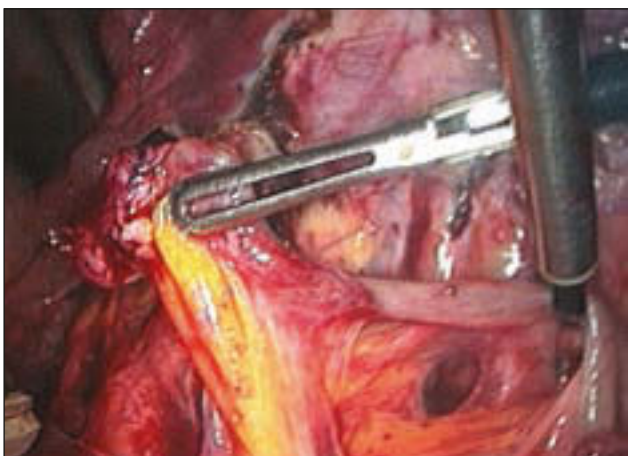


Fig. 15
Exposure of the appendix.

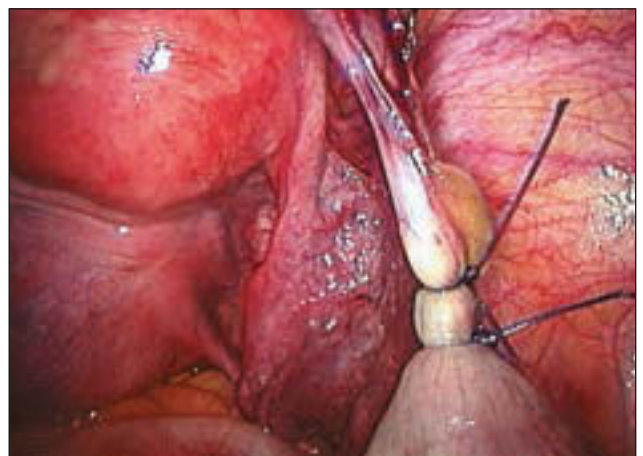


Fig. 16
Exposure and double ligation of the appendix before dividing it.

i.e. 90% and 92%, respectively. Doppler indices, such as the resistance (RI) and pulsatility indices (PI) are also significantly reduced in carcinoma and borderline ovarian tumors as compared to benign tumors. While useful in some situations, this modality is not currently part of the standard work-up. In terms of specificity and sensitivity its diagnostic value is not sufficient, i.e., it cannot be recommended as a screening tool in the normal patient population. CT scanning and MRI studies may be also useful in the pre-operative work-up.

As with other malignant neoplasms, staging is performed surgically. Many sources recommend complete staging if a borderline tumor is found. Current guidelines include biopsy specimens of the pelvic peritoneum (pouch of Douglas, pelvic wall and bladder peritoneum) and abdominal peritoneum (paracolic gutters and diaphragmatic surfaces). Some authors also suggest biopsy of the omentum, intestinal serosa and mesentery, and retroperitoneal lymph nodes (pelvic and para-aortic).

The histologic appearance of borderline tumors is quite complex because it is not always easy to differentiate them

from benign lesions. The number of cell layers, percentage of mitoses and nuclear atypia are the criteria which are used to define these tumors.

Approximately 25% of borderline tumors have cell proliferations on the outer surface of the lesion, with no evidence of growth from the inner surface. Of these, approximately 90% develop peritoneal implants. Only 4% of cases with peritoneal implants do not have surface proliferation. Peritoneal implants are described as invasive or noninvasive. Noninvasive implants are glandular or papillary proliferations with cell detachments.

As regards surgical treatment, complete excision of the lesion must be achieved if at all possible. Secondary procedures, such as appendectomy, can be performed at the same surgery (Figs. 12–19). Comprehensive staging, as described above, should be a part of every operation of this type. Even though the stage may or may not affect future treatment, it is of significant prognostic value and, therefore, is of high relevance for both clinician and patient. In 77% of patients with invasive peritoneal implants, noninvasive implants are also found. Surgical excision and full staging decrease the risk of biopsy error, which could result in an inaccurate diagnosis and prognosis. Some authors have concluded that fertility-preserving surgery can be offered to patients with stage IA disease with serous or mucinous tumors.

The optimal treatment of early-stage borderline ovarian tumors is controversial. Only a few randomized trials evaluating adjuvant treatment for this disease have been published. A Norwegian study concluded that stage I borderline tumors should not receive any adjuvant treatment.

Surgical laparoscopy can be used in cases where the tumor is limited to the ovary without any sign of dissemination. In the past, various authors maintained that laparoscopic management of borderline ovarian tumors should be reserved for early-stage disease but that this was associated with a high risk of recurrence, especially due to an increased rate of cyst rupture with possible dissemination of potentially neoplastic cells.

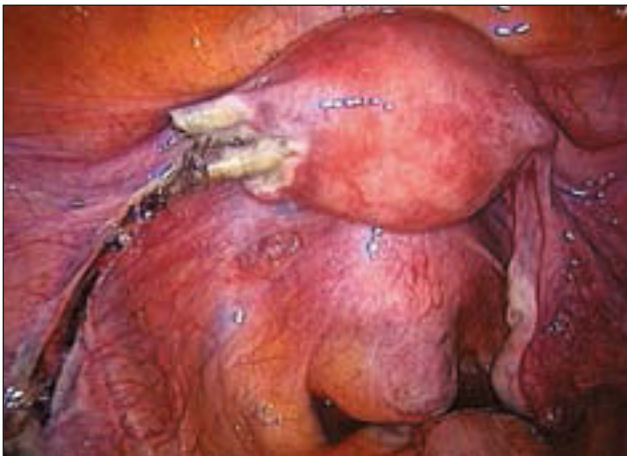

Fig. 17
Removal of borderline tumor: the operating field at the end of the surgery.

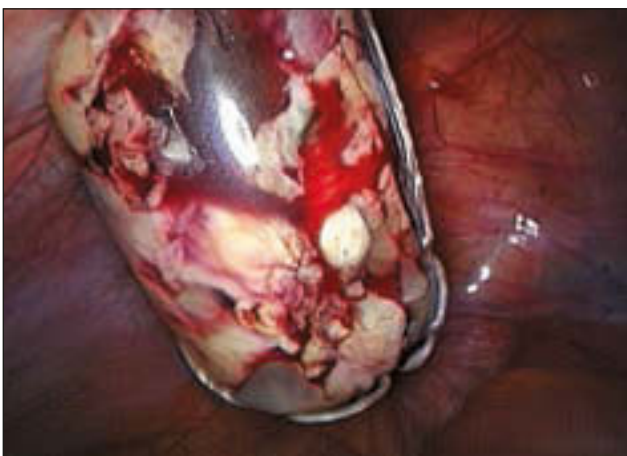

Fig. 18
Removal of borderline tumor: extraction in plastic bag.

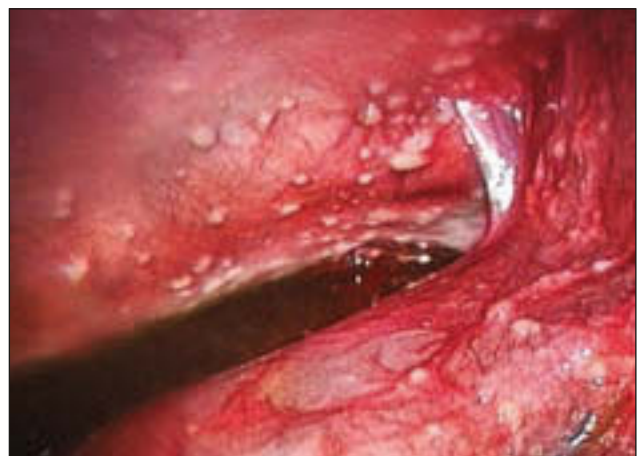

Fig. 19
Invasive peritoneal implants.

In a recent study, a French group stated that conservative treatment and cyst rupture occurred more frequently in the laparoscopy group than in the laparotomy groups. Staging was incomplete more often in the laparoscopy group than in the laparoconversion and laparotomy groups. They concluded that the laparoscopic management of borderline ovarian tumors is associated with a higher rate of cyst rupture and incomplete staging. It is known that recurrence is more frequent after conservative treatment or incomplete initial staging, whatever the surgical approach.

This study emphasizes the importance of FIGO staging in borderline tumors. The majority of laparoscopic surgeons are more conservative by nature and have a background in infertility, and this may have a negative influence on the quality and radicality of surgery. In the case of borderline tumors, the surgeon must combine accurate knowledge of oncologic aspects with the reproductive concepts of fertility preservation. Bearing this in mind, it will be possible to offer all the benefits of laparoscopic surgery even in the area of oncology.

As stated by our authors, surgeons still can provide reproductive surgery solutions for these patients. Conservative laparoscopic management of borderline ovarian tumors is a potentially safe alternative for young women who want to retain their fertility potential. Fertility and pregnancy outcomes remain excellent in these women. Preliminary data suggest, that the recurrence rate following pregnancy was not influenced by this approach.

An important contribution to this topic was also offered by an Italian group suggesting that the laparoscopic management of borderline ovarian tumors should be reserved for masses not greater than 5 cm. When conservative therapy is desired, they recommend removal of the entire affected ovary. Furthermore, they suggest that if the neoplasia is bilateral, cystectomy could be allowed in women who wish to preserve fertility, although they are at high risk of recurrence.

One of the most important complications of laparoscopic surgery in oncologic situations is port-site metastasis. In a recent study, the authors concluded that unlike port-site metastasis in other gynecologic malignancies, the prognosis in patients with a port-site implant after laparoscopic management of borderline ovarian tumors is excellent. The treatment of this complication is surgical resection.

It is important to emphasize that independent of the technique employed in these cases, suspicious ovarian cysts should never be punctured. Extreme care must be taken to

remove the tumor without any rupture. In these situations we recommend the use of plastic extraction bags when removing the cysts to prevent any spillage into the peritoneal cavity or port site. Furthermore, in some instances, we perform enucleation of the entire tumor inside the bag.

Some groups maintain that conservative surgery remains a therapeutic option in selected patients with borderline ovarian tumors. Even if the rate of new lesions/recurrence is relatively high with laparoscopy, especially in patients treated with simple ovarian cystectomy, mortality from cancer remains low. Many patients are able to conceive and carry a normal pregnancy to term after conservative surgery.

In most instances, laparoscopic surgery is curative for patients with stage I disease. If the tumor is unilateral and there is still some healthy ovarian tissue, unilateral cystectomy can be performed with preservation of the healthy part of the ovary; however, inspection of the cyst capsule for signs of rupture should be performed before resection. If it is not feasible to preserve healthy ovarian tissue, oophorectomy or salpingo-oophorectomy should be performed.

Because of the possible association between borderline ovarian tumors and peritoneal implants, the peritoneum should be explored carefully. Peritoneal assessment must be performed with great care. Any suspicious peritoneal lesion detected at laparoscopy, should be biopsied for histology (invasive or noninvasive) and then removed surgically. The histological type is of significant prognostic value.

Most of the complications of this disease are caused by the operation itself, adjunctive therapy and by recurrence.

From the results in the literature, it is apparent that it is difficult to give an accurate prognosis for an individual patient without full surgical staging. In one study of stage I disease, all recurrences occurred in patients who were inadequately staged. Many, if not all, of these patients probably did not actually have stage I disease.

Pathologic diagnosis is difficult to confirm by frozen section. Borderline tumors are correctly diagnosed by frozen section in 58–86% of cases, depending on the experience of the pathologist. In one very large study, frozen section indicated probable malignancy in 94% of cases subsequently diagnosed as borderline tumors. Thus, the proper operation and staging procedures should have been performed during the initial surgery in most cases, even though diagnosis by frozen section was not completely accurate.

Recommended Reading

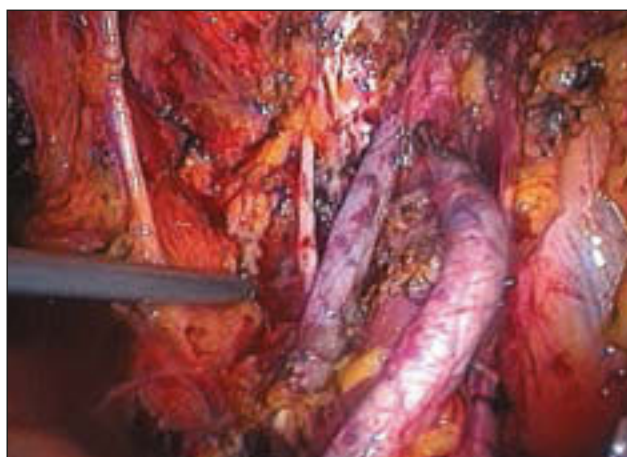1. ATALLAH D, MORICE P, CAMATTE S, et al: Place et résultats de l'examen extemporané dans la stratégie chirurgicale des tumeurs épithéliales malignes et à la limite de la malignité de l'ovaire. *Gynecol Obstet Fertil* 2004; 32: 651-6, 2004
2. CHARLES L, ALGARA A, RAMÍREZ P, FLORES C: Manejo Laparoscopico del Tumor Ovarico Limitrofe (Borderline). Analisis de la Literatura y Presentacion de un Caso. *Ginecol Obstet Mex* 2001; 69: 355-358
3. DARAI E, TEBOUL J, FAUCONNIER A, SCOAZEC JY, et al: Management and outcome of borderline ovarian tumors incidentally discovered at or after laparoscopy. *Acta Obstet Gynecol Scand* 1998; 77: 451-7
4. FAUVET R, BOCCARA J, DUFOURNET C, PONCELET C, et al.: Laparoscopic management of borderline ovarian tumors: results of a French multicenter study. *Ann Oncol* 2005; 16: 403-10
5. GREEN AE, SOGOR L: Borderline Ovarian Tumor e-medicine.com
6. KOERN J, TROPE CG, ABELER VM: A retrospective study of 370 borderline tumors of the ovary treated at the Norwegian Radium Hospital from 1970 to 1982. *Cancer* 1993; 71: 1810-1820
7. MANEO A, VIGNALI M, CHIARI S, COLOMBO A, et al: Are borderline tumors of the ovary safely treated by laparoscopy? *Gynecol Oncol* 2004; 94: 387-92
8. MORICE P, CAMATTE S, LARREGAIN-FOURNIER D, THOURY A, et al: Port-Site implantation after laparoscopic treatment of borderline ovarian tumors. *Obstet & Gynecol* 2004; 104: 1167-1170
9. MORRIS RT, GERSHENSON DM, SILVA EG, FOLLEN M, et al: Outcome and reproductive function after conservative surgery for borderline ovarian tumors. *Obstet & Gynecol* 2000; 95: 541-547
10. TROPE C, KAERN J, VERGOTE IB, et al. Are borderline tumors of the ovary overtreated both surgically and systematically? A review of four prospective randomized trials including 253 patients with borderline tumors. *Gynecol Oncol* 1993; 51: 236-243,
11. SERACCHIOLI R, VENTUROLI S, COLOMBO FM, GOVONI F, et al: Fertility and tumor recurrence rate after conservative laparoscopic management of young women with early-stage borderline ovarian tumors. *Fertil Steril* 2001; 76: 999-1004

Chapter XV

Laparoscopic Hysterectomy

Arnaud Wattiez

Strasbourg University Hospital
Strasbourg, France



1.0 Introduction

Hysterectomy is currently the most frequently practised surgery not related to pregnancy in women. In the United States alone about 600,000 operations are carried out per year.

Historically, the first surgical approach for hysterectomy was abdominal, carried out in 1843 by *Charles Clay* in Manchester, England. The alternative to the abdominal route has always been the vaginal route: the first vaginal hysterectomy was reported by *Soranus of Ephesus* in 120 BC. Apart from this historical curiosity, the vaginal approach has certainly always been the route of choice, if possible with abdominal hysterectomy being the alternative when the vaginal approach proves not feasible.

This surgical approach remained unchanged until 1988 when *Harry Reich*, in Kingston, carried out the first laparoscopic hysterectomy. The first procedure described was *laparoscopic assisted vaginal hysterectomy* (LAVH), followed by *supracervical laparoscopic subtotal hysterectomy* (SLH) and finally *total laparoscopic hysterectomy* (TLH). Over recent years various types of instruments have been produced to facilitate TLH, in particular the uterine manipulator, which we introduced in 1995.

Today, there are many indications for laparoscopic hysterectomy. In benign conditions, it has major advantages, for example in uterine fibromatosis and in the treatment of genital prolapse, as the first stage of promontory fixation. Malignant conditions now also benefit from the laparoscopic approach, particularly endometrial cancer and, in the hands of an experienced surgeon, cancer of the uterine cervix.

Nevertheless, even today in the United States, only 10–15% of hysterectomies are carried out by laparoscopy, and most are only *laparoscopic-assisted vaginal hysterectomies* (LAVH). The ACOG (*American College of Obstetrics and Gynecology*) indications state that, in order to choose the approach, the anatomy of the patient and the surgeon's experience of the different techniques must be considered. Indeed, most surgeons still prefer the laparoscopic-assisted approach to a totally laparoscopic technique. However,

there has been a significant increase in the numbers of laparoscopic hysterectomies over the past ten years; in the United States the percentage was 0.3% in 1990 and 9.9% in 1997. Some authors report a high rate of complications during laparoscopic hysterectomy: 5.8%–11.5% for all complications taken together and a rate of 2.2%–2.7% for major complications. These statistics have led certain schools of surgery to limit strictly the indication for the laparoscopic approach in hysterectomy. The figures are often distorted by incorrectly selecting patients who are obese or have a large uterus; moreover, the experience of the surgeon is of fundamental importance, particularly during the learning period. More recent studies have shown that after a period of training of about thirty hysterectomies, the rate of complications is equivalent to that using other approaches. The average duration of surgery is also comparable to that required for the vaginal route in the hands of an expert surgeon.

It is true to say, that nowadays there is no major contraindication to the laparoscopic approach in hysterectomy, not even the dimensions of the uterus; indeed, provided proper application of the technique, successful laparoscopic hysterectomy of a very bulky uterus is possible using different types of morcellators and laparoscopic instruments.

A surgeon's lack of experience and dexterity nevertheless remain relative contraindications. It is evident, that choosing the laparoscopic approach depends on the surgeon's experience and the level of difficulty of each individual case. Finally, it is incorrect to unduly extend the length of the procedure, thus exposing the patient to excessively prolonged anesthesia.

The only absolute contraindication is the size of the uterus in the case of endometrial carcinoma, as it is essential to remove the uterus intact in the presence of neoplasia. However, this is of fairly rare occurrence since endometrial carcinoma is mostly found in a uterus of normal dimensions.

Finally, if general anesthesia is absolutely contraindicated, the vaginal route may be proposed as a suitable alternative.

2.0 Operating Room Setup

2.1 The Patient

Both arms are arranged alongside the body; this avoids the risk of brachial plexus injury due to the position of the surgeon or assistant. The right arm must be well protected. The use of shoulder braces is advisable especially if an extreme Trendelenburg position is required.

A bladder catheter should be in place throughout the procedure.

The patient is placed at the edge of the table (ideally, the soft perineal parts will be off the table and the patient will lie on it

only from the tip of the coccyx); this position is very important since it facilitates manipulation of the uterus and, consequently, exposure of the tissues.

Each leg will be semiflexed to free a conical manipulation area.

The operating fields are disinfected and adequately draped for both a vaginal and abdominal approach, allowing the surgeon to perform uterine manipulations under strict aseptic conditions.

2.2 The Surgical Team

The surgeon is on the patient's left; he/she operates with both hands and should stand upright with both elbows close to the body, the line of sight passing between both hands.

The first assistant will be to the right; he/she holds the camera with the non-dominant hand and operates the instrument positioned in the pelvic port.

The second assistant will be positioned between the patient's legs; his/her function is to assist in exposing the operating field to the surgeon. He/she should be seated to avoid

impeding the surgeon's view and to ensure effective presentation.

A scrub nurse will be particularly useful when sutures are being placed; she is positioned on the surgeon's left.

The table, fitted with stirrups, should be lowered as far as possible to allow the surgeon to adopt a correct ergonomic angle for his arms. One video screen should be positioned by the patient's right foot for the surgeon and another screen by the patient's left foot for the first assistant.

3.0 Hysterectomy Technique

3.1 Positioning the Trocars

The choice of trocars and their placement depends on the technique used, the size of the uterus, cost and availability.

Once the patient is anesthetized, the surgeon conducts a clinical examination. Vaginal inspection allows the size of the uterus to be determined. This influences the position of the trocars. At the same time uterine mobility is assessed.

The distance between umbilicus and symphysis pubis must measure at least 30 cm. If this distance is shorter or if the uterus is large, the central operating trocar will be inserted through the umbilical port and an 11 mm-trocar will be placed in the midline between the xiphoid process and the umbilicus for the laparoscope.

The primary trocar is usually inserted through the umbilical port. Once the laparoscope with coupled video camera has been passed through this port, the operating surgeon visually determines the size of the uterus and confirms uterine mobility by use of the manipulator. Access to the adnexa and the pouch of Douglas is also assessed. The upper quadrants of the abdominal cavity should be systematically explored.

Next, the lateral accessory ports are placed. Special attention must be paid to the following anatomical landmarks:

- the epigastric pedicle: a branch of the iliac pedicle, emanating from the parietal surface at the level of the deep inguinal ring. It continues upwards on the deep surface of the rectus abdominis muscle. At the level of the umbilicus,

it penetrates deep into the muscle and anastomoses with the internal mammary artery. In most cases, this artery is clearly set off against the contour of the umbilical artery;

- the lateral edge of the rectus abdominis muscle: this border is essential, because the port must be placed outside the muscle;
- the area of the oblique muscles: a triangular-shaped area beyond the lateral edge of the rectus abdominis muscle. The thickness in this area is reduced, with only a few muscle fibres;
- the anterior superior iliac spine situated about 3 cm outside the oblique muscle area.

The lateral accessory ports are placed in the centre of the oblique muscle area. These two trocars are 6 mm in diameter. We prefer to use lightweight plastic disposable trocars. They have the advantage of remaining straight in the abdominal wall, facilitating single-handed insertion of operating instruments. The trocar valve allows sutures to be placed with a minimum of gas loss. At this point, the use of a high flow insufflation unit (20–30 L/min.; e.g., KARL STORZ THERMOFLATOR®) is especially recommended to maintain clear vision even in the case of gas loss (vaginal opening and sutures).

Once the lateral ports are in place, the third accessory port is created. This port does not need to be placed below

the horizontal line between the two lateral ports. Ideally, it should be slightly higher than this line giving the surgeon a more ergonomic working position and a greater variety of working angles for use of operating instruments. The distance between the operating trocar and the camera trocar must be as great as possible and should never be less than 8 cm.

If the uterus is bulky or if the distance between the umbilicus and the pubis symphysis is short, the umbilical port is used for the operating instruments, and another port is placed superiorly.

One ergonomic criterion that must be observed during laparoscopy is bringing together the eye-instrument axis; consequently, the size of the uterus becomes relatively less

important during the procedure. In fact, if the ports are placed at a higher level and the operating field is limited during the different stages of the procedure, the laparoscopic technique may also be applied easily even in the case of a very large uterus.

The diameter of the central port varies depending on the technique applied. A 6 mm trocar is sufficient for techniques using solely electro-surgical coagulation and sutures.

The use of atraumatic forceps, mechanical suturing devices or 10 mm-clip applicators requires the use of a 10/12 mm trocar. In this case, the umbilical entry site for the central trocar is advisable.

3.2 The Uterine Manipulator

The role of the uterine manipulator must be completely understood in the particular context of laparoscopic surgery. In laparoscopy the access routes are limited and therefore each time an operator handles an instrument to expose tissues an access route is lost. Correct use of the uterine manipulator allows tissues to be well exposed, thus leaving the operating trocars free during the procedure.

In detail the manipulator permits:

- mobilization of the uterus (pulsion, lateral movements, anteversion, retroversion, on-axis rotation);
- good visualization of the vaginal fornices (allowing their identification while keeping the ureter clear);
- sealing of the pelvic aperture while opening the vagina;
- possible help in morcellating a large uterus at the end of the procedure;
- visualization of the vaginal cuff and sealing to facilitate vaginal closure.

The uterine manipulator plays an even more essential role when the hysterectomy is difficult. This may be the case with a large uterus, when correct use of the uterine manipulator will allow the procedure to be carried out with the best tissue exposure and a significant reduction in surgical risks.

Various uterine manipulators are available. We use a manipulator with a threaded distal tip which is "screwed" into the uterus. The threaded tip is chosen depending on the size of the uterus. Non-threaded tips are used in the case of malignant disease and these are simply advanced into the uterus.

The distal tip of the manipulator insert can be deflected at varying angles (0° to 90° relative to the main axis of the device); deflection is controlled with the main handle.

Inserting the manipulator into the uterus requires cervical dilatation up to bougie no. 9. The device is locked into the zero position and the manipulator insert is screwed in as far as the anatomical base guard. The anatomical base itself can be inserted into the cervical os, elevating the axis of flexion as far as the interior of the cervix.

The second component of the manipulator is the manipulator rod. For good visualization of the fornices the insert can be rotated through 360° exposing the whole circumference of the vagina. As it is made from a non-conductive material, it can be exposed to unipolar current without risk of an electric arc. The manipulator insert is available in various lengths and widths fitting all kinds of vaginal shapes. The lockable handle at the proximal end of the longitudinal axis allows the manipulator insert to be controlled precisely. The position of the proximal manipulator rod matches with the distal orientation of the insert. In this way, the assistant maintains constant visual control of the position of the manipulator insert. The combination of active deflection of the manipulator tip and on-axis rotation via the manipulator rod helps in reducing iatrogenic injuries to the ureter during laparoscopic hysterectomies.

Finally, the device has a sealing system consisting of 3 soft plastic discs; this has the advantage of not obstructing the vagina during final manipulations facilitating posterior opening of the vagina.

3.3 The Role of the Operating Team

The surgeon, located to the left of the patient, controls the instruments introduced through the central and left operating ports. The first assistant located to the right controls the camera and the instrument placed in the right trocar. The second assistant situated between the legs of the patient is seated and mobilizes the uterus by operating the uterine manipulator.

The surgeon usually begins the procedure by inserting bipolar forceps into the left trocar and scissors into the central trocar.

The scissors can be connected to the unipolar electro-surgical unit. It is advisable to use grasping bipolar forceps which permit to combine as many functions as possible in the same instrument. The operating surgeon thus has various functional options available to his two hands: on the left, manipulation, grasping and electrocoagulation; on the right, dissection, mechanical dissection and electrocoagulation.

The assistant inserts forceps, usually atraumatic forceps, in the right trocar.

3.4 The Round Ligaments

The first part of the procedure is the same for hysterectomy both with and without adnexectomy. It consists of coagulation and division of the round ligaments, followed by opening of the vesicouterine space with dissection of the bladder.

The second assistant mobilizes the uterus to the right without anteflexion, applying a well-measured thrust. The surgeon grasps the left round ligament at its origin anterolateral to the uterus and exerts traction to the right and upwards. This reveals a triangle bordered by the round ligament at the top, iliac vessels laterally, and adnexal vein medially. By placing the round ligament under tension, the center of this triangle

was exposed, made up of the juxtaposition of two anterior and posterior peritoneal layers of the broad ligament. This area appears grey owing to the presence of CO₂ and an empty space under the posterior leaf of the broad ligament. The surgeon should coagulate the round ligament at the center of this triangle. In this way, the surgeon keeps a safe distance from the adnexal vein and limits the risks of bleeding. The round ligament is divided in the midline by intermittent coagulation and section. It should be noted that an arteriole is sometimes present behind the ligament, and this must be carefully coagulated (**Figs. 1–3**).

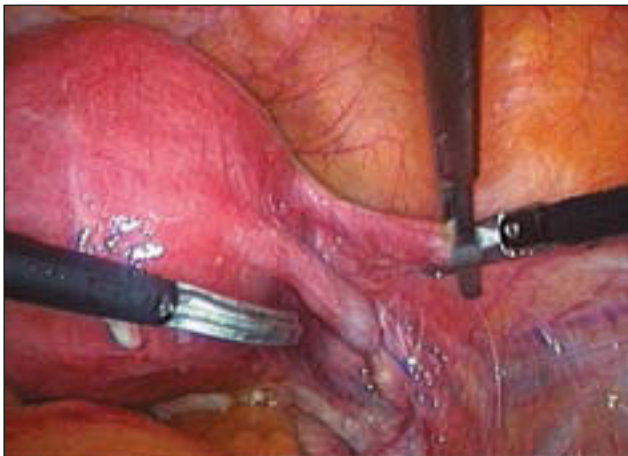


Fig. 1
Transection of the round ligament.

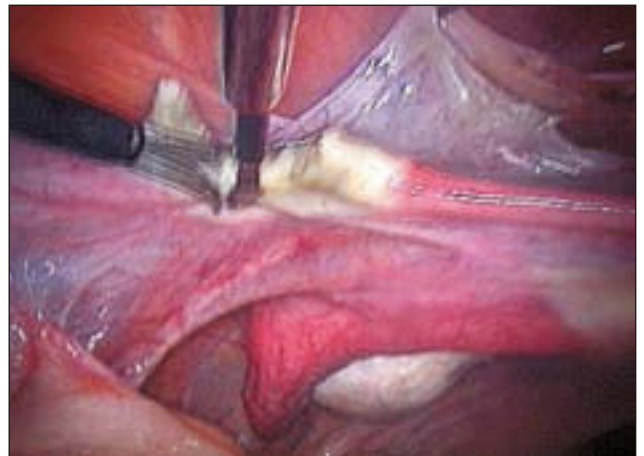

Fig. 2
Transection of the round ligament after bipolar coagulation.

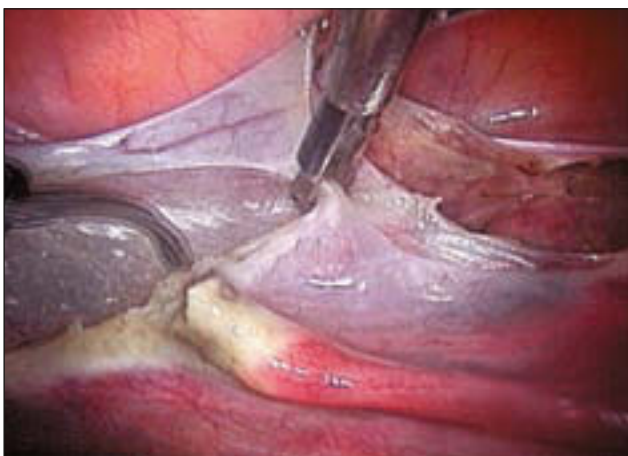


Fig. 3
A fenestration is created in the leaf of the broad ligament.

3.5 Dissection of the Vesicouterine Pouch

Once the round ligament has been transected, the access to the vesicouterine space is open.

The first assistant now directs traction downwards to provide a clear view and access to this space. The surgeon should then divide the vesicouterine peritoneum by simple traction. He introduces his two instruments into the prevesical space taking care to remain in contact with the peritoneum above; then, separating the instruments, he opens the space progressing downwards and inwards. The peritoneal capillaries are gradually coagulated. The peritoneum is divided using cold scissors or by coagulation and cutting in one step if the scissors are connected to the unipolar electro-surgical unit. This dissection should stop about 1 cm from the midline.

At this point the second assistant moves the uterus towards the surgeon, while the first assistant grasps the round ligament as close as possible to the wall. Traction to this ligament applied outwards and upwards creates the triangle described above.

The same technique is employed to reach about 1 cm from the midline. At this point the uterus is pushed upwards

and slightly retroverted while the first assistant grasps the prevesical peritoneum in the midline. It is grasped 1 cm below the junction of the peritoneum and the uterine serosa. It must be divided in a plane strictly perpendicular to the uterus while the latter is pushed firmly upwards to avoid any iatrogenic visceral injury. Ideally, the bipolar forceps, resting on the uterine isthmus, grasps the peritoneal falx and it is then divided with scissors in the same plane as far as the isthmus.

This action together with the momentum applied to the uterus automatically reveals the plane of vesicovaginal dissection once the incision has been made. When this plane is reached, blunt dissection of the bladder is carried downwards. The two internal bladder pillars are put under tension by upward traction on the bladder and are coagulated and dissected.

This space must be dissected carefully especially in the case of previous surgery, in particular previous cesarean section.

In these cases the first assistant must elevate the prevesical peritoneum well while the second assistant pushes the uterus. The surgeon must create a plane which is strictly

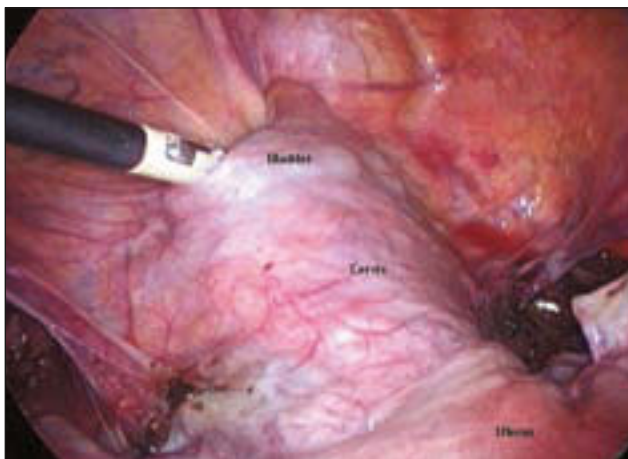


Fig. 4
Identification of the vesicouterine fold.

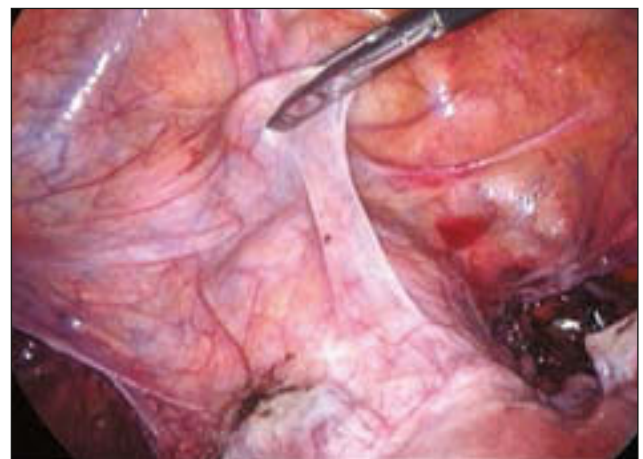

Fig. 5
The vesicouterine fold is elevated prior to being incised.

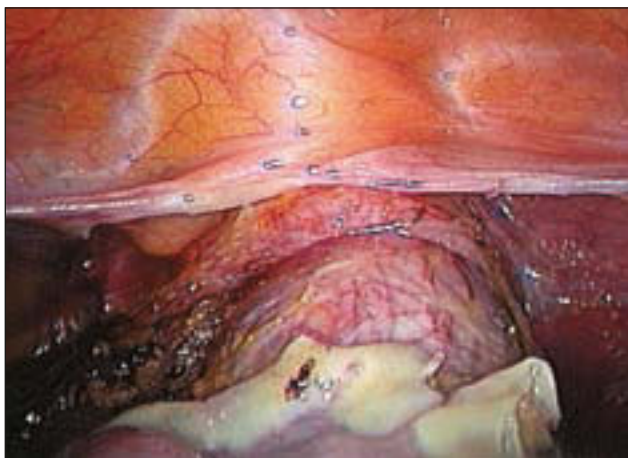


Fig. 6
Complete division of the vesicouterine peritoneum.

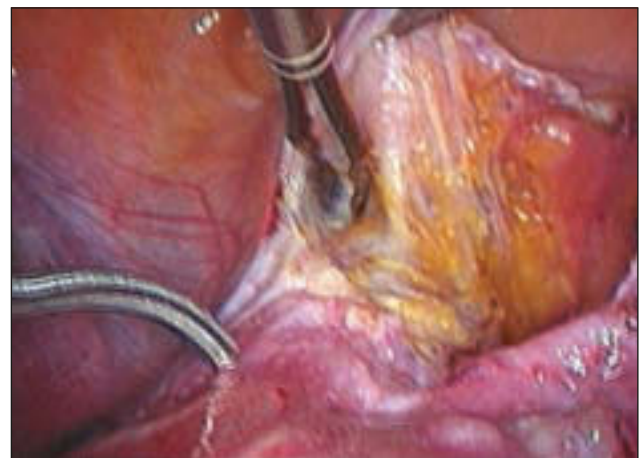


Fig. 7
Identification of the vesical pillars.

perpendicular to the uterus. During dissection of the left vesicouterine peritoneum, care must be taken as the surgeon, on the patient's left, has a tendency to dissect the

peritoneum too close to the bladder. To prevent this error, the uterus must be well centred and pushed slightly downwards by the second assistant (**Figs. 4–7**).

3.6 Fenestration of the Broad Ligaments

The surgeon now fenestrates the broad ligaments on the right and left. The uterus is again elevated and mobilized to the right, putting the left adnexa under tension. The surgeon carefully coagulates the capillaries of the broad ligament to separate the posterior leaf of the broad ligament. This should

appear grey, indicating that the intestine is not interposed behind it. The peritoneal leaf is opened by blunt dissection or is divided. Once the opening has been made, the surgeon's two instruments are introduced into the fenestration which is enlarged by divergent traction.

3.7 Treatment of the Adnexae

Hysterectomy without Adnexectomy

The opening is extended towards the uterosacral ligaments. In a total hysterectomy, it is extended towards the suspensory ligament of the ovary. Indeed, once the fenestration has been created, the ureter is found on the external side of the window (against the wall). Whatever technique is chosen to detach the adnexa or the suspensory ovarian ligament, the ureter is not endangered.

In a hysterectomy without adnexectomy, the adnexa may be coagulated and divided where it merges with the uterus by a succession of bipolar coagulations followed by division. For effective coagulation, it is preferable to set the power at 35 watts and to increase exposure time.

In hysterectomy without adnexectomy linear cutting staplers are most appropriate. In this case, a blue cartridge should be used (closed staple size equal to 1.5 mm). The stapler is best introduced via a 12 mm trocar situated in a high central position. As a general rule, a single cartridge is sufficient for the adnexal transection. Often a residual peritoneal adhesion must be lysed to complete the transection.

Today other instruments are also available which coagulate and cut simultaneously, either using ultrasound or radiofrequency. They can be helpful, especially in difficult hysterectomies, but using the bipolar modality is still the classic technique of choice.

Hysterectomy with Adnexectomy

The first assistant should grasp the ovary and put the suspensory ligament of the ovary under traction. The surgeon then coagulates and divides the ligament close to the ovary. Once the vascular pedicle has been divided and before completing division of the ligament, the traction is slightly reduced and any hemostasis completed. Once division is complete and the ligament has retracted, absolute hemostasis must be confirmed.

Adequate venous hemostasis must always be secured to order to avoid problems related to impeded vision, which can lengthen the duration of surgery.

3.8 Treatment of the Uterine Artery

Once the problem of the adnexa has been resolved, the uterine vascular pedicles are dissected. The objective is to produce an anatomical situation which separates the ureter from the pedicle of the uterine artery. The first step is posterior dissection. The uterus is first pushed upwards and to the right. The first assistant grasps the stump of the left round ligament and applies traction to it which is directed inwards.

In a total hysterectomy it may be preferable to apply traction to the adnexa. The surgeon applies traction to the posterior peritoneum by introducing the bipolar forceps between the posterior peritoneum and the base of the parametrium. The forceps moves in contact with the peritoneum towards the left cardinal and uterosacral ligaments. The peritoneum is separated by back-and-forth movements, releasing the parts of the parametrium which are moved clear. The peritoneum is then coagulated and divided.

Progression continues towards the uterosacral ligament. In the process the cardinal ligament is coagulated and cut, releasing the arch of the uterine artery which is isolated. The uterosacral ligament is sectioned in its turn. This step can be made easier by anteflexion of the uterus. The situation is

then as follows: the uterine arteries can be seen with behind them the vaginal fornix freed from the cardinal ligament.

The surgeon then moves to the front of the uterine pedicle. The uterus is slightly retroverted and pushed firmly upwards. Starting from the internal pillar of the bladder, all the tissue in front of the uterine pedicle is coagulated and divided.

At the end of this procedure the uterine pedicle stands out on the lateral surface of the uterine isthmus, between the vaginal fornices to the front and rear. The dissection is complete apart from the pedicle and the ureter is clearly visible.

The same technique is used on the opposite side. The uterus is moved to the left and the first assistant pulls the uterus towards the left via the stump of the round ligament. On this side, the angle of approach of the surgeon's instruments is often inadequate and, consequently, a risk of injury to the ureter can arise. To avoid this risk, the arrangement of instruments has to be changed: the bipolar forceps is given to the first assistant, the scissors are in the center and the forceps is moved to the left. The surgeon puts traction on the uterus via the stump of the right round ligament and the assistant carries out the same dissection as that carried out by the surgeon on the left. The surgeon retains control of the pedal.

In this way, the right and left uterine pedicles are treated. At the end of this step the ureters are at least 4 cm away from the ascending branch of the uterine artery where hemostasis will occur.

The uterine artery and vein can be dealt with using various techniques. The first hysterectomies were carried out using bipolar coagulation for the uterine vessels. The large number of cases treated successfully has demonstrated the efficacy of this technique. The only risk is electrical tissue damage extending to the ureter.

The rules to be observed to avoid injuries of the ureter are:

- issection as previously described so that the uterine vessels are dissected clear in front, to the sides and behind;
- coagulation should be applied only to the ascending branch of the uterine artery;
- the time of exposure to coagulation should be as brief as possible. Short repeated coagulation is preferable to long sustained coagulation;

- since coagulation makes the tissue resistant to the passage of current, this tissue should be resected and coagulation carried out again on non-coagulated tissue.

Technically, the assistant draws the uterus towards the right by means of the left arterial pedicle while the manipulator is pushed firmly upwards and to the right. Using the bipolar forceps in the left lateral trocar, the surgeon grasps the mass of the uterine pedicle at the level of the ascending branch. After global coagulation, the surgeon concentrates on the superficial layers which are then incised using little scissor cuts. The pedicle is thus incised gradually. This produces perfect coagulation of the veins of the periarterial uterine plexus and the artery is more easily seen and in turn coagulated and transected.

Once the artery has been divided, the surgeon should continue with dissection in front and behind to lower the pedicle beyond the boundary of the vaginal fornix. This is thus a true interfascial hysterectomy. During this step the last parts of the cardinal ligament are coagulated and divided.

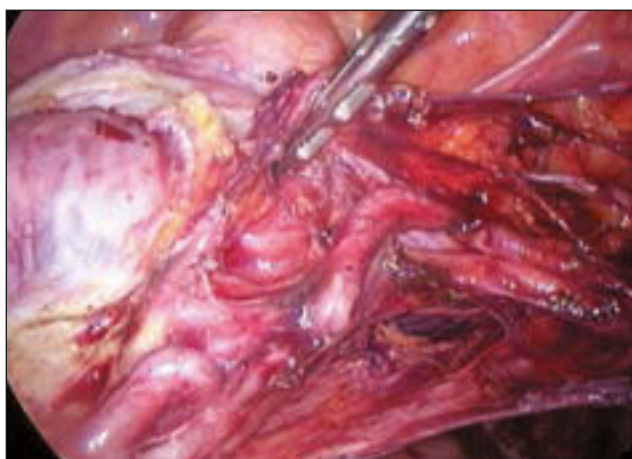

Fig. 8
Anatomic view of the uterine artery and relations with the ureter.

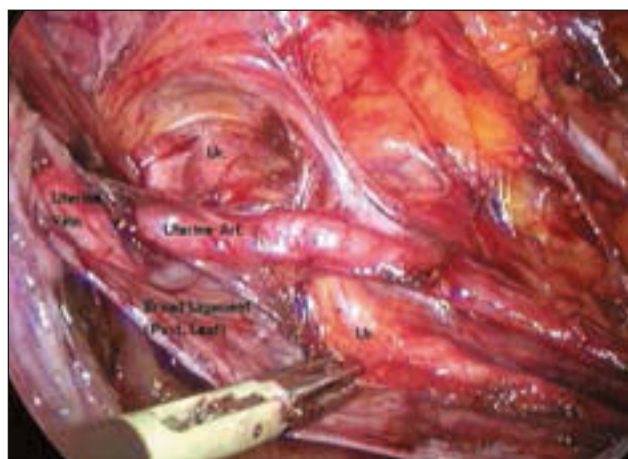

Fig. 9
Identification by careful dissection of the site where the uterine artery crosses the ureter.

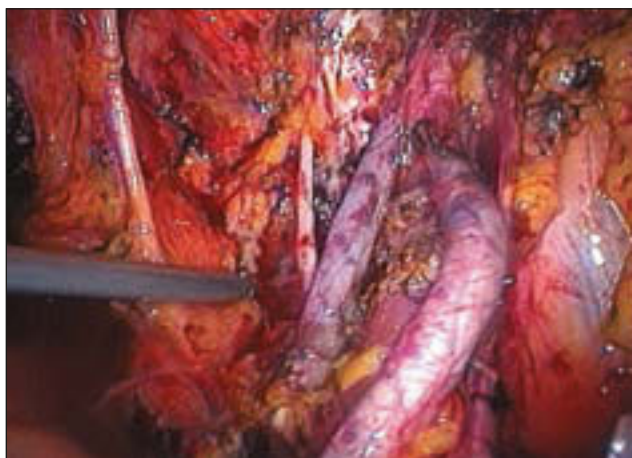

Fig. 10
Identification of the relations between the ureter and uterine artery.

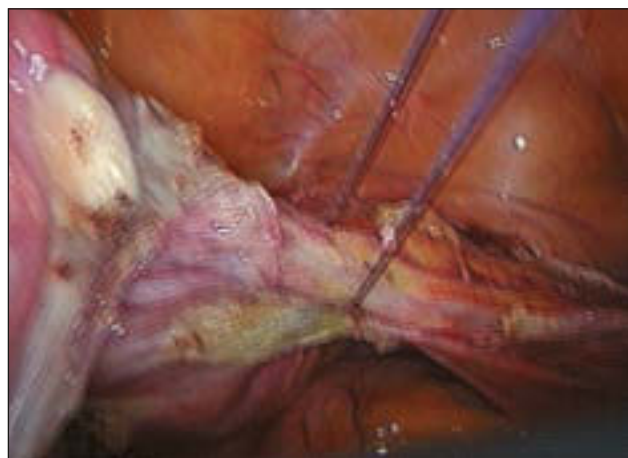


Fig. 11
Identification of the uterine artery and hemostatic suture.

The same procedure is used for the right pedicle. For the safety of the ureter it is important that the assistant uses the bipolar forceps. He can approach the pedicle perpendicular to the ascending portion and thus decrease the risk of injury to the ureter. Naturally, the surgeon retains control of the pedal.

The uterine pedicles may also be dealt with using ligatures or clips. Ligatures have the advantage of not requiring complete dissection of the artery. Once the dissection of the pedicle has been completed as described above, a 0 Vicryl suture attached to a curved 30 mm needle is passed through. It is simpler to pass from front to back of the pedicle on the left and from back to front on the right. The needle should penetrate from the dissected vaginal angle at the front and emerge in the posterior angle to avoid loading too much vagina behind the vessels. This would involve a risk of cutting the suture during subsequent interfascial dissection.

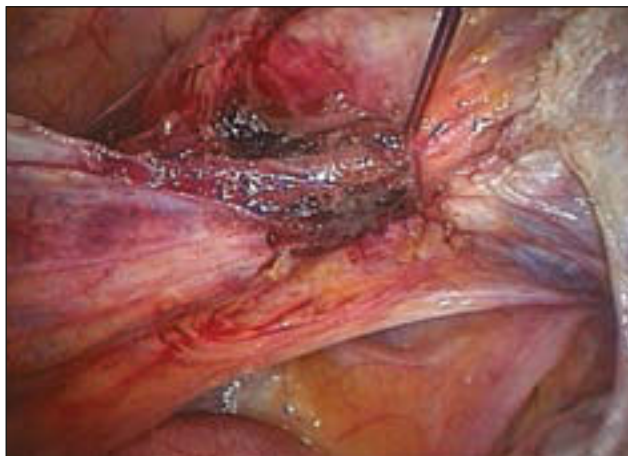

Fig. 12
Skeletonization of the uterine artery and extracorporeal laparoscopic suture.

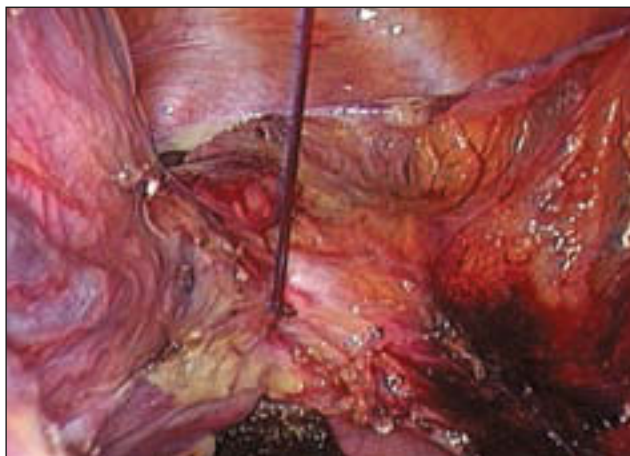


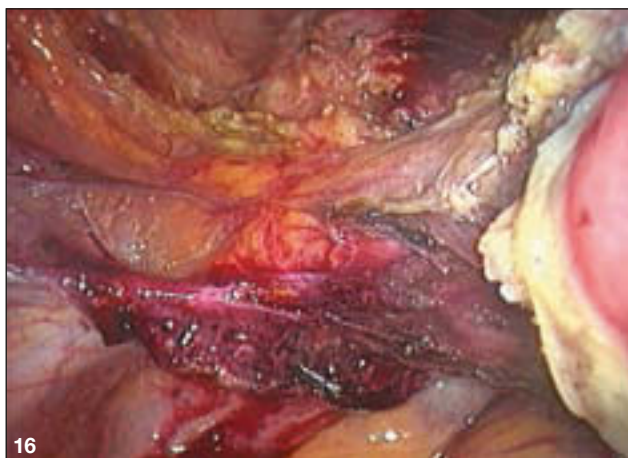
Fig. 13
The suture is applied to the vascular pedicle.

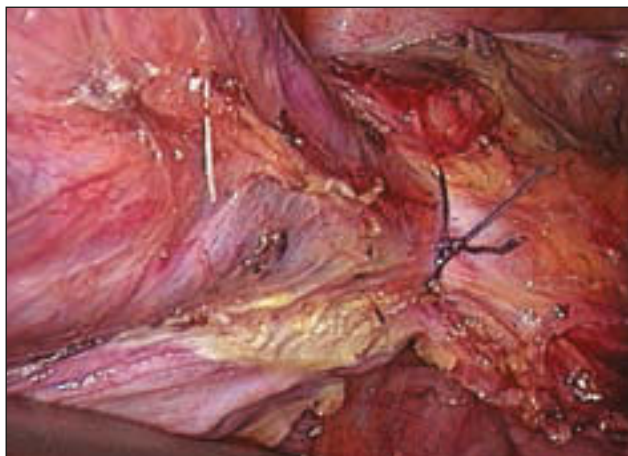
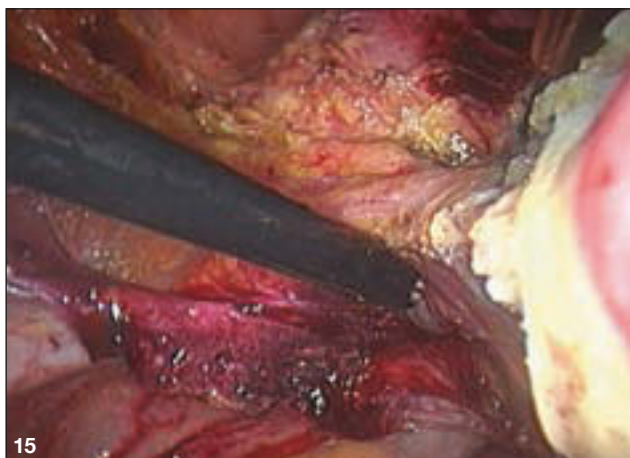
Fig. 14
Laparoscopic suture is preferable to bipolar coagulation if the uterine artery cannot be skeletonized perfectly.



15



16

Figs. 15–16
Coagulation with bipolar forceps is an optimal alternative for occluding the uterine artery.

In this case intracorporeal sutures seem to be contraindicated and it is preferable to use extracorporeal sutures, either half-hitches or Roeder knots. However, after cutting and isolating the uterine pedicle it is sometimes necessary to place a second ligature using an endoloop.

The use of sutures for the uterine pedicles seems to be particularly indicated in the case of a bulky uterus both for controlling hemostasis better and for reducing the risk of injury to the ureter, which is a major risk when the uterus is very large.

The use of clips requires dissection of the whole surface of the artery. There are two possible solutions: remaining with the ascending branch or starting at the point where the artery moves away from the uterus.

For the ascending branch, repeated coagulation of the peripheral veins around the artery should be carried out; then, by dividing them successively, the artery is exposed and clipped. Away from the uterus, the artery and vein are more easily separated. Dissection should be carried out with as little coagulation as possible due to the proximity of the ureter.

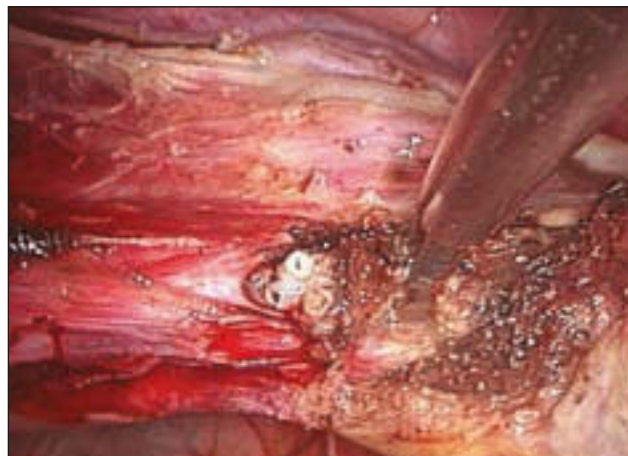

Fig. 17
In some cases, the openings of the uterine vessels can be identified perfectly.

In all cases the clip should be closed under visual control. The artery should be only partially blocked to confirm the efficacy of the clip (**Figs. 8–17**).

3.9 Opening and Division of the Vagina

At this point in the operation the uterus is no longer vascularised and becomes pale. The uterine manipulator rod, which is turned through 360°, shows that the uterine pedicles have been dissected lower than the vaginal fornices.

The sealing ceramic cylinder of the manipulator is advanced into the vagina, after being lubricated with gel or vaseline oil. The three silicone seals that can be mounted to the cylinder should be inside the vagina. The surgeon must open the vagina through 360°. The more the vagina is open the more the second assistant loses control of the uterus with the manipulator.

Usually the incision is started from the anterior vaginal wall. At the start the surgeon is equipped with the bipolar forceps on the left and disposable scissors in the centre. For the incision the scissors are connected to the monopolar current. The first assistant uses a suction cannula to aspirate blood and evacuate the smoke generated by the high frequency current. The second assistant manipulates the uterus using the rod to expose the various parts of the vagina to the surgeon for division.

He does this by rotating the rod in the same direction as the division. It is important that the rod should be rotated before

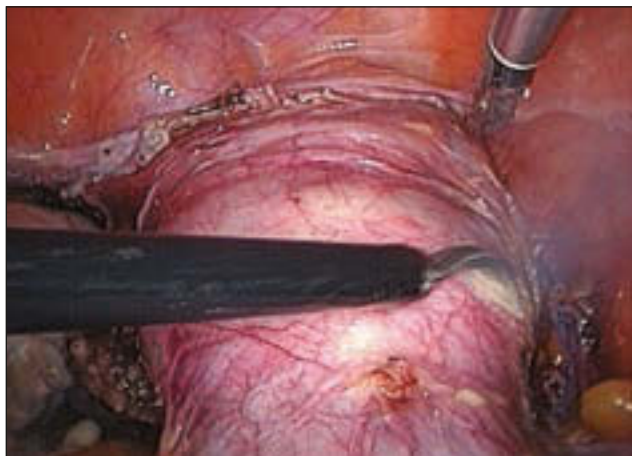

Fig. 18
Dividing the vagina with the high frequency unipolar electrode.

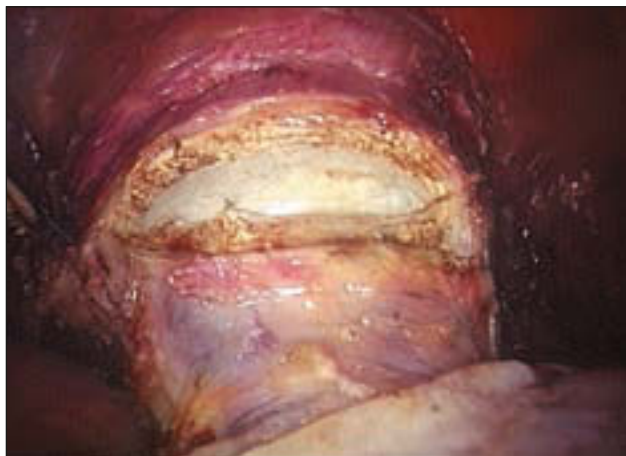

Fig. 19
The incision follows the porcelain margin of the uterine manipulator.

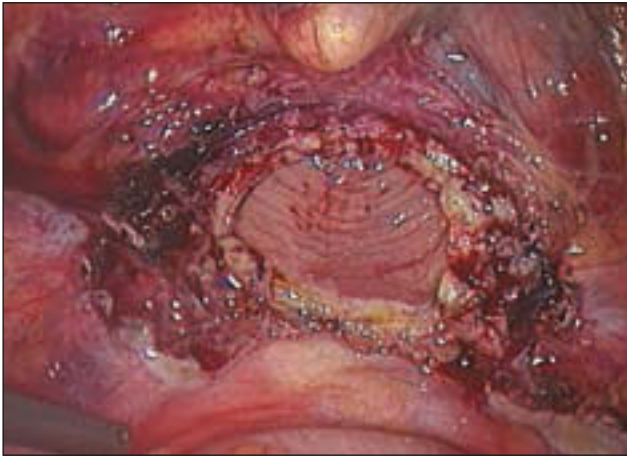


Fig. 20
After vaginal extraction of the uterus, the opening must be sutured.

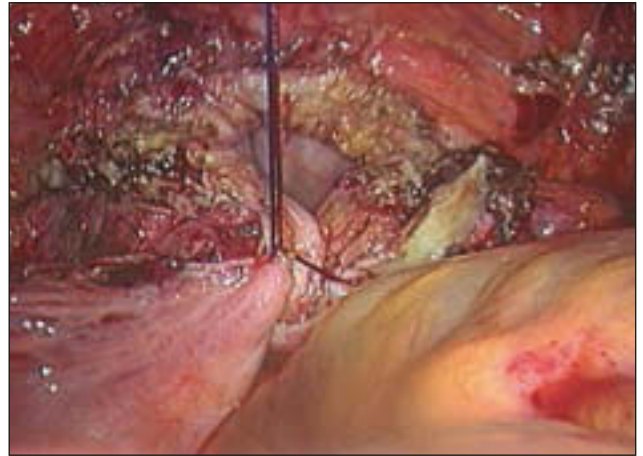


Fig. 21
Laparoscopic suture of the vaginal opening.

the surgeon has completed the division as far as the angle of the rod. If this is not the case, the rod will escape from the edge of the fornix and penetrate into the abdominal cavity. Correct repositioning of the manipulator rod may thus result in loss of the pneumoperitoneum.

During division, it may be necessary for the surgeon to move the scissors to the left trocar to gain better access for dividing the fornix (**Figs. 18–20**).

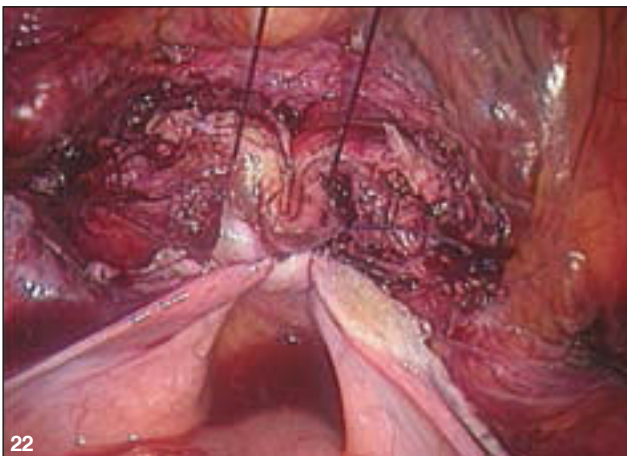
3.10 Extraction of the Uterus and Vaginal Closure

Once the uterus has been freed, if it is of normal size, it is easily extracted via the colpotomy. The second assistant draws the uterus into the vagina; in this way, the pneumoperitoneum seal is maintained and the edges of the vagina are presented for closure.

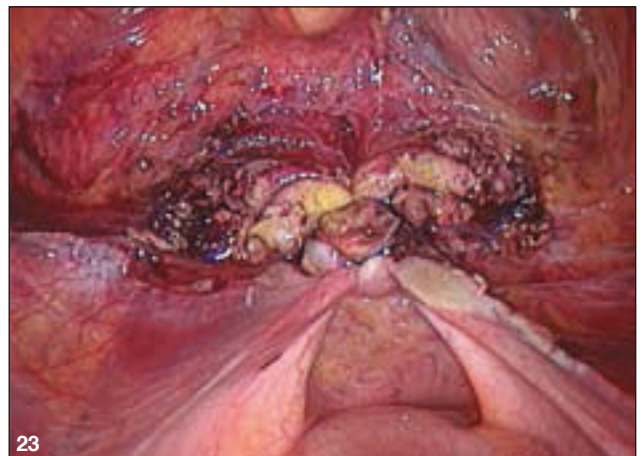On the other hand, if the uterus is large, it must be morcellated before extraction. Morcellation may be performed via the vaginal or laparoscopic routes, using a laparoscopic scalpel with a retractable blade. The uterus is either hemisected or morcellated and can then be extracted through the vagina.

The vagina may be closed via the vaginal or laparoscopic approach. Normally the laparoscopic approach is preferable

because the vaginal approach requires the patient to be repositioned, which involves a loss of time. For laparoscopic suturing, a glove filled with gauze swabs placed in the vagina is the best means of maintaining the pneumoperitoneum. Suturing is usually carried out with a no. 0 or 1 thread, attached to a curved 30–36 mm needle. The surgeon inserts the needle straight into the needle holder of the left trocar. He pierces the upper lip of the vagina in the centre of the colpotomy which is presented by the assistant. He then holds this lip by half rotating the needle upwards. The assistant then presents the posterior edge of the vagina which is in turn pierced. It is essential to transfix the vagina completely to produce total haemostasis. The surgeon repeats this



Figs. 22–23
The two uterosacral ligaments are anchored with the laparoscopic vaginal suture.



operation to produce an X suture. As a rule, extraction of the thread poses no problem. This suture is placed on the right and left. There are thus two X sutures taking in the center and then the angle of the colpotomy on either side.

In some cases a third central X stitch may be made which also includes the ends of the uterosacral ligaments to provide better support for the vaginal vault. Removal of the uterus or the intravaginal glove acts as a test of the seal.

We prefer to use extracorporeal sutures for closing the vagina, but intracorporeal sutures may also be used. In this case, it is

advisable to use two semicontinuous sutures which will then be joined in the middle of the suture. It is also advisable in this case, to strengthen the vaginal vault by including the end of the uterosacral ligaments in the suture.

A final lavage completes the operation. Bleeding of the vaginal section is carefully dealt with using bipolar current. The ureters can then be checked. Peristalsis is not a guarantee of their integrity, but the combination of an absence of dilatation and presence of peristalsis means that the risk of injury is unlikely (**Figs. 21–23**).

4.0 Subtotal Hysterectomy

In general we prefer total hysterectomy, except where the hysterectomy is associated with the management of a uterine prolapse or a suprapubic suspension operation.

In any case, in a subtotal hysterectomy the cervix is divided at the isthmus after dealing with the uterine arteries. This

division may be performed in various ways. We prefer to use a cold scalpel with an endoscopic blade holder. Closure of the uterine cervix is carried out with interrupted Vicryl 0 stitches.

5.0 Postoperative Care

Antibiotic Treatment

All patients receive a single dose of antibiotics during the operation. Postoperative treatment is not systematic in our experience. We only treat infections confirmed after taking samples and an antibiogram.

Prevention of Postoperative Thrombophlebitis

Our patients systematically receive prophylactic antithrombotic treatment. Low dose heparin is started on the day of admittance prior to surgery and is continued for 15 days.

Period of Foley catheterization

This is continued only for the duration of the operation except in cases with associated subpubic suspension.

Length of hospital stay

This varies from 2 to 3 days.

Postoperative Hygiene

In the postoperative period, the patient should avoid effort, at least for the first month. Sexual activity should not recommence until after the first postoperative check-up, one month after surgery.

6.0 Conclusions

We started to perform total laparoscopic hysterectomy in 1989, but only in 1995, with the introduction of the uterine manipulator, did our technique become standardized and reproducible. The operating technique is now well established and this surgical guide, in our opinion, should allow a laparoscopic hysterectomy to be carried out completely safely. A final consideration is that even if hysterectomy is

regarded as a basic procedure for a gynecological surgeon, it should be considered an advanced procedure if performed through the laparoscopic approach. This does not indicate any real difficulty in the procedure but rather a poor understanding of laparoscopic surgical technique which should nowadays be an integral part of the basic knowledge of the gynecological surgeon.

Recommended Reading

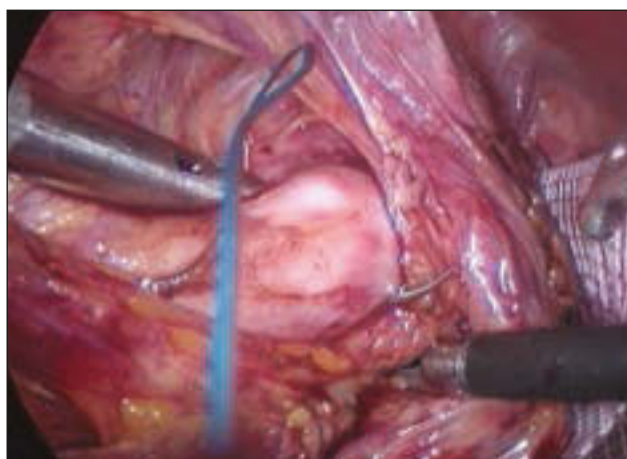
1. WATTIEZ A, CANIS M, POULY JL, MAGE G, BRUHAT MA: Technique coelioscopique de l'hystérectomie. *Journal de Coelochirurgie*. 1996 Sep; 19: 19-27.
2. REICH H.: Laparoscopic hysterectomy. *Surg Laparosc Endosc*. 1992 Mar; 2(1): 85-8.
3. WATTIEZ A, GOLDCHMIT R, DURRUTY G, MAGE G, CANIS M, CUCINELLA G, POULY JL, BRUHAT MA: Minilaparoscopic hysterectomy. *J Am Assoc Gynecol Laparosc*. 1999 Feb; 6(1):97-100.
4. WATTIEZ A, SORIANO D, COHEN SB, NERVO P, CANIS M, BOTCHORISHVILI R, MAGE G, POULY JL, MILLE P, BRUHAT MA: The learning curve of total laparoscopic hysterectomy: comparative analysis of 1647 cases. *J Am Assoc Gynecol Laparosc*. 2002 Aug; 9(3):339-45.
5. WATTIEZ A, SORIANO D, FIACCAVENTO A, CANIS M, BOTCHORISHVILI R, POULY J, MAGE G, BRUHAT MA: Total laparoscopic hysterectomy for very enlarged uteri. *J Am Assoc Gynecol Laparosc*. 2002 May; 9(2):125-30.
6. WATTIEZ A, COHEN SB, SELVAGGI L: Laparoscopic hysterectomy. *Curr Opin Obstet Gynecol*. 2002 Aug; 14(4):417-22. Review.
7. CHAPRON C, DUBUISSON JB, ANSQUER Y: Total laparoscopic hysterectomy. Indications, results, and complications. *Ann N Y Acad Sci*. 1997 Sep 26; 828:341-51. Review.
8. CHAPRON C, DUBUISSON JB: Total hysterectomy: laparoscopy or vaginal route? Arguments in favor of laparoscopy *Gynecol Obstet Fertil*. 2000 Sep; 28(9):672-8.
9. CHAPRON C, DUBUISSON JB.: Ureteral injuries after laparoscopic hysterectomy. *Hum Reprod*. 2000 Mar; 15(3):733-4.
10. COSSON M, LAMBAUDIE E, BOUKERROU M, QUERLEU D, CREPIN G.: Vaginal, laparoscopic, or abdominal hysterectomies for benign disorders: immediate and early postoperative complications. *Eur J Obstet Gynecol Reprod Biol*. 2001 Oct; 98(2):231-6.
11. DONNEZ J, SQUIFFLET J, JADOUL P, SMETS M: Results of evaluate study of hysterectomy techniques: high rate of complications needs explanation. *BMJ*. 2004 Mar 13; 328(7440):643.
12. KOH CH.: A new technique and system for simplifying total laparoscopic hysterectomy. *J Am Assoc Gynecol Laparosc*. 1998 May; 5(2):187-92.
13. KOH LW, KOH PH, LIN LC, NG WJ, WONG E, HUANG MH: A simple procedure for the prevention of ureteral injury in laparoscopic-assisted vaginal hysterectomy. *J Am Assoc Gynecol Laparosc*. 2004 May; 11(2):167-9.
14. KOVAC SR, BARHAN S, LISTER M, TUCKER L, BISHOP M, DAS A.: Guidelines for the selection of the route of hysterectomy: application in a resident clinic population. *Am J Obstet Gynecol*. 2002 Dec; 187(6):1521-7.
15. AL-JUBOURI MA.: Laparoscopic assisted vaginal hysterectomy versus abdominal hysterectomy. *Ann Clin Biochem*. 1998 Jan; 35 (Pt 1):156-7.
16. GARRY R, FOUNTAIN J, MASON S, NAPP V, et al: The eVALuate study: two parallel randomized trials, one comparing laparoscopic with abdominal hysterectomy, the other comparing laparoscopic with vaginal hysterectomy. *BMJ*. 2004 Jan 17; 328 (7432): 129.
17. SCULPHER M, MANCA A, ABBOTT J, FOUNTAIN J, et al: Cost effectiveness analysis of laparoscopic hysterectomy compared with standard hysterectomy: results from a randomised trial. *BMJ*. 2004 Jan 17; 328 (7432): 134.
18. LIU CY, REICH H.: Complications of total laparoscopic hysterectomy in 518 cases. *Gynecol Endosc*. 1994; 2:203-8.
19. CANIS MJ, WATTIEZ A, MAGE G, BRUHAT MA.: Results of eVALuate study of hysterectomy techniques: laparoscopic hysterectomy may yet have a bright future. *BMJ*. 2004 Mar 13; 328(7440):642-3.
20. CHAPRON C, LAFOREST L, ANSQUER Y, FAUCONNIER A, FERNANDEZ B, BREART G, DUBUISSON JB: Hysterectomy techniques used for benign pathologies: results of a French multicentre study. *Hum Reprod*. 1999 Oct; 14(10):2464-70.
21. DAVIES A, HART R, MAGOS A, HADAD E, MORRIS R.: Hysterectomy: surgical route and complications. *Eur J Obstet Gynecol Reprod Biol*. 2002 Sep 10; 104(2): 148-51.
22. HARKKI P, KURKI T, SJOBERG J, TIITINEN A.: Safety aspects of laparoscopic hysterectomy. *Acta Obstet Gynecol Scand*. 2001 May; 80(5):383-91. Review.
23. HERTEL H, KOHLER C, MICHELS W, POSSOVER M, TOZZI R, SCHNEIDER A.: Laparoscopic-assisted radical vaginal hysterectomy (LARVH): prospective evaluation of 200 patients with cervical cancer. *Gynecol Oncol*. 2003 Sep; 90(3):505-11.
24. LYONS TL.: Laparoscopic supracervical hysterectomy. *Obstet Gynecol Clin North Am*. 2000 Jun; 27(2):441-50. Review.
25. MALZONI M, PERNIOLA G, HANNUNA K, IUELE T, FRUSCELLA ML, BASILI R, EBANO V, MARZIANI R.: A review of 445 cases of laparoscopic hysterectomy: benefits and outcome *Clin Ter*. 2004 Jan; 155(1):9-12.
26. MEEKS GR, HARRIS RL.: Surgical approach to hysterectomy: abdominal, laparoscopy-assisted, or vaginal. *Clin Obstet Gynecol*. 1997 Dec; 40(4):886-94. Review.
27. PARKER WH.: Total laparoscopic hysterectomy. *Obstet Gynecol Clin North Am*. 2000 Jun; 27(2): 431-40. Review.
28. POSSOVER M.: Options for laparoscopic surgery in cervical carcinomas. *Eur J Gynaecol Oncol*. 2003; 24(6):471-2. Review.
29. WOOD C.: The AAGL classification system for laparoscopic hysterectomy. *J Am Assoc Gynecol Laparosc*. 2000 Feb;7(1):5-7.

Chapter XVI

**Laparoscopic Surgery
of the Pelvic Floor**

Arnaud Wattiez

Strasbourg University Hospital
Strasbourg, France



1.0 Introduction

The laparoscopic management of uterine prolapse began in our department in 1991 and there has been considerable development in the technique since then. It was initially limited to faithful reproduction of the techniques employed at laparotomy but numerous complementary features were added subsequently, allowing us to deal with any circumstances that arise during female prolapse surgery.

The common benefits of the laparoscopic approach, such as rapid postoperative recovery and short hospitalization, were soon surpassed by the innovative aspect of this technique. Indeed, the combined effects of various factors – mainly,

the outstanding quality of videoendoscopic images and the positive pressure of the pneumoperitoneum – have granted access to anatomical spaces that were hitherto very difficult to reach and allows surgical repair under direct visual control.

The results, which were encouraging overall, are now excellent owing to repair surgery that is perfect from the anatomical aspect and provides exceptional functional results.

The only issue that remains to be resolved is to simplify this technique so that it can be performed in acceptable operating times.

2.0 Preoperative Workup

Preoperative workup must be particularly careful and precise. Only a thorough evaluation of all defects that need to be treated will allow surgical repair in a single operative session and minimize the risks of postoperative functional sequelae and recurrences.

2.1 Assessment of Uterine Prolapse

Diagnosis of all the defects is the crucial moment of the clinical workup. It is essential to stage the defects for each

compartment. Standard clinical examination must attempt to define the degree of prolapse involving the uterus, bladder and rectum. Lateral cystocele with the vaginal rugae preserved must be distinguished from central cystoceles with elimination of the vaginal rugae. The former is due to detachment of the vagina from the tendinous arc of the pelvic fascia while the latter is due to a break of the vesicovaginal fascia. A systematic exploration must make sure that any enterocele is detected. The muscular tonus of the levator ani muscles must be assessed in terms of quality and quantity.

3.0 Preparation of the Patient

Preparation of the patient is essential to obtain optimum results from this type of surgery. Preparation of the vaginal tissues to promote healing and bowel preparation to optimize the endoscopic space are particularly useful.

3.1 Bowel Preparation

The purpose of this preparation is to empty the bowel so that the loops of intestine can be better seen and to deflate and flatten them to increase intra-abdominal space. However, it can also be useful in the event of accidental bowel injury. Preparation begins with a classical low-fiber diet for the five days prior to surgery. Two evenings before the operation, a laxative Xprep® enema is administered. Finally, lavage of the lower bowel is performed the evening before surgery. This chronological order is particularly important in order to avoid anal leakage on the operating table during surgery, which exposes the patient to a greater risk of infection.

3.2 Vaginal Estrogens

Administration of vaginal estrogens for at least a month prior to the operation is useful for improving vaginal nutrition. Improvement of vaginal nutrition will allow better and faster healing.

3.3 Vaginal disinfection

Vaginal disinfection is particularly important and must be carried out the evening before the operation by vaginal lavage with an antiseptic solution and administration of a Betadine vaginal ovule. The abdominal wall is also disinfected. After a shower, the evening before the operation, the patient's pubic hair is shaved and the abdominal wall and inside the umbilicus are cleaned and disinfected with an antiseptic solution. Finally, immediately before surgery, a solution of Betadine is applied prior to sterile draping.

4.0 Positioning of the Patient

Laparoscopic surgery is often long and difficult. Optimizing the surgical technique and reducing operating times require ergonomic management of the operation, and correct arrangement of the patient is fundamental.

4.1 Anesthesia

General anesthesia with endotracheal intubation is usually employed. Muscle relaxation is necessary only where it is not possible to obtain sufficient distension of the abdominal wall with a pneumoperitoneum of 12 mmHg. General anesthesia can be combined with locoregional epidural or spinal anesthesia to improve the postoperative course.

4.2 Patient Positioning

The patient is placed in dorsal decubitus with the legs apart and semi-flexed. This position allows three surgeons to take up position: The operating surgeon is situated on the left of the patient. The first assistant stands opposite to the surgeon on the right side of the patient, and the second assistant is positioned between the patient's legs. The patient's two arms are placed alongside her body to avoid injuries of the brachial plexus. Shoulder braces are placed at the level of

the acromion prominence, avoiding compression of cervical muscles. Attention must also be paid to the position of the patient's hands to avoid compression of the fingers. In some cases, a warming system is used to prevent sudden drops in the patient's body temperature.

The patient must be positioned well down the table the better to allow movements of the uterine manipulator. The greater the possibilities for moving the uterine manipulator, the better will be the exposure of the different organs during surgery.

The abdominal wall and vagina are disinfected carefully and the operation area is prepared prior to introduction of the Foley catheter and uterine manipulator. It is imperative that the perineal region is sterile and accessible to the surgeon, who should perform a vaginal or rectal examination during the operation and position the uterine manipulator.

4.3 Bladder Catheterization

An indwelling no. 18 Foley catheter is placed. The balloon is inflated with 15cc of saline and the catheter is placed under traction to make it easier to demonstrate the bladder neck. The catheter is connected to a collecting bag which is placed in visible position so that the urine can be monitored (volume, color, presence of air in the bag).

5.0 Preoperative Assessment

5.1 Clinical Examination

It is absolutely essential to reassess the uterine prolapse on the operating table as soon as the patient is anesthetized. This reassessment under anesthesia can provide new information that may modify the operative strategy. The assessment is performed with the aid of vaginal dilators and will allow evaluation of the line of the vagina and better distinction of its upward and downward movements. This will also allow a better assessment of the retrovaginal space and its mobility.

In the event of hysterectomy, assessment of the size and mobility of the uterus will allow correct choice of trocar positions.

5.2 Appearance of the Abdomen

The patient's general build and the appearance of the abdomen determine the organization of the surgical field and the placement of the trocars. The ergonomics of the operative maneuvers will depend on this.

Numerous aspects must be considered:

1] **The patient's build.** The first thing to consider is the distance from the umbilicus to the pubic symphysis, which will determine the distance between the umbilical and suprapubic trocars. The latter, in particular, must be placed sufficiently high up to allow access to the promontory and the space of Retzius and allow the various sutures to be placed. If the patient is of short stature, the camera trocar must be placed in supraumbilical position and the suprapubic trocar is placed at umbilical level.

2] **The inter-iliac distance.** Suturing is facilitated by the position of the trocars. A short patient will mean that the trocars are positioned higher to gain space.

3] **The obesity of the abdominal wall** must be assessed because the trocars are easier to position where the wall is thinner. However, more elastic areas should be avoided because of the difficulty if they need to be reinserted.

4] **The laxity of the peritoneum** will give an idea of the operation space and the positioning of the trocars will therefore depend on this.

5.3 Placement of Trocars

In general, 4 trocars are necessary, three suprapubic (6 mm) and one umbilical (11 mm). The first trocar, 11 mm in diameter, is normally positioned at umbilical level. Following internal inspection and comparison of the size of the uterus and the patient's build, the final position of this trocar is defined. If the size of the uterus is normal or below normal and the pubis-umbilicus distance is sufficient, this trocar will be used for the laparoscope; if, on the contrary, the uterus is large and the pubis-umbilicus line is short, this trocar will be the central operating port. In the great majority of cases, the position is therefore as follows: three suprapubic trocars and one umbilical trocar.

- [1] **Suprapubic trocars:** we prefer to use mtp® disposable 6 mm trocars. They have the advantage of being light and transparent and being threaded on the outside, which ensures that they are stable in the abdominal wall; they have a star-shaped valve which prevents gas leakage even during suturing. Their cost is also acceptable. The lateral trocars are placed anterior to the anterior superior iliac spine, two fingers medial to the spine and lateral to the outer border of the rectus abdominis muscle. They are passed through the oblique and transverse abdominal muscles. At this level, the thickness of the abdominal wall is usually reduced which facilitates the maneuvers. The central trocar is positioned along the pubis-umbilicus line more or less in the middle. The minimum distance between the umbilical primary port and the central port is 6 cm. In any case, it should be positioned below a line joining the two outer trocars.
- [2] **The umbilical trocar** is a simple reusable trocar, which holds the laparoscope. In fact, this model has a valve, which can be lowered for introducing the laparoscope; this allows the distal lens to be kept clean during introduction so it is an economic factor with regard to efficient use of operating time. If the umbilical entry site is used as central port for operating instruments, we prefer the use of a disposable trocar with a removable reducer attached to the proximal end of the trocar.

In the classical situation (three suprapubic trocars and one umbilical trocar), we prefer to begin the operation with three 6 mm trocars for dissection and then replace the central trocar for suturing (after the hysterectomy is complete).

6.0 Organization of the Operating Field

6.1 Positioning of the Uterine Manipulator

The CLERMONT-FERRAND uterine manipulator is essential for demonstrating the uterus. It allows the uterus to be mobilized in all its axes: advance motion, anteversion, retroversion, lateralization and flexion of the uterus forwards and laterally. It also permits:

- exposure of the vaginal cul de sac
- maintenance of the pneumoperitoneum
- sealing of the vagina after extraction of the uterus

The device comprises a series of concentric rods. The central rod is threaded at the distal end, which is inserted in the uterus. The manipulator inserts are available in various sizes to match the size of the uterus. The threaded distal end of the insert can be deflected by use of the manipulator handle. Outside this rod there is a sealing ceramic cylinder, which can rotate through 360 degrees to allow exposure of the cul-de-sac. This cylinder can be mounted with three silicone seals. Once hysterectomy is complete, the manipulator with its silicone seals is pushed toward the vaginal vault preventing gas loss and making sure that pneumoperitoneum will be maintained.

The CLERMONT-FERRAND manipulator must be positioned when the patient is asleep and the operation area has been

prepared because the surgeon must be able to manipulate under completely aseptic conditions.

After demonstrating the cervix, hysterometry gives the size of the uterus so that the appropriate manipulator insert can be selected. The cervix is dilated with Hegar dilators up to size 8. With the manipulator locked in zero position, a twisting motion is applied to push the device through the cervical os until the threaded part of the insert is completely within the cervical canal. At the end of this maneuver, the handle locking mechanism must be on the right.

Most of the time, the manipulation movement must be preceded by a pushing movement in the direction of the patient's head. This is because anteversion of the uterus is achieved by a combination of two movements: pushing the uterus and anteversion by lowering the handle. In this way, the uterosacral ligaments are placed under tension and the cul-de-sac of the pouch of Douglas is exposed. The adnexae are exposed the same way with a movement of pushing and lateral deflection of the handle towards the patient's legs, which are in gynecologic lithotomy position.

The dilator can be pushed any time and allows correct exposure of the vaginal cul-de-sac.

6.2 Fixation of the Intestine

At the start of the operation, organization of the operation field is highly important to achieve stability and exposure without the assistant's intervention. The pouch of Douglas is exposed by fixing the sigmoid to the abdominal wall. For this maneuver, we use two different techniques. The first employs a nylon suture with a straight needle, which is introduced through the abdominal wall about 5 cm above the left lateral trocar. The needle then passes through the parasigmoid fat from one side of the sigmoid to the other and then comes out again through the abdominal wall through the same hole.

The sigmoid is elevated with the aid of forceps and the suture is tied on the outside. The same can be done with a curved needle introduced into the abdomen; the sigmoid fat is trans-fixed and the needle is then brought out again through the same trocar and the suture is then tied. A Reverden needle is then used to bring the sutures out transparietally always more or less 5 cm above the left lateral trocar and they are fixed using a forceps. In the same way, following hysterectomy, the vagina or remaining cervix can be suspended from the anterior wall using a Reverden needle.

6.3 Division of the Insertion of the Uterosacral Ligaments

The insertion of the uterosacral ligaments can be divided at the start of the operation. Culdoplasty commences from this point. They can be divided simply by touching them with bipolar coagulation or better with a suture.

7.0 Surgical Strategy Planning

The strategic order of the surgical steps is important and the phases of dissection must first be distinguished from the phases of fixation.

- **Phases of Dissection.** The chronological order is as follows: dissection of the promontory, right lateral peritoneal dissection, the rectovaginal space followed by hysterectomy, during which vesical dissection is pushed far downwards. This order is logical. Dissection of the promontory first is essential and to do this, an increased Trendelenburg position is important, which is often possible only at the start of the operation. Once this dissection is complete, the patient can be placed level if required by the anesthetist. Dissection of the spaces where the meshes will be placed is made easier by the presence of the manipulator, which assists access to the different spaces; this is therefore performed prior to hysterectomy.
- **Phases of Fixation.** The posterior mesh is fixed first and culdoplasty is performed before the mesh is fixed anteriorly. Low peritonization is then carried out until half of the right peritoneal opening is closed. At this point, the need for Burch colposuspension is assessed.
- If the classical technique is desired with suspension of the bladder neck before fixation of the mesh to the promontory, the meshes are left free until the Burch procedure and any vaginal repair are performed. More often, it is fixed to the promontory; this is followed by peritonization and cervical suspension is then performed in a further step.

8.0 Operative Technique

8.1 Dissection of the Sacral Promontory

The surgical approach to the promontory is best made when the patient is in increased Trendelenburg position after displacing the loops of intestine and fixing the sigmoid to the abdominal wall. A position between L5-S1 or the upper part of S1 is identified, where the common anterior vertebral ligament can be viewed. The middle sacral artery and vein are exposed and coagulated if necessary. In obese patients or those with a low aortic bifurcation, dissection begins from the left common iliac vein. The promontory is identified by instrumental palpation. After identifying the right ureter and the inferior border of the left common iliac vein, the posterior prevertebral parietal peritoneum is drawn upwards by the assistant and incised vertically towards the right ureter starting from the promontory. Once the peritoneum has been opened,

7.1 Hysterectomy

Classically, the uterus is left in position to avoid opening the vagina with the risk of infecting the mesh. This technique is possible by the laparoscopic route; the spaces are dissected with sparing of the round ligaments and with the meshes crossed by the broad ligaments. The current trend is to perform total or subtotal hysterectomy. In our experience subtotal hysterectomy has proven better because the vagina is not opened. In the case of total hysterectomy, the vaginal vault is closed in two layers.

As stated above, the essential difference compared with a simple hysterectomy is the chronology of the operating phases. When treating a prolapse, dissection of the rectovaginal and vesicovaginal spaces needs to be performed first, and the uterus is removed only after all these spaces have been dissected.

7.2 Preoperative Antibiotic Prophylaxis

Our patients usually receive preoperative antibiotic prophylaxis consisting of an injection of a recent generation cephalosporin; this is repeated if the operation takes more than 4 hours.

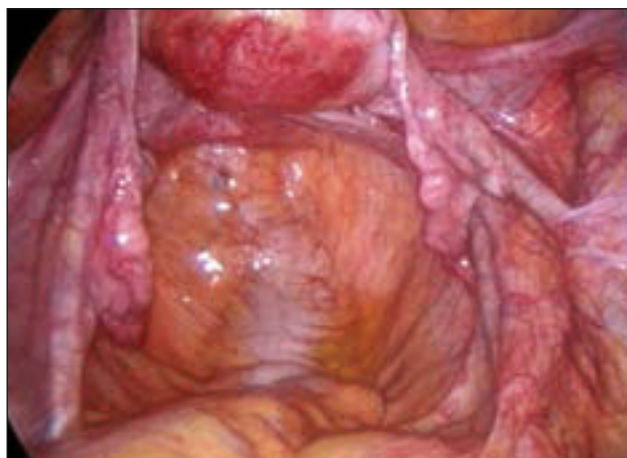

Fig. 1
Panoramic view of the pelvis.

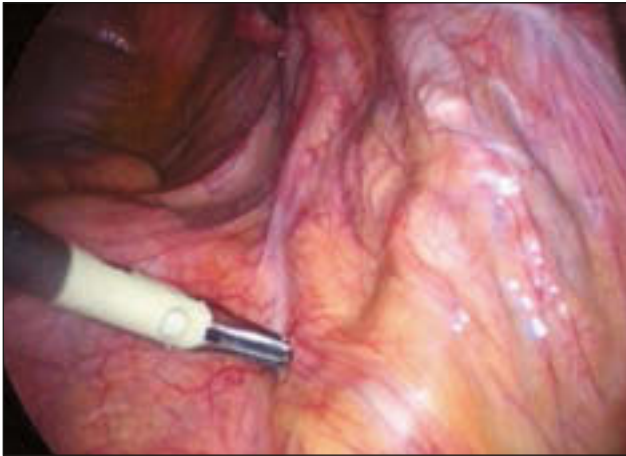

Fig. 2
Identification of the right ureter.

the pneumoperitoneum gas enters the retroperitoneal space, providing an initial dissection. The organs adherent to the posterior plane remain fixed while movable structures are moved away from the promontory (Figs. 1–4).

8.2 Incision of the Right Lateral Peritoneum

The dissection follows a vertical axis as far as the cul-de-sac of the Douglas pouch. In the course of this dissection, attention should be paid to the internal iliac vein, which is crossed, and to the area of the uterosacral ligament, which is usually difficult to dissect. This incision, which is made to enable peritonization of the mesh, must free the ureter. This is mobilized from the peritoneum to gain tissue so that the mesh can later be covered without stretching the ureter.

8.3 Dissection of the Rectovaginal Space

The junction of the uterosacral ligaments with the uterus is divided. The rectum is elevated and at the same time stretched towards the sacrum by the assistant with the aid of intestinal forceps. The peritoneum is put under tension, coagulated and then divided two centimeters above the insertion in the uterus. Dissection continues as far as the posterior vaginal wall which facilitates the access to the rectovaginal junction. Dissection is carried downward remaining in contact with the vagina anteriorly until the perineal body is reached. At this point, dissection is directed laterally towards the pelvic wall where the subobturator area is reached. In this lateral area, the median rectal vessels will be found and can be left intact or coagulated depending on the space available. At this

8.4 Hysterectomy

The technique of hysterectomy is as follows:

- Placement of the uterine manipulator
- The various phases of dissection are part of the preparation of the bed required for placing the mesh: the vesicovaginal and rectovaginal space.
- Coagulation and division of the round ligaments and dissection of the lateral vesical spaces. Fenestration of the posterior leaf of the broad ligament.

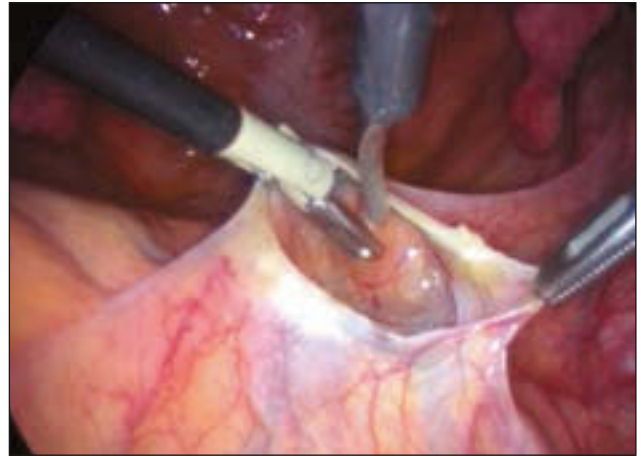


Fig. 3
Incision of the peritoneum at the level of the sacral promontory.

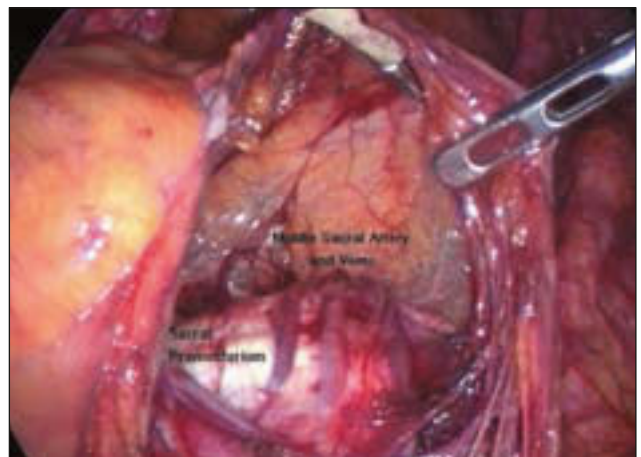


Fig. 4
Identification of the various structures at the level of the sacral promontory.

point, the surgeon turns again towards the rectum to identify the rectopubic bundles of the levator ani muscles. At the end of the dissection, it is important that the levator ani muscles (pubococcygeus, puborectalis, and iliococcygeus) can be identified. The dissected space is bounded by:

- the levator ani muscles and the pelvic wall laterally
- the perineal body inferiorly
- the vagina anteriorly
- the rectum posteriorly (Figs. 5–8).

- Integrity of the adnexae may be preserved or not, depending on the patient's age. The utero-ovarian ligament, tube and adnexal vessels are coagulated and dissected if the adnexae are to be spared, whereas the lumbo-ovarian ligament is coagulated and dissected if the adnexae are to be removed.

- Bladder dissection is taken lower than normal to facilitate placement of the mesh.

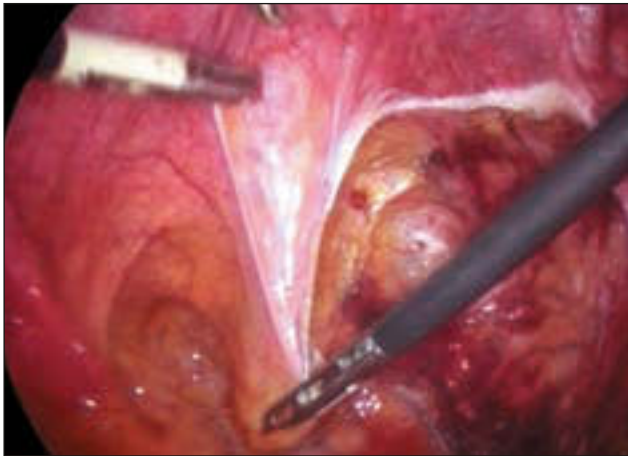


Fig. 5
Dissection of the rectovaginal space.

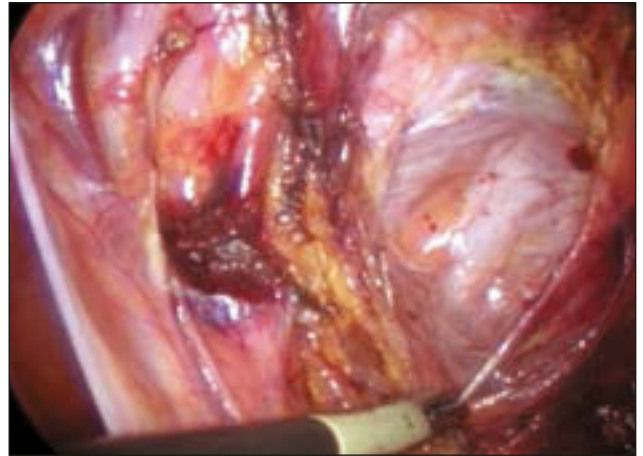


Fig. 6
Identification of the levator ani muscles.

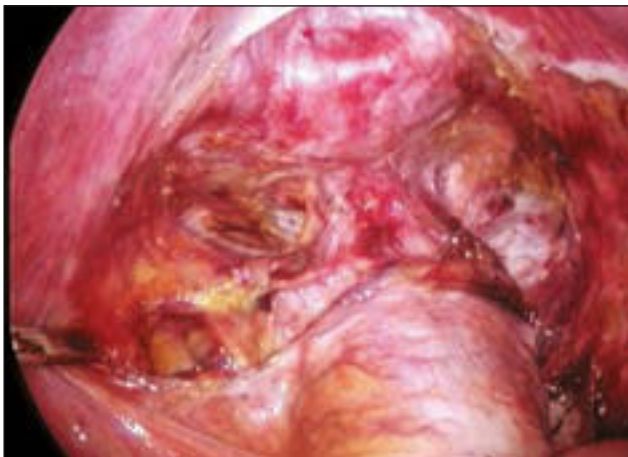

Fig. 7
Posterior dissection complete.

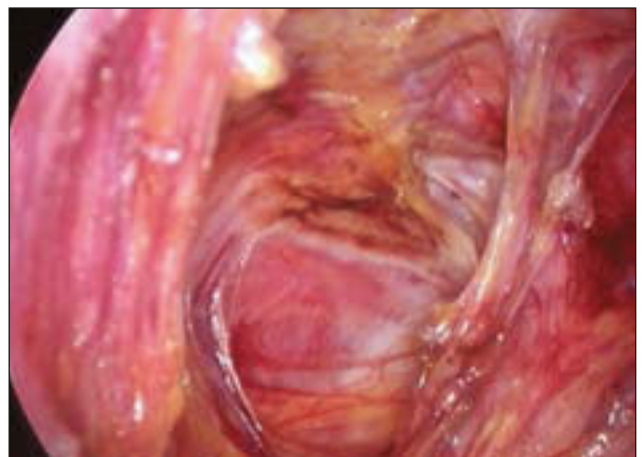

Fig. 8
Left levator muscles.

- Dissection of the posterior leaf of the broad ligament as far as the origin of the uterosacral ligaments.
- Identification of the uterine pedicles, which are coagulated with bipolar forceps or ligated with 0 Vicryl®.
- Intrafascial dissection with coagulation of the cervicovaginal vessels. If total hysterectomy is being performed, Halban's fascia must be identified to allow closure in two planes.
- Opening of the vagina through 360° under the guidance of the uterine manipulator.

- Extraction of the uterus via the vagina
- Two-layer suture of the vagina: the first layer takes only the vaginal mucosa and the second approximates the pericervical fascia. A 0 Vicryl® suture is used. These two layers are essential to protect the mesh against contamination of vaginal origin.
- If a subtotal hysterectomy is being performed, the cervix is divided at the level of the isthmus after coagulating the uterine vessels. Division of the cervix can be performed in various ways. We prefer to use a cold knife held in an endoscopic blade holder.

8.5 Fixation of the Posterior Mesh

The posterior portion of the mesh is fixed first.

Once the hysterectomy has been completed, it is convenient to suspend the vagina to the anterior abdominal wall so that the assistant's instrument is more readily available for suturing.

Each of the levator ani muscles is included in the suture using Ethibond® 0 on a 30 mm-needle. The mesh is fixed on both lateral sides. At this point, myorrhaphy is performed; this

should never be total but should rather be a partial closure of the inter-levator hiatus. This closure is more or less complete depending on the situation. It will constitute the low support point where the vagina will be attached. Once the mesh has been stretched between the left-side and right-side puborectalis muscles, the hiatus between the mesh and the vagina is closed by suturing the mesh to the vaginal wall at the level of the perineal body.

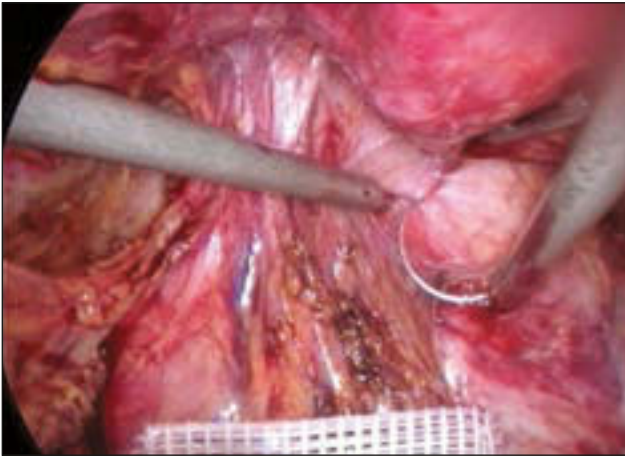

Fig. 9
Placement of the suture in the right puborectalis muscle.

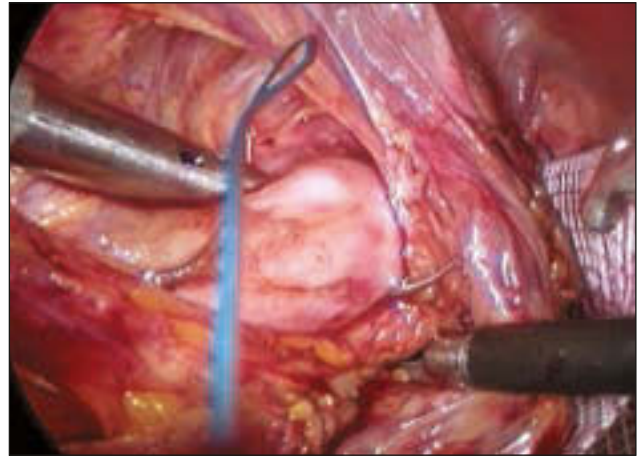


Fig. 10
The left levator muscle is picked up with the needle.

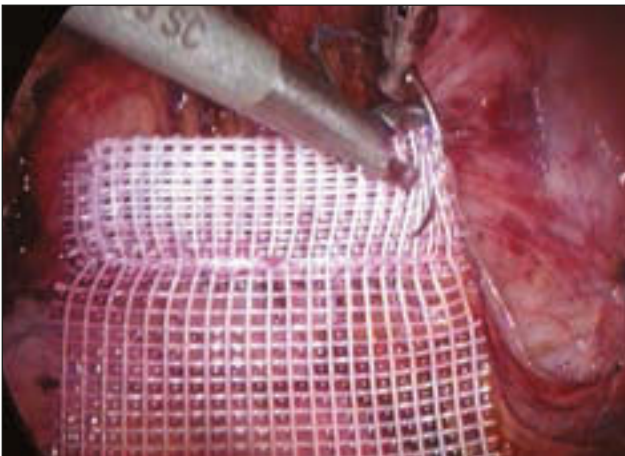


Fig. 11
Fixation of the mesh on the right.

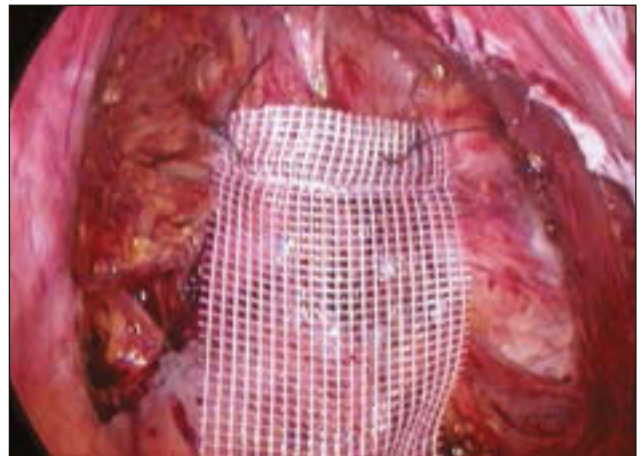

Fig. 12
Caudal and posterior fixation is complete.

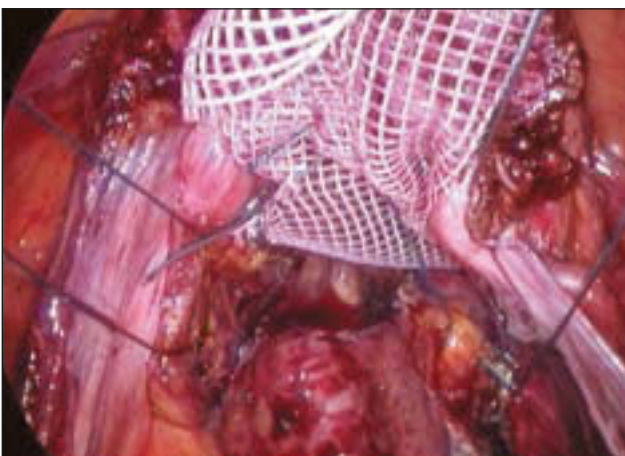


Fig. 13
Fixation of the posterior mesh to the cardinal ligaments and vagina.

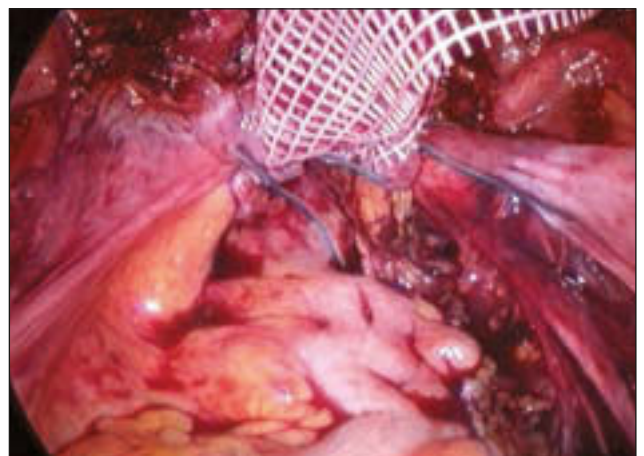


Fig. 14
Boundary of posterior fixation.

The mesh will then be stretched on the posterior wall of the vagina and attached to the cardinal ligaments with non-absorbable sutures (Ethibond® 0). We avoid sutures in the

8.6 Culdoplasty

The aim of culdoplasty is to re-establish the normal anatomical relationship between the rectum and vagina by repositioning the rectum more superiorly and restoring tension for the vagina towards the back. This can be performed with or without Douglasectomy and with one or two absorbable sutures (Ethibond® 0). The first step is to pick up the most cranial or posterior part of the uterosacral ligament with the

8.7 Anterior Fixation of the Mesh

The mesh is stretched in the anterior vesicovaginal cavity. If the uterus is spared, the two straps of the mesh are passed through the windows made in the posterior leaf of the broad ligament. These are fixed behind the isthmus with a flat knot in the deperitonized area at the start of the rectovaginal detachment.

posterior part of the vagina to minimize the risk of transfixing the vagina. Once the mesh has been fixed posteriorly, a *Mc Call* culdoplasty is performed (Figs. 9–14).

needle and then, after identifying the ureter, the cardinal ligament is fixed particularly carefully, followed by the mesh and the vagina. The knot is tied when this is complete. The same steps are repeated on the contralateral side. When this repair has been completed, the vagina resumes its anatomical position so upward traction is no longer necessary.

The mesh is fixed to the anterior vaginal wall with absorbable sutures which must not transfix the full thickness of the wall: Ethibond® 2/0 with 18 mm curved needle. The knots are tied with half-hitches made using the extracorporeal technique. 4 to 6 sutures will be needed (Figs. 15–17).

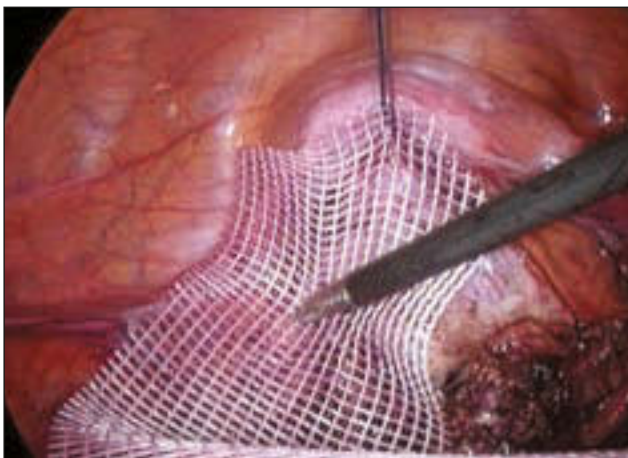


Fig. 15
Fixation of the anterior mesh.

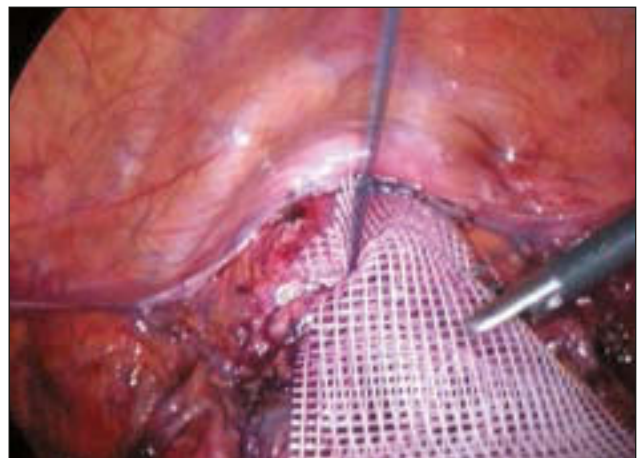

Fig. 16
High fixation of the anterior mesh.

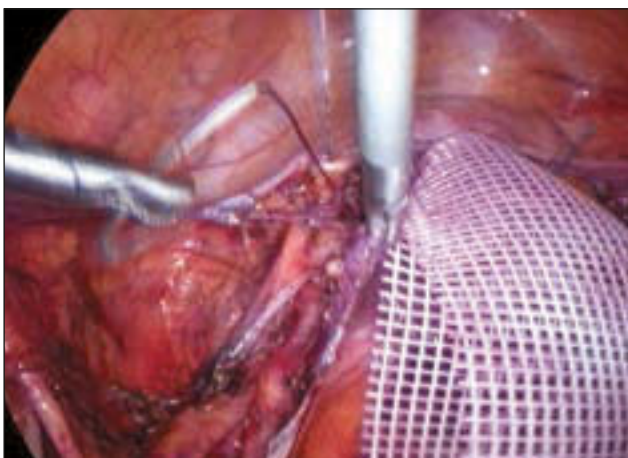


Fig. 17
Junction laterally of the anterior and posterior meshes.

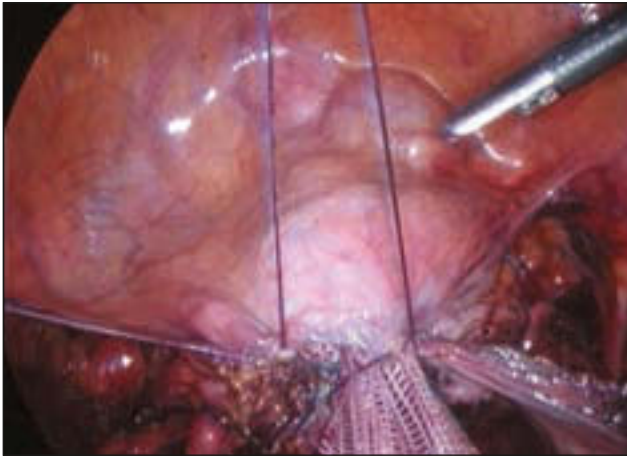


Fig. 18
Start of low peritonization.

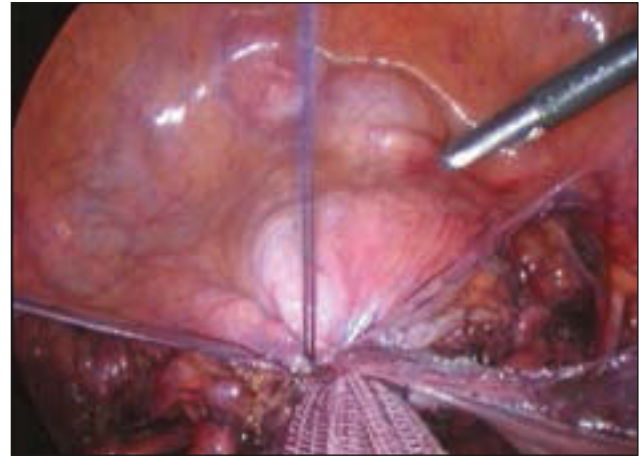


Fig. 19
End of low peritonization.

8.8 Low Peritonization

At vaginal level the purpose of the peritonization is to exclude the mesh from the abdominal cavity, placing the bladder over the prosthesis. The surgeon begins with a 0 Vicryl® suture with 30 mm curved needle in the prevesical peritoneum, then the bladder pillar, the lateral vaginal peritoneum and then the

inner margin of the lateral incision. Using the same suture, this procedure is repeated on the right side. A series of half-hitches tie the purse string to close the peritoneum and provide suspension of the bladder (**Figs. 18–19**).

8.9 Sacral Colpopexy

Sacral colpopexy involves fixing the anterior and posterior portions of the mesh to the promontory or anterior vertebral ligament with two sutures of Ethibond® and a 30 mm-curved needle or with staples or Tacker®.

The needle must remain discernable by transparency including only the fibrous layer of the aponeurosis to reduce to a minimum the risk of spondylodiscitis.

Once the sutures have been placed, slight traction is applied to confirm that they are anchored firmly.

The mesh needs to be fixed in position. When all the corrections have been made, the mesh will be stretched on the promontory and fixed at this level. The surgeon's experience is extremely important at this point (**Figs. 20–21**).

8.10 High Peritonization

The mesh must be completely retroperitoneal in position. A continuous suture joins the outer and inner layers of the lateral peritoneal incision. We use a 0 Monocryl suture with 30 mm curved needle. The smoothness of this suture makes

for ease of suturing. An adequate number of half-hitches is used for closure.

These steps conclude the anterior part. It may also be necessary to open the space of Retzius (**Figs. 22–23**).

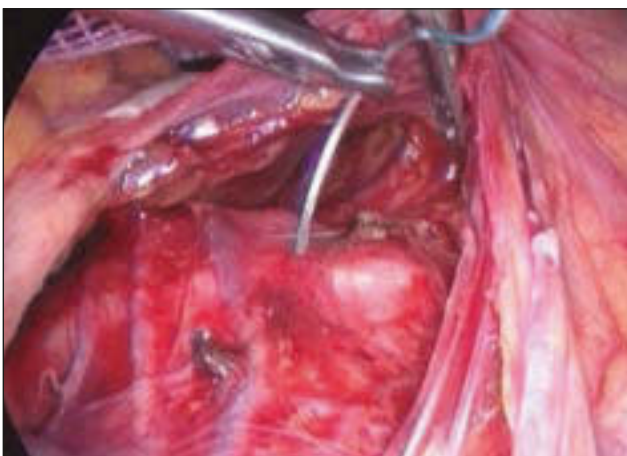

Fig. 20
Placement of the suture in the promontory.

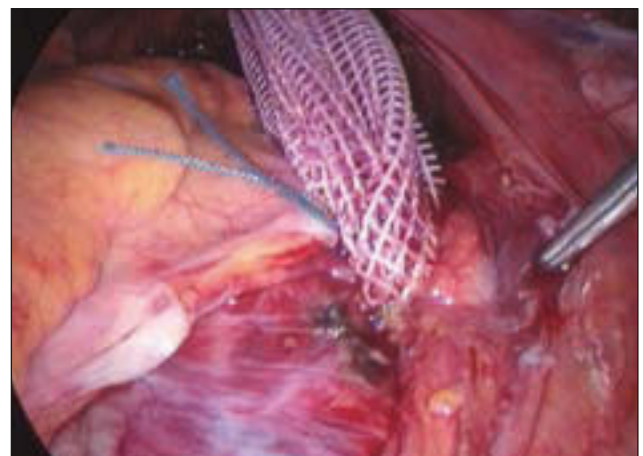


Fig. 21
Fixation of the mesh to the promontory.

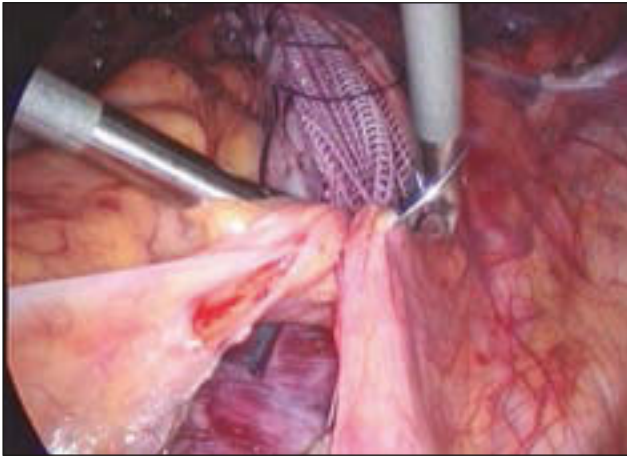


Fig. 22
High peritonization.

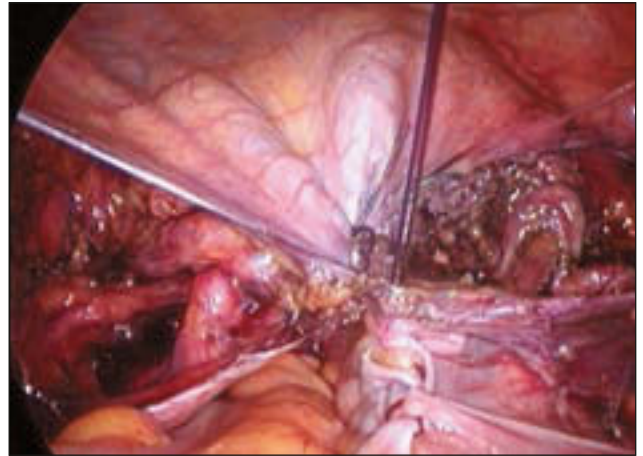


Fig. 23
Peritonization completed.

8.11 Opening the Space of Retzius

In the case of a transperitoneal approach, the procedure begins with identification of the landmarks:

- Pubis
- Cooper's ligament
- Superior margin of the bladder dome where the urachus originates

The peritoneum is incised above the bladder dome. The incision must be horizontal, from one umbilical artery to the other. The assistant applies downward traction to the peritoneum using forceps, while the surgeon draws the plane vertical with the right hand and incises it with monopolar scissors held in the left hand.

The urachus is coagulated and transected while the surgeon proceeds along a vertical plane towards the abdominal wall. The umbilico-prevesical aponeurosis must be passed

to penetrate the space of Retzius. This space is completely avascular and is dissected with simple divergent traction. The pneumoperitoneum aids in opening the space. Remaining in contact with the aponeurosis, a series of tissue layers must be passed until the fatty tissues anterior to Cooper's ligament indicate that the superior boundary of the space of Retzius is reached.

Cooper's ligament is localized bilaterally. At this point, the space of Retzius is easily opened down to the tendinous arc of the pelvic fascia. The dissection must reach the obturator foramina.

The vaginal walls are palpated with the aid of a finger placed in the vagina. The bladder margin is highlighted by the presence of a vein running along it, which must then be carefully separated from the vagina appearing pearly white (**Figs. 24–25**).

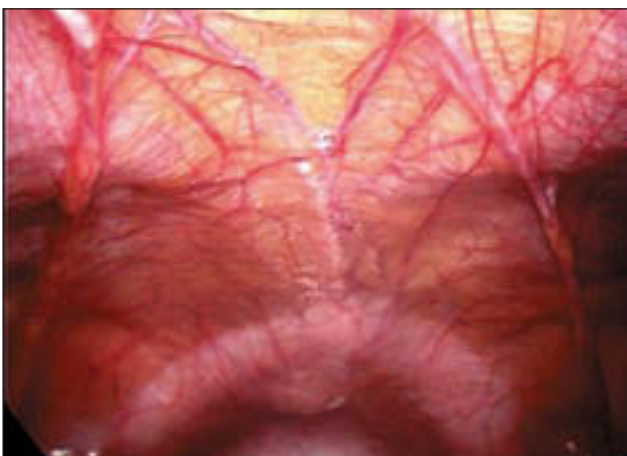


Fig. 24
Identification of the upper border of the bladder.

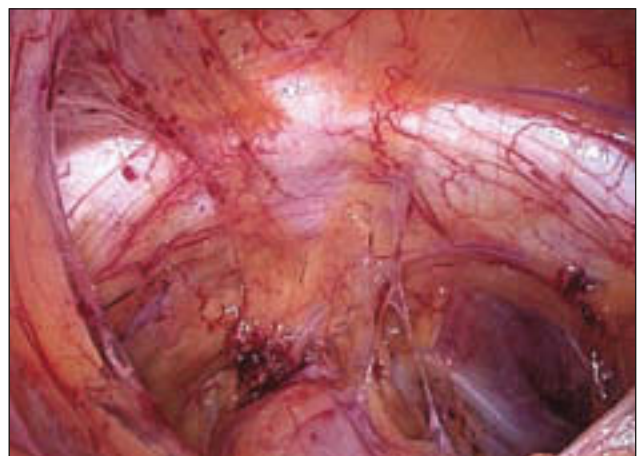


Fig. 25
Space of Retzius.

8.12 Paravaginal Repair

The positive pressure of the pneumoperitoneum allows visualization of the paravaginal defect which is nearly always present with high-grade prolapse. It appears as a herniation between the vaginal wall and the tendinous arc of the pelvic fascia. If there is indeed a paravaginal hernia, the defect

is closed using separate stitches or a running suture of Ethibond® 0 on a 18 mm-needle. This suture should run from the pubo-urethral ligaments anteriorly to the ischial spine posteriorly. Repair can be uni- or bilateral.

8.13 Burch Colposuspension

Following this repair, colposuspension is performed. The suture employed is Ethibond® 3.5 (0) with a 26 mm needle.

The suture passes through Cooper's ligament from above downwards and then through the vagina from within outwards, ensuring that the full thickness of the wall is not transfixed. Transfixion of the vagina must be wide enough to

preserve a certain degree of firmness. In the event of bleeding after the first passage, an X suture can be placed. In the case of promontory fixation, a single suture per side is placed and the tension is reduced. Where paravaginal repair has also been performed, this will necessitate hypercorrection of the cervical suspension.

8.14 Peritonization

This must always be performed in full. The aim is to prevent loops of intestine from becoming trapped in the space of Retzius. We use Vicryl® 0 with a 46 mm curved needle. Closure is achieved with three passes from right to left and we join this to the high and low peritonization with half-hitches.

9.0 Final Procedures

9.1 Uterine Morcellation

Morcellation is required in the case of subtotal hysterectomy. We use the Rotocut Morcellator (KARL STORZ, Tuttlingen, Germany). The uterus, which is normally small, is cut into strips 10 mm in diameter and removed and sent for histological examination.

9.2 Release of Fixation Sutures

The previously suspended intestine is released and hemostasis is ensured.

9.3 Peritoneal Toilet

This is best performed with Ringer lactate. Any blood clots are aspirated and careful hemostasis is performed. At the end of the procedure, the Ringer lactate must be completely clear.

9.4 Cystoscopy

The ureters are checked repeatedly during the procedure: after hysterectomy, after peritonization and after Burch suspension. These repeated controls make it possible that any iatrogenic injury caused by operating maneuvers can be immediately detected and thus allow for a more accurate repair. The color of the urine and air filling the collecting bag are important checks if bladder or ureter injury is suspected.

The role of cystoscopy is controversial. Some authors perform it systematically and others only in case of doubt, but in all cases, the indications should be broad. It will confirm the patency of the ureter orifices and thus ureter integrity.

10.0 Postoperative Care

10.1 Antibiotic Therapy

We do not use this systematically but treat infections only as they are identified and according to the antibiogram.

10.2 Prevention of Postoperative phlebitis

All of our patients receive antithrombotic prophylaxis, which starts on the evening of the operation and continues for 15 days postoperatively.

10.3 Foley Catheter

The catheter is left in for at least 24 hours depending on the patient's age and mobilization. When it is removed, urinalysis and urine culture are performed routinely and antibiotic therapy is started if necessary.

10.4 Duration of Hospital Stay

3 to 5 days

10.5 Postoperative Period

The postoperative period should be quiet, avoiding undue effort and excessive weights.

The diet is normal with plentiful hydration to reduce the constipation that is nearly always present in the first 3 postoperative weeks. Sexual activity can be resumed after 6 weeks.

11.0 Conclusions

Laparoscopy allows to combine the benefits of prolapse repair via laparotomy with the low morbidity of the vaginal approach. Operating times are long initially but in the hands

of expert surgeons, the duration is about 2 hours. Certainly, studies of long-term efficacy and reliability are still needed to fully assess the value of this technique.

Recommended Reading

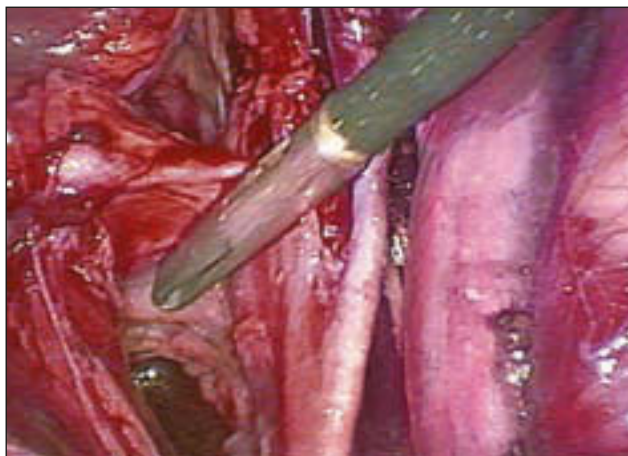
1. AMELINE A, HUGUIER J: La suspension postérieure du disque lombo-sacré : techniques de remplacement des ligaments utéro-sacrés par voie abdominale. *Gynecol Obstet*, 1957 ; 56 :94-98
2. RANDALL C: Surgical treatment of vaginal inversion. *Obstet Gynecol*, 1971;38: 327-332
3. NICHOLS D, MILLEY P: Significance of restauration of vaginal depth and axis. *Obstet Gynecol*, 1970; 36: 251-255
4. HOFF S, MANELFE A, PORTET R; GIROT C: Promontofixation ou suspension par bandelettes transversales ? Etude comparée de ces deux techniques dans le traitement des prolapsus génitaux. *Ann Chir*, 1984 ; 38 : 363-367.
5. BAKER KR, BERESFORD JM, CAMPBELL C: Colposacropexy with Prolene Mesh. *Gynecol Obstet*, 1990; 171: 51-54
6. ROBERT HG: Nouveau traité de techniques chirurgicales gynécologiques. Masson et Cie, 1969, 820 pages, p 128-130.
7. ADDISON WA, LIVENGOOD CH, SUTTON GP, PARKER RT: Abdominal sacral colpopexy with Mercilene mesh in the retroperitoneal position in the management of posthysterectomy vaginal vault prolapse and enterocele. *Am J Obstet Gynecol*, 1985; 15: 140-146
8. SUTTON JP, ADDISON WA, LIVENGOOD CH, HAMMOND CB: Life threatening hemorrhage complicating sacral colpopexy. *Am J Obstet Gynecol* 1981; 140 : 836-837
9. CAUBEL P, LEFRANC JP, FOULKES H, PUI A, BLONDON J: Traitement par voie vaginale des prolapsus génitaux récidivés. *J Chir*, 1989 ; 126 : 446-470
10. ADDISON WA, TIMMONS C, WALL LL, LIVENGOOD CH: Failed abdominal sacral colpopexy: observations and recommendations. *Gynecol Obstet*, 1989; 74: 480-842.
11. QUERLEU D, PARMENTIER D, DELODINANCE P: Premiers essais de la coelio-chirurgie dans le traitement du prolapsus génital et de l'incontinence urinaire d'effort. In : *Les troubles de la statiques pelviennes*. Blanc., boubli, Baudrant E., D'Ercale C. : 219 pages, Arnette. Paris Ed p 155-158.
12. WATTIEZ A, BOUGHIZANE S, ALEXANDRE F, CANIS M, MAGES G, POULY JL, BRUHAT MA: Laparoscopic procedures for stress incontinence and prolapse. *Current Opinion in Obstetrics and Gynecology*. A. DeCherney and Stuart Cambell Editors. 1995, Vol 7, n° 4, 317-21.
13. WATTIEZ A, AIMI G, FINKELTIN F, CANIS M, POULY JL, POMEL C, GERARD CH, MAGE G, BRUHAT MA: Cure chirurgicale des prolapsus velico-uterins par voie coelioscopie exclusive Gunaikaia, 1997, 2, 2, 50-5
14. WATTIEZ A, CUCINELLA G, GIAMBELLI F, MENCAGLIA L: Laparoscopic burch procedure for retropubic colposuspension. *It J Gynecol Obstet* 1997, 9, 3, 114-7.
15. WATTIEZ A, CANIS M, MAGE G, POULY JL, BRUHAT MA: Promontofixation dans le traitement des prolapsus : intérêt et technique de la voie coelioscopique. *Le Journal de Coelochirurgie*. 1999, 31, 7-11.

Chapter XVII

**Laparoscopic Surgical Staging
of Endometrial Carcinoma**

Fabrizio Barbieri and Luca Minelli

Department of Gynecology and Obstetrics
“Sacro Cuore” General Hospital, Negrar, Italy



1.0 Introduction

Endometrial carcinoma is the most common tumor of the female reproductive system and the fourth most common after breast, colon and lung cancer if all other malignant

disease is considered. It affects mainly women between the ages of 50 and 70 years. In about 80% of cases it is diagnosed at stage I with a 5-year survival of 80-90% (**Tab. 1**).

FIGO stage	Ia	Ib	Ic	IIa	IIb	IIIa	IIIb	IIIc	IVa	IVb
Overall 5-year survival rate	88.9%	90.0%	80.7%	79.9%	72.3%	63.4%	38.8%	51.1%	19.9%	17.2%

Tab. 1
Endometrial carcinoma; overall 5-year survival (FIGO classification).

The first staging system drawn up by the *International Federation of Gynecologists and Obstetricians (FIGO)* in 1971 was clinical staging based on clinical examination under general anesthetic, ultrasound and a limited number of investigations such as endocervical curettage, hysteroscopy, cystoscopy, proctoscopy and radiography of the chest and skeleton. This staging is still applied for patients regarded as inoperable.

Subsequently, many studies demonstrated significant substaging of patients undergoing clinical staging so in 1988,

the Oncological Committee of the FIGO introduced a system of anatomical-surgical staging (**Tab. 2**):

- Total hysterectomy + bilateral salpingo-oophorectomy + pelvic and lumbo-aortic lymph node dissection (LND)
- Peritoneal washing

Although more accurate histological information about the grade and extent of the disease is obtained through surgical staging, total uniformity has not yet been reached, especially as regards the need for always performing LND and its

TNM category	FIGO staging system	Description
TX		The primary tumor cannot be assessed
T0		There is no evidence of primary tumor
Tis	0	Carcinoma in situ
T1	I	Tumor confined to the corpus uteri
T1a	Ia	Tumor limited to the endometrium
T1b	Ib	The tumor invades up to less than half of myometrium
T1c	Ic	The tumor invades to more than one half of myometrium
T2	II	The tumor invades the cervix but does not extend beyond the uterus
T2a	IIa	Endocervical glandular involvement only
T2b	IIb	Cervical stroma invasion
T3 and/or N1	III	Local and/or regional dissemination as specified in T3a, b, N1 and FIGO IIIA, B, C below
T3a	IIIa	The tumor involves the serosa and/or adnexae (direct extension or metastasis) and/or cancer cells in ascites or peritoneal washings
T3b	IIIb	Vaginal involvement (direct extension or metastasis)
N1	IIIc	Metastasis to the pelvic and/or para-aortic lymph nodes
T4	IVa	Tumour invades bladder mucosa and/or bowel mucosa ¹
M1	IVb	Distant metastases (excluding metastases to the vagina, pelvic serosa or adnexae and including metastases to intra-abdominal lymph nodes other than para-aortic and inguinal)

Note 1. The presence of bullous edema is not sufficient to classify a tumor as T4.

Tab. 2
Carcinoma of the uterine corpus classified according to FIGO / TNM staging systems.

extent. For instance, the extent of lymphadenectomy has not yet been defined: biopsy of the pelvic and lumbo-aortic lymph nodes, systematic pelvic and lumbo-aortic lymphadenectomy or removal only of enlarged lymph nodes. If, on the one hand, pelvic and lumbo-aortic lymphadenectomy is essential for correct staging, on the other hand it does not appear to influence overall survival (at present there is only one meaningful scientific study published by *Kilgore et al* in 1995 that supports the therapeutic value of LND).

As stated above, the operative staging procedure usually includes total extrafascial hysterectomy, bilateral adnexectomy, intraperitoneal exploration / cytological washing and lymphadenectomy. In the majority of cases, pelvic lymphadenectomy is sufficient; however, the lumbo-aortic lymph nodes would be removed in the following situations: positive pelvic lymph nodes, ovarian metastases and clear cell or serous papillary histological type. For many authors, intraoperative pathological assessment can provide guidance on whether to go ahead with lymphadenectomy particularly based on infiltration of the myometrium.

During the past 10 years numerous studies have assessed the value of the laparoscopic approach as compared to traditional laparotomy in the staging and treatment of endo-

metrial carcinoma. Laparoscopy has been shown to be capable of implementing all steps of the surgical staging system in accordance with the FIGO guidelines.

Numerous studies have shown that with laparoscopic surgery the incidence of postoperative complications such as pyrexia, paralytic ileus and wound infection is reduced; the duration of hospitalization is also reduced with an early return to normal activity.

The first study of laparoscopic treatment of endometrial carcinoma was published in 1990. In the following period, various authors demonstrated the feasibility of laparoscopic surgical staging taking into account potential limiting factors related to patient (anatomy, body mass index, presence of adhesions) and surgeon (experience and training) factors. Subsequently, a single randomized study with a short follow-up period reported that laparotomy and laparoscopy were equivalent in terms of overall survival and disease-free survival.

In recent years, therefore, entirely laparoscopic or vaginally assisted laparoscopic surgical staging has become more and more widespread for the first stages of endometrial carcinoma. Obviously, it is extremely important for the surgeon to have a profound knowledge of both laparoscopy and gynecologic oncology.

2.0 Preoperative Management

When endometrial carcinoma is suspected clinically, usually because of abnormal uterine bleeding, it must be confirmed by endometrial histology. Where endometrial biopsy cannot be performed in an outpatient setting because of stenosis of the cervical canal or poor patient compliance, it must be carried out under general anesthesia.

Although they are insufficient for diagnosis, gynecological examination and transvaginal ultrasound must be performed to rule out concomitant adnexal pathology.

Cytological examination of the endocervix and ectocervix can exclude the presence of cervical pathology.

Given the confirmed diagnosis of endometrial carcinoma, the next step is to determine the extent of the disease so

that the correct surgical management and any adjunctive therapy can be planned. In 80% of cases, there is no clinical evidence of extrauterine disease so the only tests needed are chest radiograph and routine preoperative laboratory tests. However, transvaginal ultrasound and/or MRI scan are useful for assessing myometrial infiltration and can indicate cases at risk of metastatic spread. If the liver function tests are altered or advanced-stage disease is suspected, imaging procedures such as MRI, computed tomography (CT) and abdominal and pelvic ultrasound can be useful in tracing metastases. In patients with characteristic symptoms of disease in certain organs, cystoscopy, contrast enema, cerebral CT or bone scan may be necessary.

3.0 Surgical Technique

In the majority of cases, total laparoscopic extrafascial hysterectomy with bilateral adnexectomy and pelvic lymphadenectomy is sufficient. In a few cases, radical laparoscopic hysterectomy may be indicated (**Figs. 1–12** and **Tab. 1**).

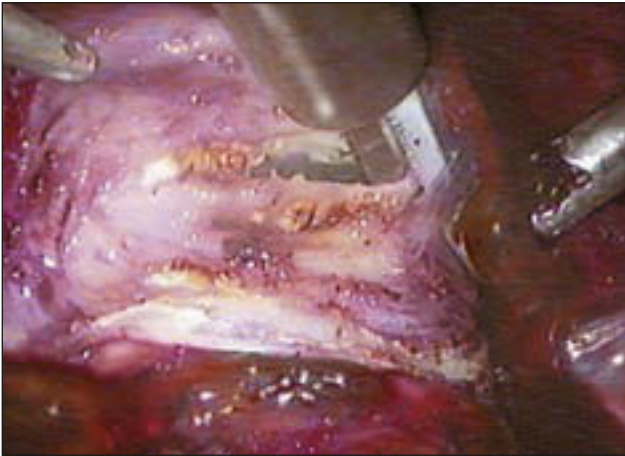

Fig. 1
Laparoscopic incision of the vaginal wall.

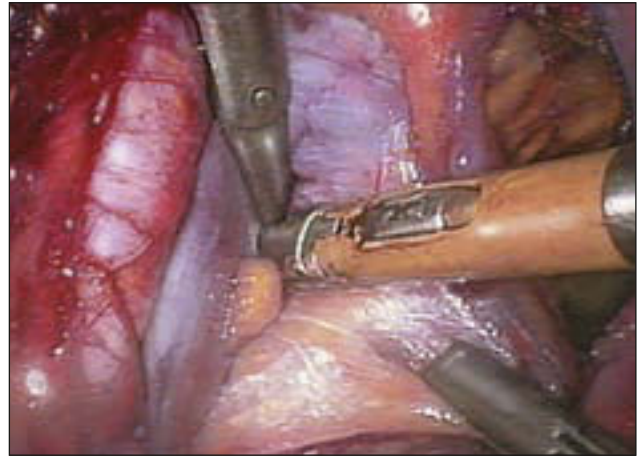


Fig. 2
External iliac artery and vein. External iliac lymph nodes.

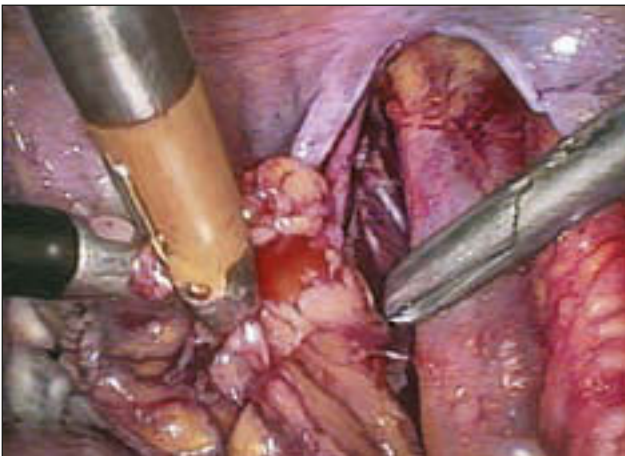


Fig. 3
Internal iliac lymph nodes located medial to the external iliac vessels.

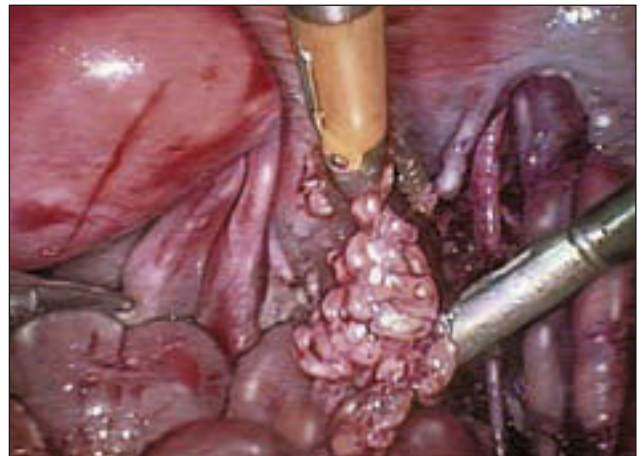


Fig. 4
Sampling of an internal iliac lymph node.

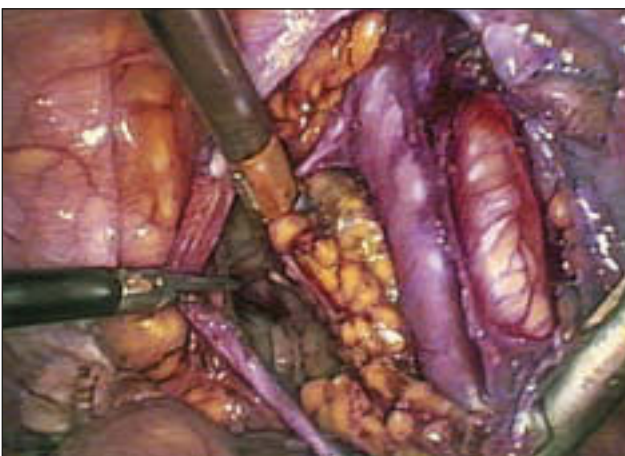


Fig. 5
The external iliac artery and vein, and the internal iliac lymph nodes. The internal iliac artery is visible.

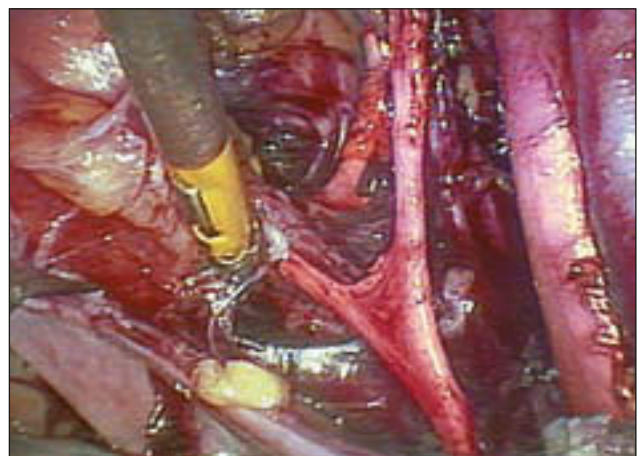


Fig. 6
After sampling the lymph nodes the external iliac artery and vein, the uterine artery and internal iliac artery can be localized.

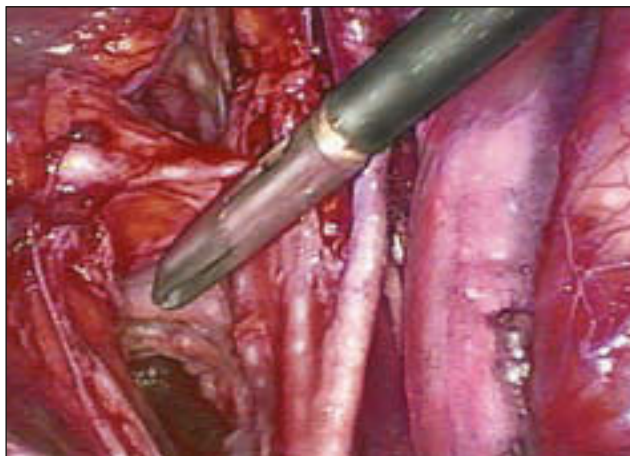

Fig. 7
The uterine vessels are distinct anatomical landmarks that highlight the boundary between the paravesical space anteriorly and the pararectal space posteriorly.

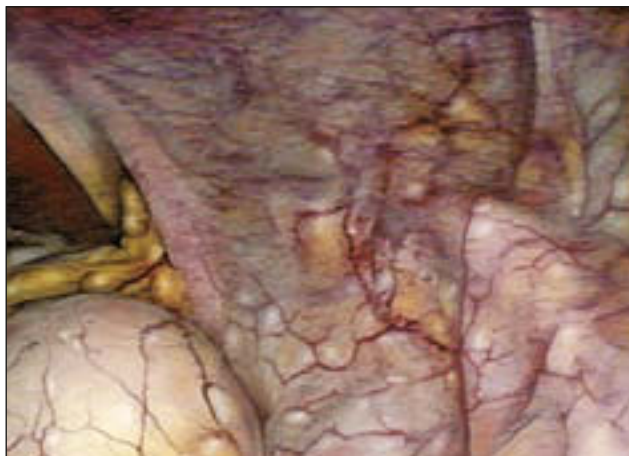

Fig. 8
The ureter can be followed laterally as far as the pelvis where it crosses the uterine artery.

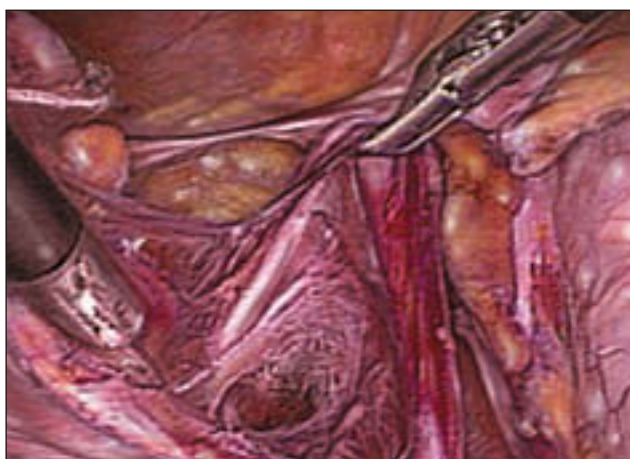

Fig. 9
The ureter can be skeletonized safely.

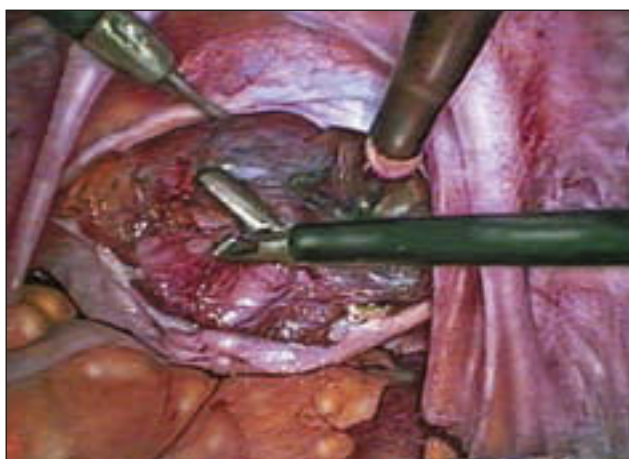


Fig. 10
Opening the rectovaginal space between the cul-de-sac and the uterosacral ligaments.

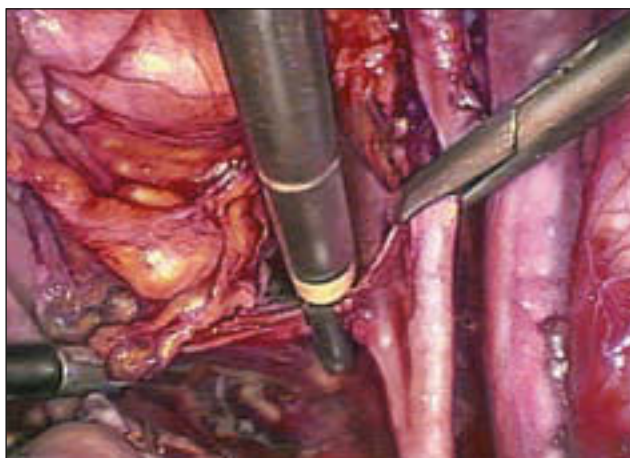


Fig. 11
Coagulation of the origin of the uterine artery with bipolar forceps.

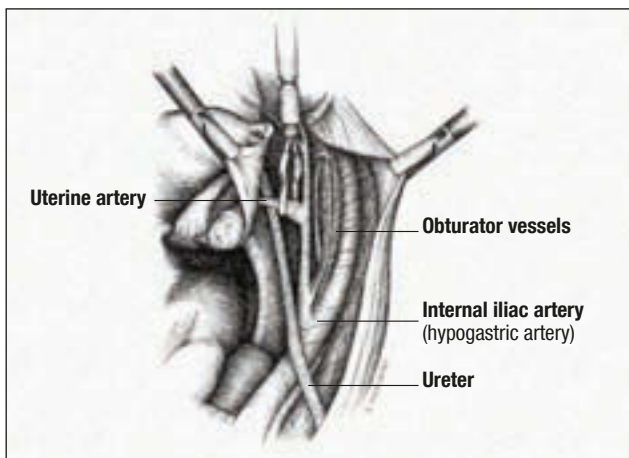


Diagram 1
Exposure and occlusion of the uterine artery by coagulation at its origin, the anterior division of the internal iliac artery.

4.0 Conclusions

The problems emphasized most frequently with the laparoscopic approach are:

Peritoneal Dissemination

Thanks to the studies by *Vergote* and *Possover*, it has been demonstrated fully that there is no significant statistical difference between laparotomy and laparoscopy with regard to the incidence of positive peritoneal cytology. It should be stressed that in both series the uterine manipulator was not used and the tubes were coagulated at the start to avoid intraoperative dissemination. Finally, it has been shown that positive peritoneal cytology on its own is not an unfavorable prognostic factor.

Recurrence in the Vaginal Vault

Numerous studies have shown that there is no increase in vaginal vault recurrence in patients with laparoscopically staged endometrial cancer.

Laparoscopic Port-site Metastases

Recurrence at the port-site following laparoscopic surgery has been described for all types of gynecologic cancers, even in patients with early disease. The incidence has not yet been accurately assessed because surgeons often do not achieve long-term patient follow-up and this type of recurrence is often considered to be of little prognostic value in the presence of concomitant distant metastases. In the literature, the incidence is 2.3% with gynecologic carcinomas and as regards endometrial cancer, a recent review reports 4 cases of port-site metastasis in patients with laparoscopically staged endometrial carcinoma. Numerous hypotheses about promoting factors have been proposed: the pneumoperitoneum, carbonic anhydride, the "pathway effect", the local immune system, the surgical technique and also trocar contamination. It is essential to emphasize that there is nothing at present to explain whether the cause of these metastases is linked to the particular aggressiveness of the tumor or to laparoscopic surgery per se.

Some authors report a reduced incidence of port-site metastases with peritoneal closure and/or surgical repair of the incision site.

Recommended Reading

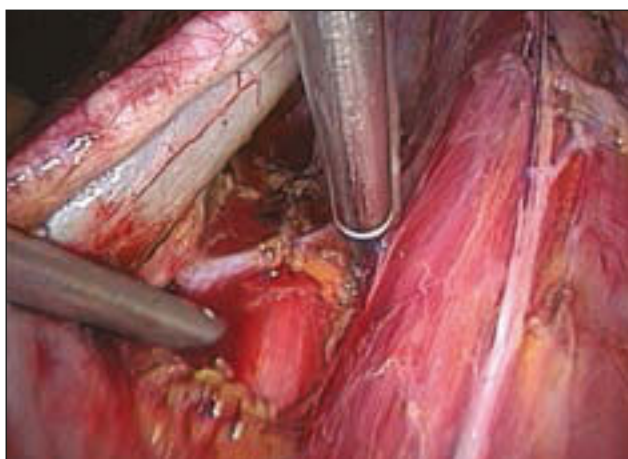
1. BEREK J, HACKER NF: Practical gynecologic oncology. Third edition 2000. Ed Lippincott Williams and Wilkins. Philadelphia
2. BENEDET JL, BENDER H, JONES H, NGAN HY, PECORELLI S: FIGO staging classifications and clinical practise guidelines in the management of gynecologic cancer. *Int J Gynecol Obstet* 2000, 70:209–62
3. RAMIREZ PT, FRUMOVITZ M, WOLF JK, LEVENBACK C: Laparoscopic port-site metastases in patients with gynecological malignancies. *Int J gynecological malignancies* 2004, 14:1070–7
4. VAISBUCH E, DGANI R, BEN-ARIE A, HAGAY Z: The role of laparoscopy in ovarian tumors of low malignant potential and early-stage ovarian cancer. *Obstet Gynecol Surv.* 2005 May;60(5):326–30
5. AGOSTINI A, ROBIN F, JAIS JP, AGGERBECK M, VILDE F, BLANC B, LECURU F: Peritoneal closure reduces port site metastases. *Surg Endosc* 2002, 16:289-91
6. KILGORE LC, PARTRIDGE EE, ALVAREZ RD, et al: Adenocarcinoma of the endometrium: Survival comparisons of patients with and without pelvic node sampling. *Gynecol Oncol* 1995, 56:29-33

Chapter XVIII

Laparoscopic Pelvic and Lumbo-aortic Lymphadenectomy

Fabrizio Barbieri and Luca Minelli

Department of Gynecology and Obstetrics
"Sacro Cuore" General Hospital, Negrar, Italy



1.0 Introduction

In patients with gynecologic tumors, the prognosis is established in conformity with the guidelines of the FIGO staging system. Surgical staging is superior to clinical staging because it allows histological confirmation of the extent of tumor invasion. Methods such as magnetic resonance imaging (MRI), computed tomography (CT), lymphography or needle aspiration have low specificity and sensitivity.

Lymphadenectomy, in particular, allows accurate surgical staging and can be of therapeutic value at the same time. However, conventional pelvic and lumbo-aortic lymphadenectomy requires a large laparotomy incision so there is high peri- and postoperative morbidity. Thus, the development of the laparoscopic techniques can have major

advantages with regard to scarring, postoperative pain and length of hospital stay.

Laparoscopic lymphadenectomy in oncologic gynecology was first described by *Dargent* in 1989 and *Querleu* in 1991 subsequently reported on the first series of 30 patients undergoing transperitoneal pelvic lymphadenectomy. The first laparoscopic lumbo-aortic lymphadenectomy was reported by *Nezhat* 1992. Today, there are various publications – regardless of the fact that most of them are based on a small patient population – addressing the technical feasibility, the number of lymph nodes removed and the safety of laparoscopic lymphadenectomy in carcinoma of the endometrium, cervix and ovary.

2.0 Preoperative Management

- | | |
|---|---|
| <ul style="list-style-type: none"> ● Routine preoperative laboratory tests ● Chest X-ray ● ECG ● Imaging procedures: abdominal and pelvic ultrasound, computed tomography of the abdomen and pelvis, nuclear magnetic resonance imaging of the abdomen and pelvis | <ul style="list-style-type: none"> ● Thromboembolism prophylaxis (low molecular weight heparin + elastic compression) ● Antibiotic prophylaxis ● Cross-match and blood available for transfusion |
|---|---|

3.0 Patient Positioning

- | | |
|--|--|
| <ul style="list-style-type: none"> ● Classical supine gynecologic position ● Arms alongside the trunk ● Oro-tracheal intubation | <ul style="list-style-type: none"> ● Foley catheter in the bladder ● 30° Trendelenburg |
|--|--|

4.0 Instrumentation

- | | |
|--|---|
| <ul style="list-style-type: none"> ● 0° laparoscope ● Bipolar forceps ● Cold or unipolar scissors ● Grasping forceps (Dorsey, Schneider) | <ul style="list-style-type: none"> ● Endobags ● Suction cannulas ● Uterine manipulator with atraumatic tip ● Endovascular clips |
|--|---|

5.0 Surgical Technique

5.1 Pelvic Lymphadenectomy

Systematic pelvic lymphadenectomy involves the following lymph node groups:

External iliac:	
lateral group:	lateral to and above the external iliac artery
intermediate group:	between the external iliac artery and vein (the antero-lateral limit is represented by the deep circumflex iliac vein.)
medial group:	below the internal iliac vein close to the lateral pelvic wall
interiliac:	at the iliac bifurcation
obturator:	between the internal obturator muscle and the superior margin of the obturator nerve
Common iliac:	
lateral group:	in the ileolumbar fossa lateral to the common iliac artery
intermediate group:	above the common iliac artery and vein
medial group:	medial to the common iliac vessels, promontory and presacral region

The first surgeon is on the patient's left. After creation of the pneumoperitoneum with the aid of the Veress needle, an 11-mm trocar for the laparoscope is placed at umbilical level,

followed by two 6-mm ports in the left and right iliac fossae and a 11-mm suprapubic port.

The peritoneum over the psoas muscle is opened from the round ligament, which is pulled in antero-caudal direction by the second surgeon until the genitofemoral nerve is localized at the base of the infundibulo-pelvic ligament at the lateral margin of the external iliac artery. The external iliac artery and vein are exposed from the bifurcation of the common iliac artery to the level of the deep circumflex iliac vein. The obliterated umbilical artery is then identified and the paravesical space is dissected down to the pelvic floor. Preserving the genitofemoral nerve, the external iliac vessels are exposed and descending along the lateral pelvic wall, dividing the lymphatic tissue from the psoas muscle laterally with careful coagulation, the obturator fossa is reached by blunt dissection and the nerve is identified. The external iliac lymph nodes are removed en bloc together with the obturator nodes, drawing the lymphatic tissue from in front backwards and gradually releasing the obturator nerve until the bifurcation of the common iliac artery is reached. Systematic pelvic lymphadenectomy involves the interiliac and common iliac lymph nodes, which are accessed by opening the peritoneum in caudo-lateral direction; this allows the ileocecal junction to be mobilized on one side and the sigmoid on the other, so that the ureter can be identified and displaced medially. To remove the block of lymphatic tissue, the lymphatic ducts can be ligated with endoclips or bipolar and the lymph nodes are then removed from the peritoneal cavity using an extraction bag (**Figs. 1–8**).

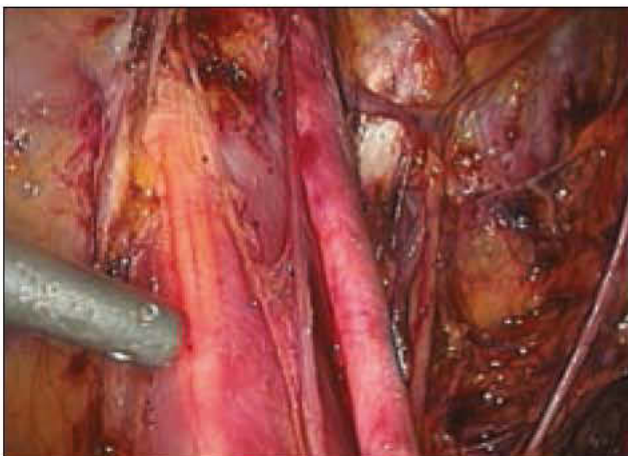


Fig. 1
Identification of the genitofemoral nerve over the psoas muscle.

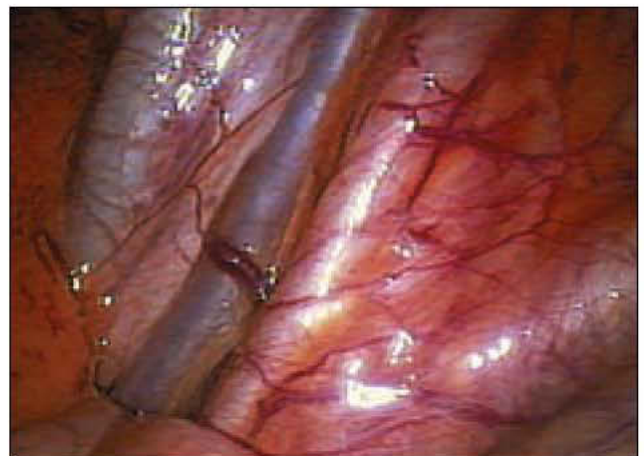


Fig. 2
Bifurcation of the common iliac artery.

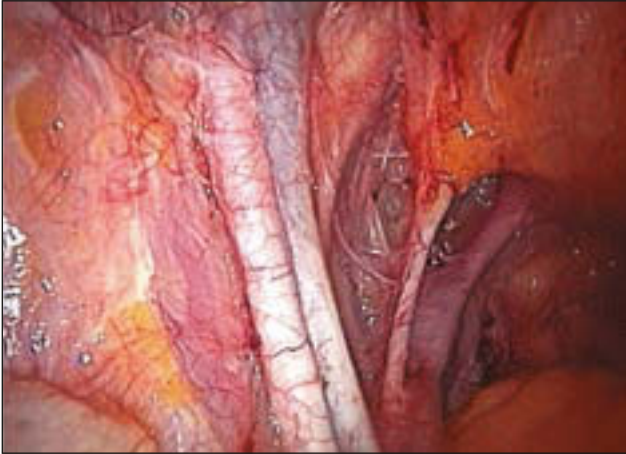


Fig. 3
The external iliac vessels are excised to the level of the deep circumflex iliac vein.

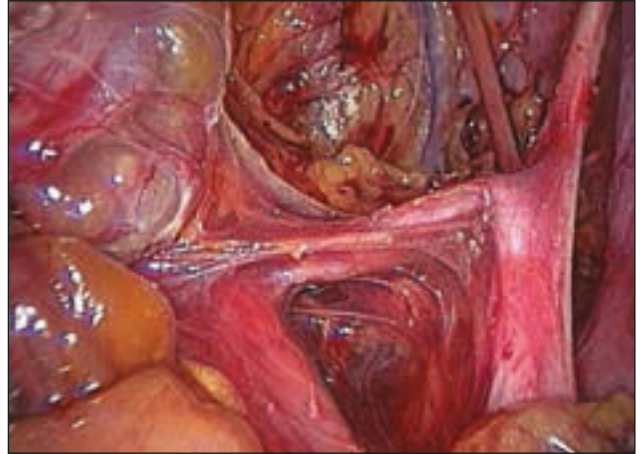


Fig. 4
Identification of the origin of the uterine artery.

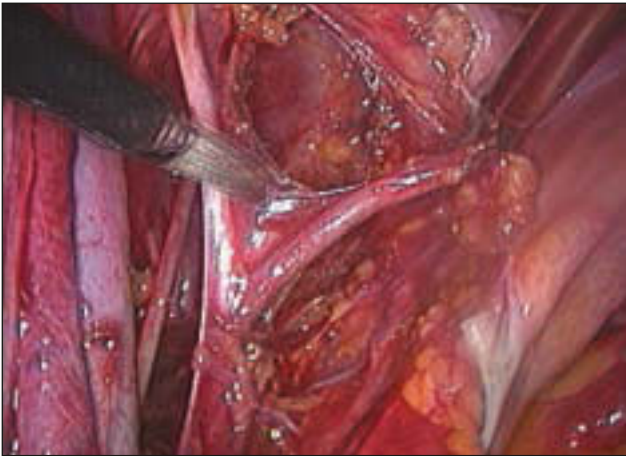

Fig. 5
Dissection of the prevesical space.

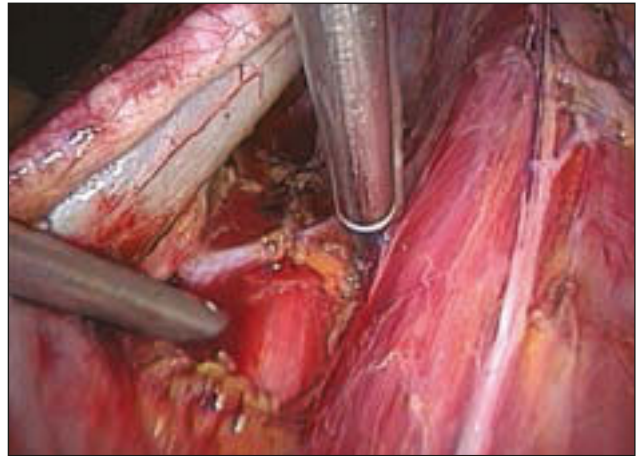


Fig. 6
Exposure of the external iliac vessels from the lateral pelvic wall.

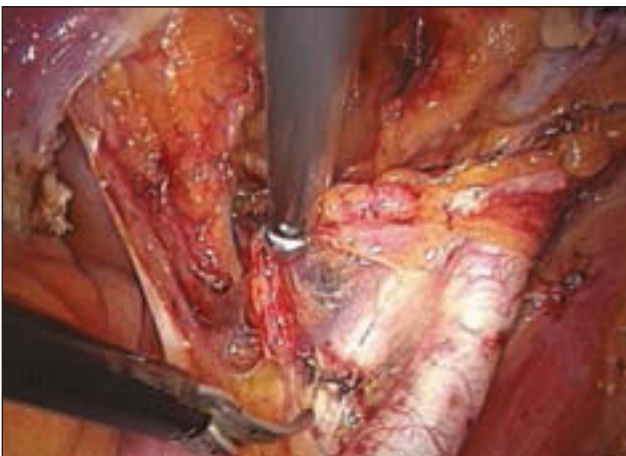


Fig. 7
En bloc removal of the external iliac lymph nodes.

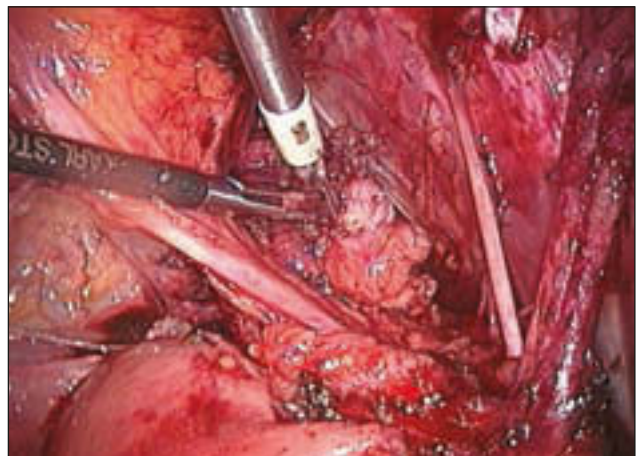


Fig. 8
Removal of the obturator lymph nodes.

Surgical landmarks:

1. round ligament (antero-superficial)
2. infundibulo-pelvic ligament (medial superficial)
3. genitofemoral nerve (lateral and medial)
4. external iliac vessels (lateral and medial)
5. obliterated or blind umbilical artery (caudal and medial)
6. Cooper's ligament (deep caudal and lateral)
7. uterine artery (medial)
8. ureter (medial)
9. obturator muscle (dorsomedial)
10. internal iliac vessels (superficial dorsal)
11. lumbosacral plexus (deep dorsal)

5.2 Lumbo-aortic Lymphadenectomy

Left lumbar lymph nodes:	above, lateral to and below the aorta
Intermediate lymph nodes:	between the aorta and the inferior vena cava
Right lumbar lymph nodes:	above, lateral to and below the inferior vena cava

The first surgeon is at the patient's right to remove the left para-aortic lymph nodes, and at the left to remove the right-sided and pelvic nodes.

Following creation of the CO₂ pneumoperitoneum, an 11 mm umbilical port is placed, with three 6-mm ports in the right and left iliac and suprapubic regions, and another 11-mm port in the left hypochondrium, which is used to apply traction to the bowel and to extract the lymph nodes with an endobag.

Lymphadenectomy begins in the right para-aortic region by making an incision in the peritoneum covering the uppermost part of the ipsilateral iliac artery.

The video camera is orientated so that the aorta and inferior vena cava appear horizontal with the inferior vena cava above

A retroperitoneal approach has also been described. This would have certain advantages for exposure of the operative field because the bowel is within the peritoneum and because of the reduced incidence of adhesions (a major advantage especially in patients who must have radiotherapy) but at the expense of a greater incidence of lymphocele, which can be reduced by opening the peritoneum of the paracolic gutters at the end of the operation.

the aorta. The ureter is localized and pushed laterally. The precaval and paracaval lymph nodes are dissected starting to the right of the common iliac artery and continuing as far as the right ovarian vein using bipolar forceps. If the lymph nodes are positive or there is right ovarian cancer, the lymphadenectomy is extended as far as the renal vessels.

For dissection to the left of the aorta, the camera is rotated through 180° and the first surgeon stands at the patient's right side. After identifying the ipsilateral ureter and inferior mesenteric artery and elevating the mesosigmoid – being careful to preserve the superior hypogastric plexus – the left para-aortic, presacral and common iliac lymph nodes are removed (inframesenteric lymphadenectomy). In the case of left ovarian carcinoma, the lymphadenectomy is extended as far as the left renal vein, removing the entire infundibulo-pelvic ligament as far as its origin but sparing the inferior mesenteric artery.

In patients at high risk of lymph node recurrence or with ovarian tumors, the lymphadenectomy is extended to the region between the aorta and the inferior vena cava as far as the renal vessels (infrarenal lymphadenectomy).

6.0 Sentinel Lymph Node

The sentinel lymph node is the first node in the lymphatic system draining lymph from the primary tumor. If this lymph node is not invaded by metastasis, all other lymph nodes should be tumor-negative. The sentinel lymph node can be identified by peritumor injection of blue dye, which usually stains the first draining lymph node, or by a peritumor injection of a radioactive tracer (e.g., technetium 99), which diffuses and accumulates in the sentinel lymph node where it can be visualized with a gammacamera.

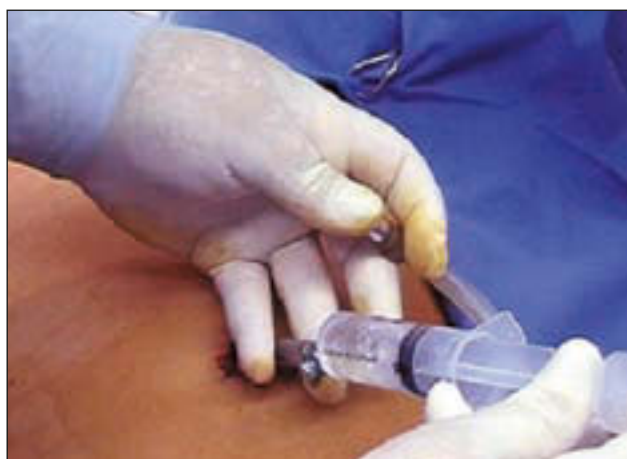Sentinel lymph node sampling can be indicated in the case of malignant melanoma, breast cancer and carcinoma of the vulva. The procedure can be performed laparoscopically for surgical staging of other gynaecologic tumors such as endometrial and cervical cancer. In early-stage cervical carcinoma, in particular, biopsy sampling of the sentinel lymph node allows frozen section analysis for determination of the lymph node status. The metastatic status of the SN can help to triage patients between radiochemotherapy or radical hysterectomy, thus reducing morbidity and post-operative hospitalization.

Chapter XIX

**Complications in
Laparoscopic Surgery**

**Leopoldo Carlos Videla Rivero
and Beatrice Videla Rivero**

Callao Surgical Institute
Buenos Aires, Argentina



1.0 Introduction

In recent years, laparoscopic surgery has become common clinical practice in many countries because of its benefits as compared to traditional laparotomy. It is minimally invasive surgery, which allows the patient to recover and return to ordinary life more rapidly. Like any surgical technique, it is associated with potential complications and technical problems some of which being attributable solely to the laparoscopic technique.

It is known that the incidence of major intraoperative complications is less than 1%, with mortality ranging between 4 and 8 per 100,000 cases. There are various publications on personal experiences with the laparoscopic technique, systematically analyzing data collected from series of case histories presented with incidence rates and types of complications.

In this chapter, the following topics are addressed:

- meaning and definition of a complication in general terms
- the critical moments of surgery associated with an increased potential risk of complications, such as the importance of the first access port in laparoscopic surgery
- some of the main publications on the complications of the laparoscopic approach
- a suggested classification of the complications
- pictures of laparoscopic complications
- means of preventing laparoscopic complications
- intraoperative resolution of complications
- a proposal to set up a database for multicenter collection of data on complications, cross-linked with the Internet
- conclusions
- recommended reading

2.0 Meaning and Definition of a Complication in General Terms

A complication is a concurrence of various causes and conditions in the course of a surgical procedure, which do not normally form part of it and which usually make it more serious. A complication by definition is an unexpected and undesirable fact. Moreover, it is an event that is possible in any surgical operation, that can occur at any moment and that can happen to any surgeon and to any patient.

A complication is an error that allows conclusions to be drawn as to which procedure was initially planned, whether it has been a technical or strategic error.

Laparoscopic surgery is supported by three fundamental concepts:

- The surgical team, which must have adequate experience and proficiency in laparoscopic surgery
- The laparoscopic instruments must be suitable for the planned operation
- The surgical indication must be precise

Consequently, it can be stated that complications can be correlated with:

- the experience and coordination of the surgical team that is operating. In this case, the surgeon's experience and the learning curve for this technique on the part of the entire team must be assessed.
- the patient's disease, in which the surgical indication plays a fundamental role, and the limits of the disease being treated. Another determining factor is the anatomical complexity of the intra- or retroperitoneal surgical approach.

As regards instrumentation, it is extremely important to assess the quality, safety and complexity of all technical components, also with regard to the surgical indication.

Where a balance can be maintained in controlling these three variables, there will be a consequent reduction in the risk of surgical complications.

When a complication occurs, the unwanted consequences and implications become evident on different levels and in various ways:

In the patient, the complication can elicit physical damage with possible sequelae.

At medico-legal level, it can trigger a claim for damages with consequences for society, the physician and the patient. Consequently, the laparoscopic surgical technique suffers in terms of prestige and is subjected to often unfounded criticisms. It should be mentioned, that sometimes the attitude of some physicians co-involved in or outside the complication event is not always constructive and may have a further negative effect.

Historically, laparoscopic surgery has developed greatly since the 1970s up to the present day. This development has been accompanied by complications, from the risks of the laparoscopic technique at the start, through the different indications for laparoscopic surgery which developed during this period, up to the present, when, given the worldwide trend toward the increased use of the laparoscopic method, the principal causes of complications can be attributed directly to the surgeon (**Tab. 1**).

Historical Evolution of the Risk of Complications		
Period	Laparoscopic surgery	complications
'70 – '85	Initial period	due to the technique
'85 – '90	Development	due to the indications
'90 – presence	Globalization	due to the surgeon

Tab. 1

3.0 Complications – Patterns of Risk Factors

Although it has already been stated that complications can occur at any moment and under any circumstances during surgery, statistical analysis and empirical evidence demonstrate that there are situations and conditions which constitute what can be described as “patterns of risk factors”. An inherent characteristic of laparoscopic surgery is the high level of complexity related to surgical maneuvers and instrumentation. Profound knowledge of the function of each instrument is of paramount importance for proper manipulation of instruments and precise surgical maneuvering. This concept is particularly important in the development of laparoscopic skills. Indeed, a thorough knowledge of the instruments and their function considerably increases the safety of surgery.

Laparoscopic surgery requires the use of standardized techniques and maneuvers under visual control through a laparoscope that shows the anatomy, whereas introduction of the first trocar is not under direct visual control but is performed blindly, thus constituting a risk factor (Tab. 2).

Furthermore, the surgical instruments are separated from the surgeon’s hands by a considerable distance, which means that the force and precision of the movements depend on the position of the forceps. Another variable is the fact, that the distal end of the instrument can have more than one function at the same time (grasping – traction – cutting – dissection – uni/bipolar coagulation).

Therefore, it can be stated that the laparoscopic technique is inherently associated with characteristic complications.

Patterns of Risk Factors

- The use of non-specific instruments
- First access route
- Surgical technique and alternative options
- Electrosurgical applications
- Level of proficiency of the surgical team

Tab. 2

Undoubtedly, the successful outcome of laparoscopic surgery is closely linked to the strict compliance with a set of basic rules and criteria, that allow the procedure to be performed without complications. “*Successful results of laparoscopic surgery are essentially accomplished by good technique and application of ergonomic principles*” states A. Wattiez. The detailed rules that must be strictly observed can be summarized as follows: choice of the first umbilical port with a correct intra-umbilical incision; positioning of the trocars must take into account the various working angles required during surgery; choice of accessory trocars of the same size as the instruments to be used, as this improves the precision of surgical actions (this holds true, e.g., if a 5 mm instrument is inserted through a 11-mm trocar while using a reducer); placing the accessory trocars perpendicular to the abdominal wall to facilitate movements as much as possible; choice of laparoscope (angle of view 0° or 30°) according to the pathology and choice of a high-resolution video camera system for delivery of high-quality images; knowledge of the basic principles of electrosurgery; correct choice of forceps

for adequate grasping and traction of each anatomical structure; simplification of surgical actions by assuming the appropriate position at the operating table, coordination and adequate setup of the surgical team in the operating room including the height of the table and patient and the placement of the carts, machines and monitors. The length of the forceps and instruments must be selected prudently to make sure that the grasping or traction forces applied to the tissues during surgery will be essentially the same throughout the procedure. The surgical strategy is closely associated with the level of proficiency and experience of the surgeon and all members of the team. This can be improved by prior discussion of the case with experts and with the team. Lavage should not be used during surgery as the presence of liquid in the peritoneum can impede visual quality for various reasons. It is currently considered appropriate to use lavage of the operative field only at the end of the operation before the laparoscope and trocars are removed. Unnecessary movements during the operation should be avoided by all members of the team. The proper choice of suture (stitch – knot – suture – needle) requires specific preparation. The relevant anatomic site and the instruments in use should always be kept in the center of the screen. Consequently, the eyes should never be taken off the screen throughout the surgical procedure. Attempt to make the most of the specific technical features of the instruments and the skills of all team members to rationalize the surgical strategy.

The principles of ergonomics, however, impose rules on all team members involved in the procedure: observing all the listed rules and the principles of ergonomics will allow the operation to be carried out optimally.

A general recommendation is always to employ delicate movements in laparoscopic surgery, especially during steps that demand great care.

In gynecological surgery, particular attention must be paid while ligating vascular pedicles; during anatomical dissection by using nerve-sparing techniques and making sure that arterial and venous vascular pedicles are properly skeletonized. Precise suturing technique is based on the correct choice of suture and needle, the target site of the suture and the most suitable knot, depending on the case. Knowledge of electrosurgical principles is essential in gynecological laparoscopic surgery. In gynecology, each group of surgical procedures has its own special characteristics. In ablative procedures such as hysterectomy, particular attention must be paid to ligation of the vascular pedicles and skeletonization of the uterine artery and its anatomical-topographic relations to the ureter.

In oncologic laparoscopic surgery, it is essential to meet oncologic radicality criteria and not to modify the established surgical standards because of the different access route.

In adnexal disease, it is very important not to underestimate the risk of malignancy. In laparoscopic myomectomy, particular attention must be paid to careful hemostasis, to suture of the uterine bed and extraction of the operative specimen.

As in ablative laparoscopic surgery, it is essential to restore the anatomical conditions as much as possible and to place sutures appropriately. In surgery for infertility, the use of microsurgical techniques is highly important.

The first laparoscopic access merits a separate paragraph. This is the step in laparoscopic surgery that requires particular care. Creation of the first port can be accomplished by establishing the pneumoperitoneum with the Veress needle and using the open laparoscopy technique, with direct insertion of the abdominal trocar or by use of a specific optical trocar that allows constant visual control. However, all of these techniques involve the inherent risk of complications. Those, associated with the first laparoscopic access are the risk of perforating or injuring vessels or organs during entry and the possibility of a viscus remaining incarcerated in the incision during removal which entails a postoperative wound hernia.

Although the first laparoscopic access route offers various alternatives, the surgeon's choice is often influenced by

a few subjective aspects. There is no single answer to the question which of the given options in terms of technique could be "best" for the laparoscopic approach: the best surgical technique is the one the surgeon is familiar with and the best surgical maneuver is the one that he controls best. The surgeon should have a good command of the technique to be applied. Besides, there are further aspects that should be considered: the way how the technique is performed, the surgeon's experience with the technique, conviction of its surgical usefulness, its choice and safety in performing it, and finally the personal competences and aspects of technical feasibility as related to the infrastructure available.

The technique that is most universally employed and accepted in gynecologic laparoscopic surgery, especially in Europe, is the one with the Veress needle, which is followed by the classical safety maneuvers, intra-umbilical incision and introduction of a trocar with a conical tip. Introduction of the accessory trocars for the instruments is carried out under visual control (**Figs. 1–9**).

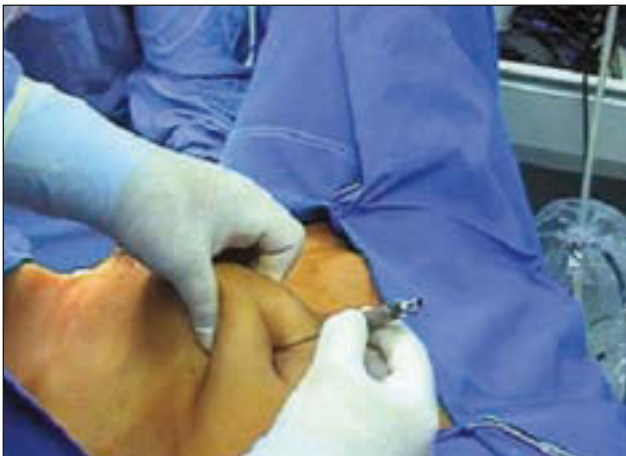

Fig. 1
Introduction of the Veress needle.

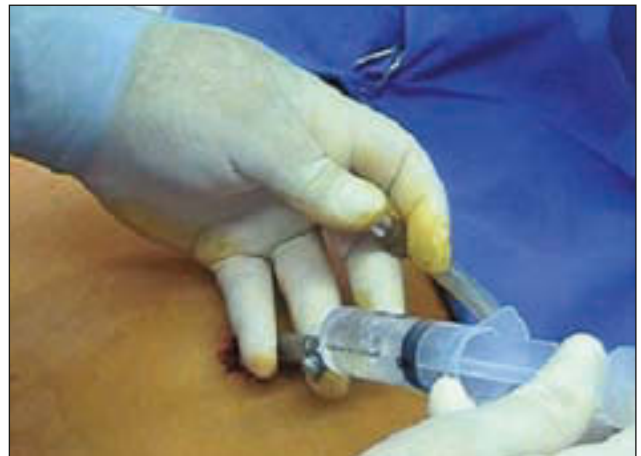

Fig. 2
Safety test performed with syringe and normal saline.

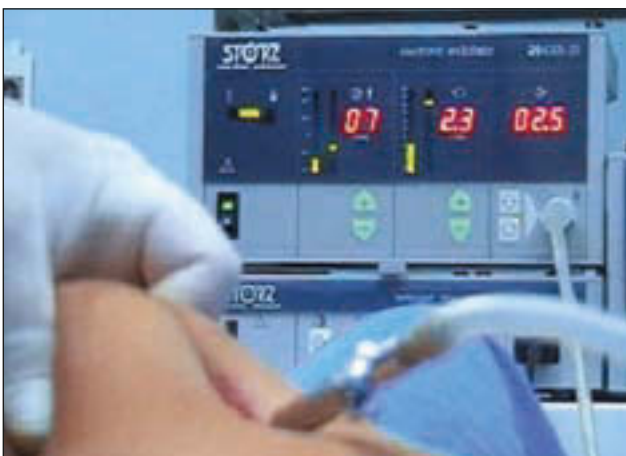

Fig. 3
Assessment of intra-abdominal pressure by applying cephalic traction to the anterior abdominal wall.

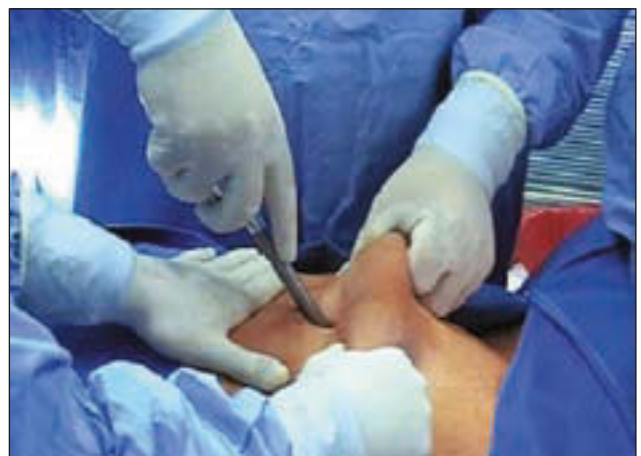

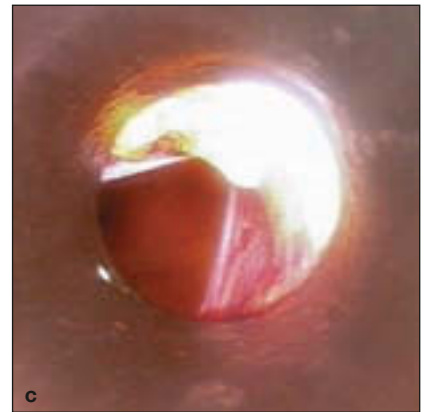
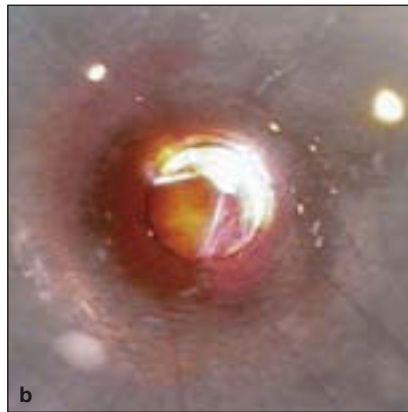
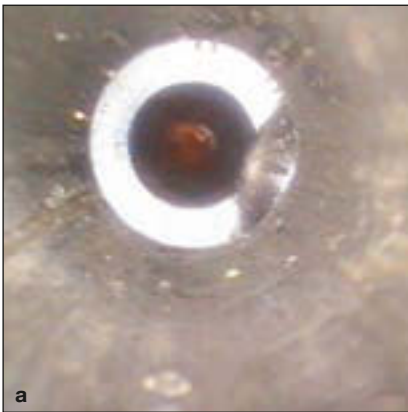
Fig. 4
Introduction of the first intra-umbilical trocar.

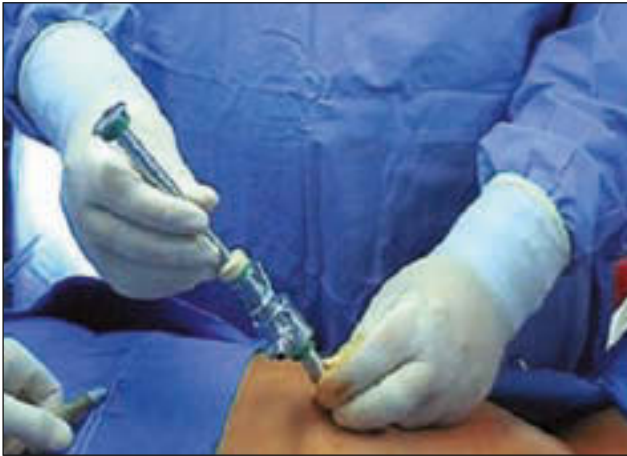

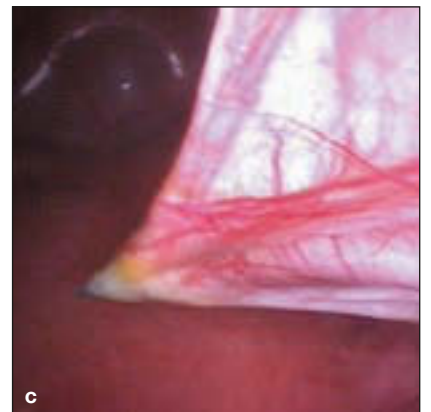
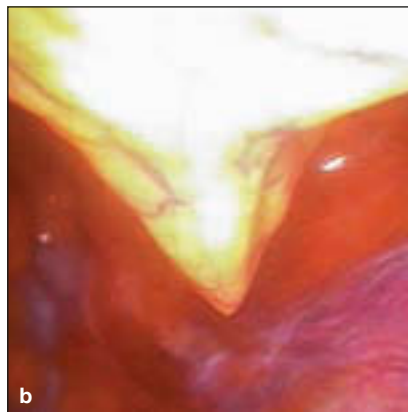
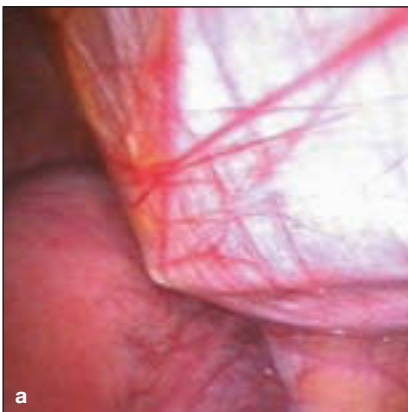
Fig. 5
Removal of the conical trocar with the cannula left in place.

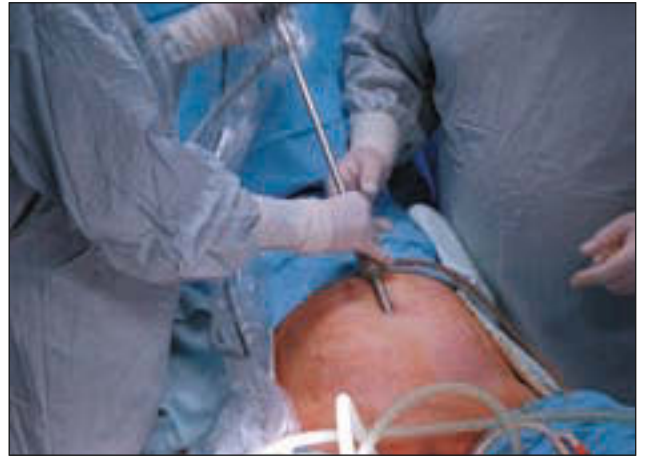

Fig. 6
Insertion of the laparoscope with coupled video camera.



Figs. 7a-c
Sequence showing the passage of the laparoscope through the first trocar under visual control.



Figs. 8a-c
Sequence demonstrating the insertion of the second trocar. This is always performed under visual control.

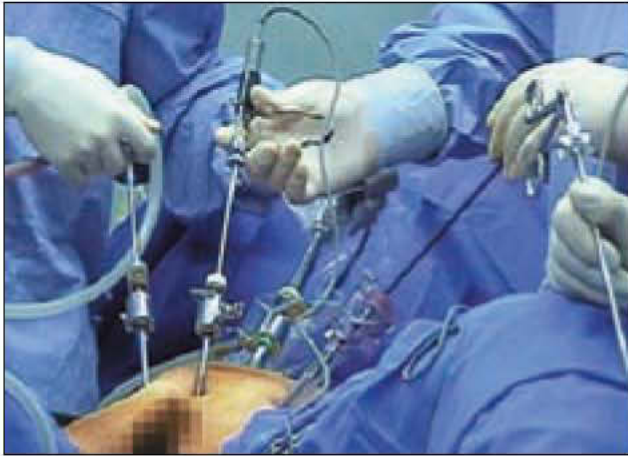

Fig. 9
Usual working position in gynecology.

The “open laparoscopy” according to *Hasson* has had a large influence and become widespread in the majority of schools of surgery, especially in general surgery, urology, pediatrics and with some gynecologic surgeons. It is likely that the criteria will be standardized in future.

4.0 Principal Publications

“Those who do not have complications either do not operate or they conceal them and therefore do not publish them”. In reality, there are numerous publications on the complications of laparoscopic surgery, although retrospective studies by single surgeons may tend to underestimate the true incidence. Despite the fact that retrospective analyses have a risk of underestimation, these studies are important for defining the complications and their incidence. In general,

records of complications derive from scientific associations, institutions or personal experiences.

A few international publications are listed here in the form of tables (**Tab. 3–4**), including institutional and personal publications.

In 1995, the **Sociedad Argentina de Cirugía Laparoscópica** (SACIL) published an analysis of 18,435 surgical laparos-

Country	Author	Year	n	Major %	Total %	Mortality x 100,000
Germany	<i>Lehemann-Willenbrock et al</i>	1992	292,462	0.19	0.19	5.1
USA	<i>Phillips et al</i>	1977	298,029	0.46	0.41	5.2
USA	<i>Phillips et al</i>	1984	117,705	0.28–0.31	0.29	4.2
USA	<i>Henning et al</i>	1985	36,207	0.18	0.87	66
England	<i>Chamberlain et al</i>	1978	50,247	s/d	3.5	8
USA	<i>Phillips et al</i>	1984	125,560	0.14	0.14	0
USA	<i>Peterson et al</i>	1990	36,928	1.5	0.15	5.4
Argentina	<i>Videla R. et al</i>	1995	18,435	0.29	2.06	0
France	<i>Querleu D. et al</i>	1996		0.22–0.34	0.89	0
Chile	<i>Miranda C. et al</i>	2002	2,140	0.46	0.79	0

Tab. 3

Complications during the first access							
Country	Author	Year	n	Veress	1 st trocar	Vascular	Visceral
Italy	<i>G. Melotti et al</i>	1996				0.64	0.16 – 0.27
Italy	<i>M. Candiani et al</i>	1997	1,000	0.27	0.27		
USA	<i>R. Corfman et al</i>	1993				0.45 – 0.9	0.1 – 0.18
USA	<i>J. Flowers et al</i>	1994				0.6	0.3
USA	<i>C. Y Liu et al</i>	1996	518	0	0	0	1.1
Brazil	<i>C. Parente Barbosa</i>	1998	2,324	0.13	1.03 (0.04 open)	0.35 (c/t 5 mm) 0.13 (c/t 10 mm)	0.67
Chile	<i>C. Miranda</i>	2002	2,140	0	2	2	0

Tab. 4

copies performed by surgeons at different levels of training/stages of the learning curve, with an incidence of 381 complications (2.06%) (Tab. 5), 54 of which were reported as potentially lethal (0.29%).

Total complications	381 (2.06%)
<ul style="list-style-type: none"> ● Extrapertoneal insufflation 118 ● Hematoma of the abdominal wall 80 ● Vascular injury 72 ● Infection 34 ● Postoperative bleeding 21 ● Connected with anesthesia 16 ● Urologic injury 14 ● Intestinal injury 10 ● Transitory nerve paralysis 5 ● Pericholecystitis 3 ● Hematoma of the vaginal vault 3 ● Hyperthermia (48 h) 2 ● Chemical peritonitis (dextran) 2 ● Hypothermia 1 	

Tab. 5
Argentine Laparoscopic Surgery Society.

The Ibero-American Gynecologic Endoscopy Society SIAEGI in 2002 on the occasion of its IX Congress in Quito, Ecuador collected the Latin American records of laparoscopic complications in Argentina and Chile (Tab. 6).

Argentina	5,183 cases 42 complications 0.81% (LC Videla Rivero)
Chile	2,140 cases 16 complications 0.74% (C Miranda)

Tab. 6
Ibero-American Gynecologic Endoscopy Society SIAEGI.

As institutional and personal publications, we present a few case series with the percentage of complications. In some cases the complications that occurred are listed (Tab. 7–11).

Surgical laparoscopies Complications	2,401 10 (0.42%)
<ul style="list-style-type: none"> ● 1 injury of the aorta ● 1 injury of the ureter ● 1 injury of the bladder ● 1 postoperative hemorrhage + brachial plexus ● 1 immunologic peritonitis (dextran) ● 1 nerve compression with paresis of the lower limb ● 1 pericholecystitis ● 1 injury of the ileum (fistula) ● 1 hematoma of the vault 	

Tab. 7
LC Videla Rivero Private Gynecology Service.

Surgical laparoscopies Complications	2,711 28 (1.03%)
---	---------------------

Tab. 8
Gynecology Service, University of Buenos Aires Hospital Clinic, Argentina.

Surgical laparoscopies Complications	1,261 10 (0.79%)
3 postoperative hemorrhages	
<ul style="list-style-type: none"> ● 2 at the vaginal vault, hysterectomy ● 1 from the myomectomy bed 	
1 intestinal injury	
<ul style="list-style-type: none"> ● first trocar 	
3 injuries of the bladder	
<ul style="list-style-type: none"> ● 1 during Burch suspension ● 1 during hysterectomy ● 1 during myomectomy 	
2 vascular injuries	
<ul style="list-style-type: none"> ● 1 first trocar, mesenteric artery ● 1 epigastric vein, second port 	
1 fistula uretero-vaginale	
<ul style="list-style-type: none"> ● during radical hysterectomy 	

Tab. 9
Gynecology Service of Private Institute specializing in Endoscopic Surgery, Buenos Aires, Argentina.

Surgical laparoscopies Complications	2,140 16 (0.74%)
<ul style="list-style-type: none"> ● 2 injuries of the aorta (first trocar) ● 3 injuries of the ureter or bladder ● 3 injuries of the intestine ● 1 related to anesthesia ● 1 intraoperative hemorrhage ● 1 epigastric artery hemorrhage ● 5 postoperative 	

Tab. 10
University of Chile Hospital Clinic, Santiago de Chile.

Surgical laparoscopies Total complications Major complications Death or serious consequences	2,500 38 (1.5%) 0.25% 0
---	----------------------------------

Tab. 11
Gynecology Service, Lagomaggiore Hospital, Mendoza, Argentina.

P. Ayrosa Ribeiro in 2004 in a personal communication reported a retroperitoneal complication which occurred while applying traction to the peritoneum at the moment when it was opened.

Conversion from laparoscopy to laparotomy should not be regarded as a complication of laparoscopic surgery but

rather an honest and medically responsible action. In fact, conversion is related not so much to complications as to the complexity of the surgical procedure. Different authors have shown that conversion correlates directly with the limits of the laparoscopic approach and with the surgeon's experience (**Tab. 12**).

Country	Author	Year	Procedure			
			Dx	Minor	Major	Advanced
France	<i>Querleu, D. et al.</i>	1993	1.7	0.4	4.8	8.9

Tab. 12
Laparoscopic conversion rates to laparotomy.

5.0 Classification of the Complications

There are various classifications of laparoscopic complications; however, that published by *Querleu* and *Chapron* in 1993 is distinguished by its practicality and logical structure. Under the title "*Complications of gynecologic laparoscopic surgery*", these authors proceed to a further classification into potentially lethal and non-lethal; they are also divided into intraoperative and postoperative, and minor and major complications (**Tab. 13**).

- Potentially lethal complications
- Non-lethal complications
- Intraoperative complications
 - Minor
 - Major
- Postoperative complications

Tab. 13:
Classification of complications in gynecologic laparoscopic surgery according to *Querleu* and *Chapron*.

6.0 Images of Laparoscopic Complications

"The best way to treat the complications is to recognize them and the best way to recognize them is to show them to the medical community".

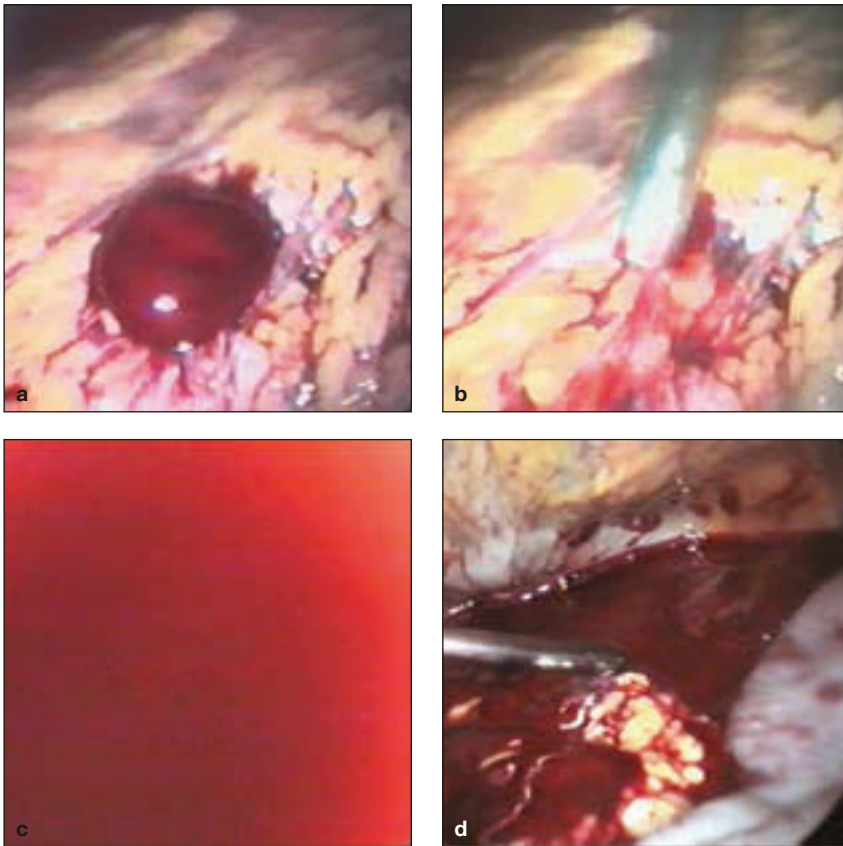
Following this concept and because a characteristic of laparoscopic surgery is that it allows documentation in images, we can present photos taken from the records of surgical

procedures. These images have a "historical" value as they were recorded and preserved so that they could be shown to the medical community. The complications occurred at different times in the past and were dealt with at that time. This is why we have called this collection a "museum of complications".

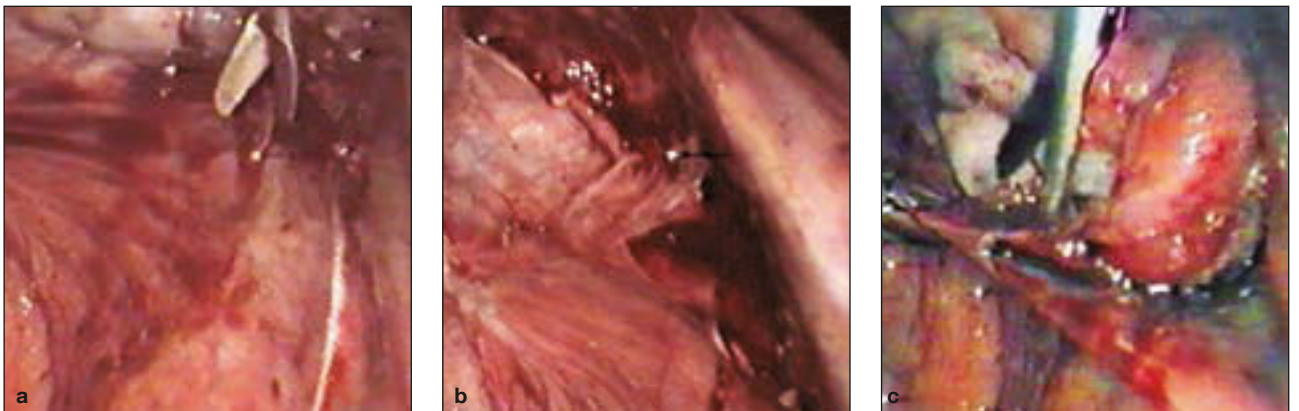
Museum of Complications

■ Potentially lethal complications

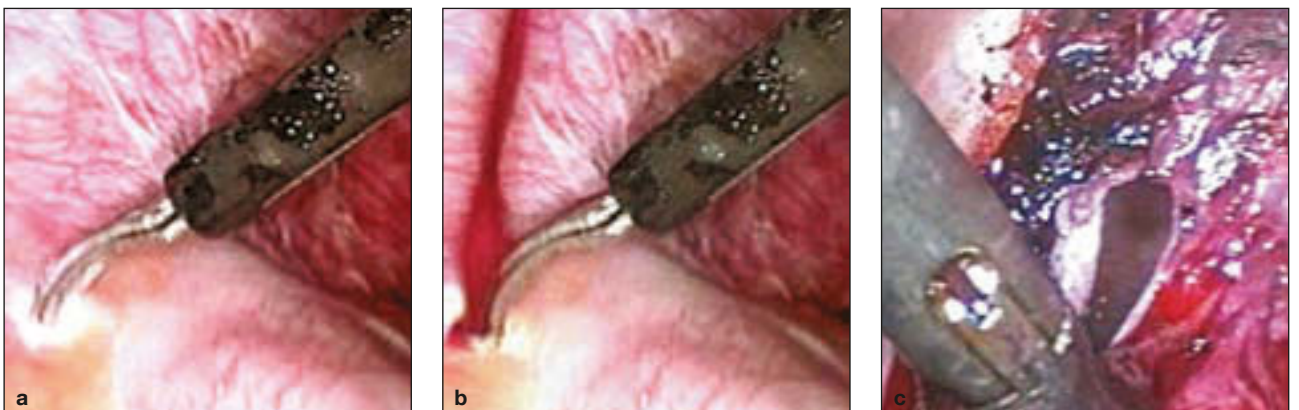- 1 injury of the aorta in 1995, with immediate conversion and vascular suture without serious consequences (**Fig. 10**).
- 1 injury of the ureter in 1987, not discovered, which occurred during removal of an endometrioma from the right ovary on the posterior surface of the broad ligament with scissors. The injury became apparent in the postoperative period with urinary peritonitis, repaired by laparotomy with uretero-cystic anastomosis. Good postoperative recovery (**Fig. 11**).
- injury of the external iliac artery in 2004 during the retroperitoneal approach; the injury was caused by unipolar scissors. Laparoscopic vascular suture was performed but conversion was required because of arterial thrombosis. Subsequent recovery without consequences (**Fig. 12**).



Figs. 10 a–d Sequence demonstrating iatrogenic injury of the aorta during introduction of the first trocar (immediate conversion) in 1995.



Figs. 11a–c Sequence demonstrating accidental injury of the right ureter during endometrioma removal, 1987.



Figs. 12 a–c Sequence demonstrating iatrogenic injury to the external iliac artery during surgery for deep endometriosis, 2004.

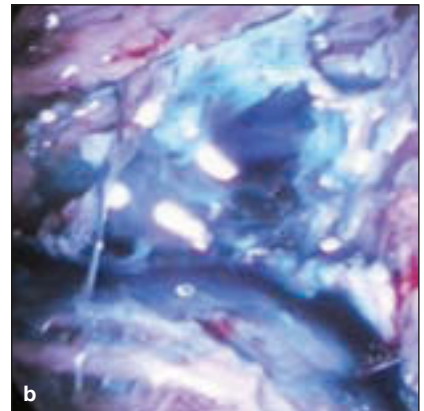
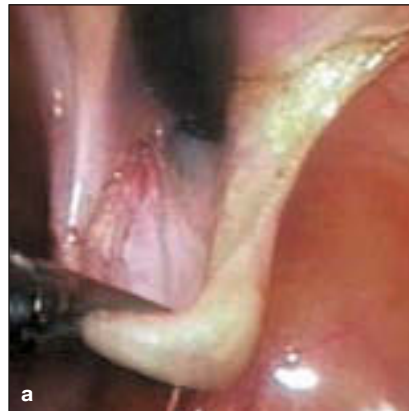■ Intraoperative complications

- 3 injuries of the bladder in 1996, 1997 and 2004, the first during total hysterectomy, the second during a Burch suspension. Dealt with in all cases by laparoscopic suture and indwelling catheter in the postoperative period. Good recovery (**Fig. 13**).
- 1 uterine hemorrhage in 1993 during laparoscopic hysterectomy. Due to nonavailability of bipolar forceps, the injury was repaired laparoscopically by hemostatic suture of the left uterine artery. Good recovery (**Fig. 14**).
- 1 hypotension of anesthetic origin

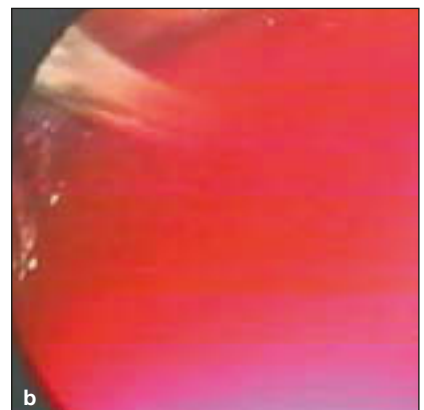
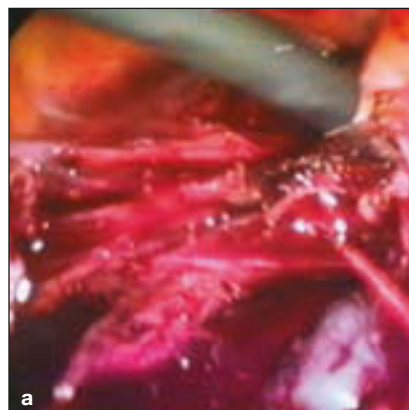
■ Postoperative complications

- 1 injury common peroneal nerve (lateral popliteal sciatic nerve) with paresis of the right lower limb for 3 months. Occurred in 1990 following excision of a large myoma by colpotomy and consequent compression. The patient made a full recovery (**Fig. 15**).
- 1 pericholecystitis in 1991 following rupture of a dermoid cyst and spillage of its contents in the peritoneal cavity. The patient presented with an acute abdomen in the right hypochondrium known as pericholecystitis. The complication resolved with simple medical treatment (**Fig. 16**).

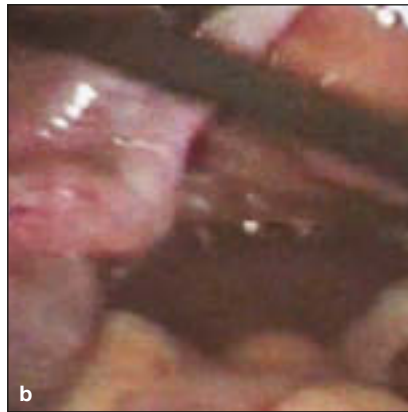
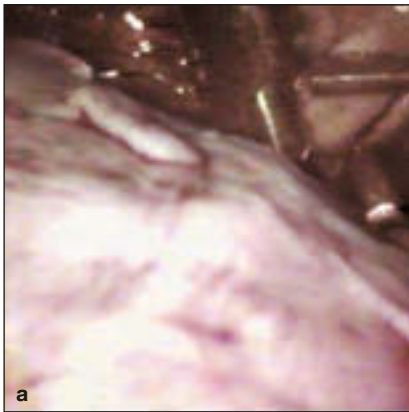
- 1 chemical peritonitis in 1998. In conservative adnexal surgery, it is customary to leave dextran in the peritoneal cavity to prevent the formation of adhesions. This high molecular weight polymer can provoke a peritoneal reaction known as chemical peritonitis. It was treated by laparoscopy with aspiration of 10 l ascitic fluid and lavage with saline. The patient made a good recovery (**Figs. 17–18**).
- 1 injury of the ileum in 2003 which turned into an ileal fistula on the second postoperative day. After laparotomy, the patient made a good recovery.
- 1 umbilical herniation in 1994. A week after laparoscopy when the sutures were being removed, the patient had umbilical herniation with prolapse of the omentum. The umbilical hernia was repaired after resection of the omentum and the patient made a good recovery.



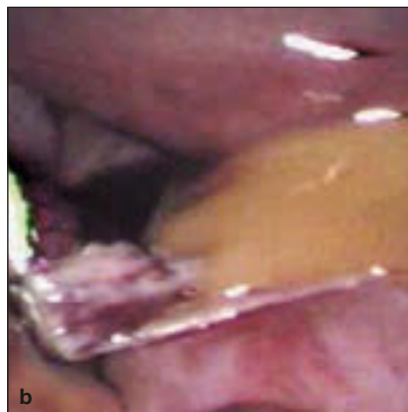
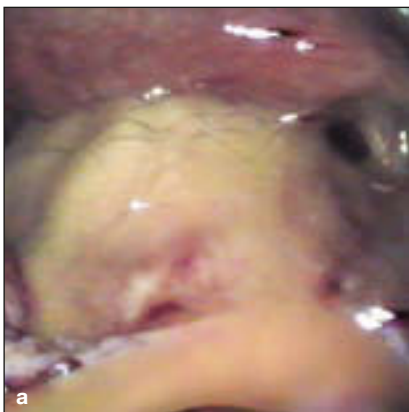Figs. 13 a, b
Sequence demonstrating iatrogenic injury of the bladder, injection of methylene blue and suture, 1994.



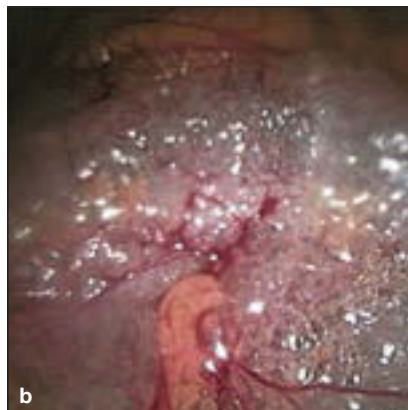
Figs. 14 a, b
Sequence demonstrating bleeding from the left uterine artery during hysterectomy, 1993.



Figs. 15 a, b
Sequence demonstrating iatrogenic injury of the sciatic nerve during extraction of myoma via colpotomy, 1993.



Figs. 16 a, b
Sequence demonstrating pericholecystitis after rupture of a dermoid cyst, 1993.



Figs. 17 a, b
Sequence demonstrating a patient with dextran in the peritoneal cavity, 1988.

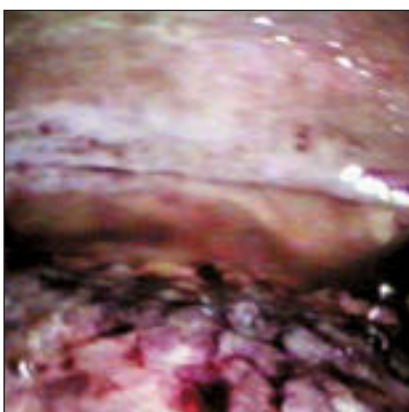

Fig. 18
Second-look laparoscopy in the patient with chemical peritonitis due to dextran, 1988.

7.0 Prevention of Complications

In the strict sense, a complication is an event that is largely unpredictable. The term “prevention of complications” therefore has very precise limits. What follows in this section should be interpreted as advice born out of reason and experience on how to reduce the incidence of complications in laparoscopic surgery.

The balance between the surgical indications, the technical abilities of the surgical team and the available instruments is an equation that determines the results of laparoscopic surgery and thus the incidence of complications. Coordination and good personal relationships within the surgical team will reduce the rate of errors. Moreover, safety systems are described for each step of laparoscopic surgery, mainly based on correct ergonomics and an appropriate surgical technique. Observing these standards reduces the risk of complications. The aim of this section is to provide awareness of the possible complications. Communicating and sharing the complications is positive because information exchange aids in preventing them. Learning laparoscopic surgery requires continuous practice and updating of one’s knowledge. The learning curve accompanies the first steps and also the maturity and accomplishment of the laparoscopic surgeon. The incidence of complications is closely linked to the learning curve. Laparoscopic surgery is a surgical procedure with various grades of complexity while using

a single access route. Providing the patient with accurate information about the various alternatives in the event of a complication improves patient compliance and facilitates recovery. Experience shows that a good relationship between physician and patient based on the physician’s responsibility and the patient’s trust will help to reduce the number of complications.

- Balance between indications, technical abilities of the surgical team and instruments
- Coordination and good personal relationships within the surgical team
- Safety standards valid during surgery
- Knowing that a number of complications exists
- Knowing what the possible complications are
- Training and continuing education of the surgical team
- Maximum respect for the patient
- Not all laparoscopic surgeries are the same
- Patient’s informed consent
- Good doctor–patient relationship
- Appropriate documentation in the patient records

Tab. 14

8.0 Intraoperative Resolution of Complications

It is absolutely essential to be well prepared for an intraoperative solution of complications because late resolution worsens the situation in every aspect. At the moment of the complication, a phenomenon is found that involves a large number of indeterminates. The surgeon has a tendency not to admit his mistake and this can be the first difficulty in solving the problem. Indeed, the first step is correct diagnosis of the complication and an appropriate strategy for solving it. It is self-evident that intraoperative resolution of complications is the best alternative. Therefore, a decision must be made whether or not to resolve the complication laparoscopically or to opt for conversion to laparotomy as the more appropriate measure. Often, the outcome will depend on this preliminary decision. The coordination and ability of the surgical team are put to the test when the complication is discovered. In this case, the support that the admitting hospital can provide becomes important, possibly involving the intensive care

unit, hemotherapy and multidisciplinary services, which can obviously influence the course of a potentially lethal complication. Very often, the experience of the gynecologic surgeon in the fields of vascular and intestinal surgery and urology is limited. The ability to benefit from the assistance of other multidisciplinary services and other specialist branches of surgery is a basic foundation for the gynecologic surgeon in the event of a serious complication.

- Correct diagnosis of the complication
- Knowledge of the limits of laparoscopic surgery
- Maximum coordination of the surgical team
- Appropriate complexity of the admitting hospital
- Possibility for interdisciplinary consultation

Tab. 15

9.0 Module for Recording Data on Complications in Gynecologic Endoscopic Surgery (endogin.net)

The following is a module which is used on the www.endogin.net website to classify and document the complications that can occur in laparoscopic surgery. The specific aim of the module is to simplify data collection. It can also form part of a multicenter project for collecting data via the Internet,

in which individuals, teams, institutions and scientific associations can participate. When the data have been collected according to our module, it will be possible to have precise qualitative and quantitative consistency regarding the incidence of complications according to time and place.

<p>Diagnosis of the complication</p> <ul style="list-style-type: none"> ■ During surgery ■ During hospitalization ■ After discharge <ul style="list-style-type: none"> ◆ Within 3 days ◆ After 3 days 	<ul style="list-style-type: none"> ◆ electrosurgery <ul style="list-style-type: none"> □ burns ◆ light source and laparoscope <ul style="list-style-type: none"> □ burns ◆ various <ul style="list-style-type: none"> □ CO₂ □ operating lamp □ electrical equipment 	<p>Importance of the complication</p> <ul style="list-style-type: none"> ■ major, potentially lethal ■ minor
<p>Type of complication</p> <ul style="list-style-type: none"> ■ Anesthesiological <ul style="list-style-type: none"> ◆ related to the anesthesia itself ◆ related to the surgical procedure ■ Related to the access route <ul style="list-style-type: none"> ◆ laparoscopic ◆ hysteroscopic ◆ THL ◆ laparotomy ◆ vaginal ■ Related to the surgical procedure <ul style="list-style-type: none"> ◆ hemorrhage <ul style="list-style-type: none"> □ without blood transfusion □ with blood transfusion ◆ infection <ul style="list-style-type: none"> □ general <ul style="list-style-type: none"> ● septicemia ● peritonitis □ local <ul style="list-style-type: none"> ● surgical wound ● urinary □ collection <ul style="list-style-type: none"> ● abdominal ● pelvic ● retroperitoneal ◆ mechanical injury <ul style="list-style-type: none"> □ ileus □ torsion □ adhesion □ obliteration ◆ traumatic injury <ul style="list-style-type: none"> □ perforation □ division □ laceration □ electrosurgical injury ■ Operating room and instruments <ul style="list-style-type: none"> ◆ operating table <ul style="list-style-type: none"> □ nerve compression □ joint injuries □ muscle injuries □ stretching of plexuses 	<p>Site of the complication</p> <ul style="list-style-type: none"> ■ Abdominal wall <ul style="list-style-type: none"> ◆ emphysema ◆ hematoma ◆ infection ◆ eventration ■ Urinary <ul style="list-style-type: none"> ◆ ureter ◆ bladder ■ Vascular <ul style="list-style-type: none"> ◆ small vessels ◆ large vessels ■ Neural <ul style="list-style-type: none"> ◆ plexuses <ul style="list-style-type: none"> □ motor □ sensory □ sympathetic □ parasympathetic ◆ nerves ■ Intestinal <ul style="list-style-type: none"> ◆ stomach ◆ intestine ◆ colon ■ Uterine <ul style="list-style-type: none"> ◆ perforation ◆ synechiae ◆ hematometra ◆ pyometra ◆ metrorrhagia ■ Tubes <ul style="list-style-type: none"> ◆ section ◆ removal <ul style="list-style-type: none"> □ unilateral □ bilateral ■ Ovary <ul style="list-style-type: none"> ◆ removal <ul style="list-style-type: none"> □ unilateral □ bilateral 	<p>Resolution of the complication</p> <ul style="list-style-type: none"> ■ phase of resolution <ul style="list-style-type: none"> ◆ immediate ◆ deferred ■ route of resolution <ul style="list-style-type: none"> ◆ laparoscopy ◆ hysteroscopy ◆ laparotomy ◆ vaginal ■ surgical team <ul style="list-style-type: none"> ◆ same team ◆ with gynecologic consultation ◆ with multidisciplinary consultation ◆ with a different team ■ hospital admission <ul style="list-style-type: none"> ◆ in the same place as the surgery <ul style="list-style-type: none"> □ normal □ intensive therapy ◆ transferred to a different center <ul style="list-style-type: none"> □ of greater complexity □ immediate □ deferred ■ re-operation <ul style="list-style-type: none"> ◆ number ◆ route of operation <ul style="list-style-type: none"> □ laparoscopic □ hysteroscopic □ laparotomy □ vaginal □ radiologic ■ procedure performed <ul style="list-style-type: none"> ◆ description
<p>Progress of the complication</p> <ul style="list-style-type: none"> ■ without consequences ■ with consequences <ul style="list-style-type: none"> □ slight □ moderate, interfering with ordinary life □ disabling □ type of consequence □ description ■ lethal 		
<p>Analysis of the complication</p> <ul style="list-style-type: none"> ■ Description 		

10.0 Conclusions

To sum up, it can be concluded that complications exist and are inherent in surgical practice. In laparoscopic surgery there are complications specific to this technique. The complications are usually due to a sum of factors, which should be analyzed and discussed even if this often appears to be difficult for surgeons. We must accept the idea that it is essential to communicate our complications in order to contribute to a better knowledge of them. Classification and an appropriate record of these events will improve understanding. The best way to prevent complications is surgical

knowledge of how they can be avoided. However, the best treatment of complications is intraoperative.

From 1998 to 2005 in the gynecology service of the Callao Surgical Institute in Buenos Aires, the complication rate was 10/1261 (0.79%) and the rate of major complications was 3/1261 (0.23%). In a French multicenter study, the percentages were similar, with 0.89% for complications in general and 0.22–0.34% for major ones. A few studies have reported higher percentages.

Recommended Reading

1. BARBOSA C: Manual Ilustrado de Cirurgia Videolaparoscópica em Ginecologia Texto e atlas. 1998; Cap 10, Livraria e Editora RevienteR Ltda.
2. BATEMAN BG, KOLP LA, HOEGER K: Complications of laparoscopy-operative and diagnostic. *Fertility and Sterility* 1996; 66: 30–35.
3. BONGARD F, DUBECZ S, KLEIN S: Complications of therapeutic laparoscopy. *Current Problems in Surgery* 1994; 862–924
4. CANDIANI M, CANIS M, LUCIANO A, MARANA R, MENCAGLIA L, WATTIEZ A, ZUPI E: Testo Atlante di Chirurgia Laparoscopica in Ginecologia. 1997; Cap.7.1, Poli industria Chimica SpA. Edizione fuori commercio. Mosby Doyma Italia Srl. Milano, Italia
5. CHAPRON CM, PIERRE F, LACROIX S, QUERLEU D, LANSAC J, DUBUISSON J-B: Major vascular injuries during gynecologic laparoscopy. *J Am Coll Surg* 1997; 185:461–65.
6. GARRY R, PHILLIPS G: How safe is the laparoscopic approach to hysterectomy? *Gynaecological Endoscopy* 1995, 4:77–79.
7. GARRY R, PHILLIPS G: How safe is the laparoscopic approach to hysterectomy? *Gynaecological Endoscopy*. 1995; 4:77–79.
8. HASSON HM: Open laparoscopy as a Method of Access in Laparoscopic Surgery. *Gynaecological Endoscopy*, 1999; 8:353–62
9. HASSON HM: Open laparoscopy: In *Gynecology and Obstetrics*, J.J. Sciarra, Ed., Harper & Row, Philadelphia, 1992, Vol. 6, Ch.44, p.1–8.
10. HILL DJ: Complications of the laparoscopic approach. *Bailliers Clin Obstet Gynaecol* 1994; 8:865–79.
11. LEHEMANN-WILLENBROCK E, RIEDEL HH, MECKE H AND SEMM K: Pelviscopy/Laparoscopy and its Complications in Germany, 1949–1988; *The Journal of Reproductive Medicine* 37(8): 671–677, Ref 10, Ago 1992.
12. LIU C.Y: Laparoscopic Hysterectomy and Pelvic Floor Reconstruction. 1996; Cap 15, Blackwell Science Inc.
13. MENEIRO M, MELOTTI G, MOURET PH: Cirugía Laparoscopica. 1996; Cap2:34–38, Editorial Médica Panamericana.
14. MIRANDA CS, CARVAJAL A: Complication of operative Gynecological Laparoscopy. *Journal Society Laparoscopic Surgeons* 2003 Jan-Mar; 7(1):53–8.
15. NEZHAT C, CHILDERS J, NEZHAT F, NEZHAT C.H, SEIDMAN D.S: Major retroperitoneal vascular injury during laparoscopic surgery. : *Hum-Reprod*. 1997 Mar; 12(3): 480–3
16. NORDESTGAARD AG, BODILY KC, OSBORNE RW, BUTTORFF JD: Mayor vascular injuries during laparoscopic procedures. *The American Journal of Surgery* 1995; 169: 543–545
17. PETERSON HB, HULKA JF, PHILLIPS JM: American Association of Gynecologic Laparoscopists' 1988 Membership Survey on Operative Laparoscopy. *The Journal of Reproductive Medicine*, 586–598.
18. Primera Cátedra de Ginecología, Hospital de Clínicas Universidad de Buenos Aires: Memoria anual de 1994
19. QUERLEU D: y col. (conversiones) *Gynecol. Endosc.* 2:3–6, 1993.
20. QUERLEU D, CHAPRON C: Complications of gynecologic laparoscopic surgery. *Current Opinion in Obstetrics and Gynecology* 1995, 7: 257–261
21. SADEGHI-NEJAD H, KAVOUSSI LR, PETERS CA: Bowel injury in open technique laparoscopic cannula placement. *Urology* 1996; 43:559–60.
22. SARROUF J: Complicaciones en Laparoscopia- 2002, XIV Congreso Peruano de Obstetricia y Ginecología Lima, Perú en: Docencia, www.endogin.net.
23. SEMM K: Cutting versus conical tip designs *Endosc-Surg-Allied-Technol.* 1995 Feb; 3(1): 39–47
24. TERNAMIAN A M: Laparoscopy without trocars. *Surg-Endosc.* 1997 Aug; 11(8): 815–8
25. VANCAILLIE TG: Active electrode monitoring. How to prevent unintentional thermal injury associated with monopolar electrosurgery at laparoscopy. *Surg-Endosc.* 1998 Aug; 12(8): 1009–12
26. VIDELA RIVERO LC. ORTIZ J: Encuesta sobre Complicaciones en Cirugía Laparoscopica. *Revista de la Sociedad Argentina de Cirugía Laparoscopica.* 1995, 2: 16–21
27. VIDELA RIVERO LC: Base de datos de Complicaciones en Endoscopia Ginecológica 2005, www.endogin.net.

**Recommended Set
for Gynecological Laparoscopic Surgery**

Basic Instrument Set for Gynecological Laparoscopic Surgery

26003 AA	HOPKINS® II Straight Forward Telescope 0° , enlarged view, diameter 10 mm, length 31 cm, autoclavable , fiber optic light transmission incorporated, color code: green	38361 ON	RoBi® Grasping Forceps , CLERMONT-FERRAND model, rotating, dismantling, with connector pin for bipolar coagulation, double action jaws, fenestrated, with especially fine atraumatic serration, size 5 mm, length 36 cm
26120 JL	VERESS Pneumoperitoneum Needle , with spring-loaded blunt stylet LUER-Lock, autoclavable , diameter 2.1 mm, length 13 cm	38361 MD	RoBi® KELLY Grasping Forceps , CLERMONT-FERRAND model, rotating, dismantling, with connector pin for bipolar coagulation, double action jaws, especially suitable for dissection, size 5 mm, length 36 cm
30103 MC	Trocar , with conical tip, insufflation stopcock, multifunctional valve, size 11 cm, working length 10.5 cm, color code: green, including: Trocar only , with conical tip Cannula , without valve, with insufflation stopcock Multifunctional Valve , size 11 mm	26173 BN	Suction and Irrigation Tube , anti-reflex surface, with two-way stopcock, for single hand control, size 5 mm, length 36 cm
30160 MC	3 x Trocar , with conical tip, insufflation stopcock, multifunctional valve, size 6 mm, working length 10.5 cm, color code: black, including: Trocar only , with conical tip Cannula , without valve, with insufflation stopcock Multifunctional Valve , size 6 mm	30675 ND	MANHES High Frequency Needle , for splitting and coagulation, insulated, with connector pin for unipolar coagulation, length 31 cm
30160 S	3 x Thread Sleeve , for trocar size 6 mm, color code: black	26775 UF	Coagulating and Dissecting Electrode , L-shaped, with connector pin for unipolar coagulation, size 5 mm, length 36 cm
33351 ME	CLICKLINE® MANHES Grasping Forceps , rotating, dismantling, insulated, with connector pin for unipolar coagulation, with irrigation connection for cleaning, single action jaws, width of jaws 4.8 mm, with multiple teeth, for atraumatic and accurate grasping, size 5 mm, length 36 cm	26775 UE	Coagulating and Dissecting Electrode , spatula-shaped, blunt with connector pin for unipolar coagulation, size 5 mm, working length 36 cm
33361 ON	CLICKLINE® Grasping Forceps , rotating, dismantling, without connector pin for unipolar coagulation, single action jaws, with especially fine serration, fenestrated, size 5 mm, length 36 cm	26005 M	Unipolar High Frequency Cord , with 5 mm plug for HF unit, models KARL STORZ AUTOCON® system (50, 200, 350), AUTOCON® II 400 (111, 115) and Erbe type ICC, length 300 cm
33351 SN	CLICKLINE® SCHNEIDER Lymph Node Grasping Forceps , rotating, dismantling, insulated, with connector pin for unipolar coagulation, single action jaws, atraumatic, size 5 mm, length 36 cm	26176 LE	Bipolar High Frequency Cord , to KARL STORZ Coagulator 26021 B/C/D, 860021 B/C/D, 27810 B/C/D, 28810 B/C/D, AUTOCON® system (50, 200, 350), AUTOCON® II 400 system (111, 113, 115) and Erbe-Coagulator, T- and ICC-row, length 300 cm
33351 ML	CLICKLINE® KELLY Dissecting and Grasping Forceps , rotating, dismantling, insulated, with connector pin for unipolar coagulation, double action jaws, size 5 mm, length 36 cm	39301 C	Plastic Container for Sterilizing and Storage of two Telescopes , perforated, with transparent lid, with silicone telescope holder, external dimensions (w x d x h): 520 x 90 x 45 mm
34351 MA	CLICKLINE® Scissors , rotating, dismantling, insulated, with connector pin for unipolar coagulation, double action jaws, length of blades 17 mm, serrated, curved, spoon-shaped blades, size 5 mm, length 36 cm	39301 CH	Silicone Telescope Holder , for two telescopes, up to size 10 mm, i. e. for use with plastic containers 39301 B to D
38361 ML	RoBi® KELLY Grasping Forceps , CLERMONT-FERRAND model, rotating, dismantling, with connector pin for bipolar coagulation, double action jaws, especially suitable for dissection, size 5 mm, length 36 cm	26173 SP	2 x SZABO-BERCI Needle Holder "PARROT-JAW®" , with diamond coated jaws, straight handle, with ratchet, for use with trocars size 6 mm, length 33 cm, for use with suture material 2/0 – 4/0, needle size SH (Ethicon), EN-S (Ski), V 20 (USSC)
		26596 CL	CICE Knot Tier , CLERMONT-FERRAND model, for extracorporeal knotting, size 5 mm, length 36 cm
		26168 D	Uterine Manipulator , CLERMONT-FERRAND model, complete
		26168 TN	Uterine Manipulator , TINTARA model, complete
		26175 BL	Myoma Fixation Instrument , screw-shaped, size 5 mm
		26 7130 18	ROTOCUT G1 , diameter 12 mm/15 mm cutter, for laparoscopic application for use with UNIDRIVE® S III
		495 NCS	Fiber Optic Light Cable , extremely heat-resistant, diameter 4.8 mm, length 250 cm

HOPKINS® II Straight Forward Telescope 0°

diameter 10 mm, length 31 cm



26003 AA



26003 AA

HOPKINS® II Straight Forward Telescope 0°, enlarged view, diameter 10 mm, length 31 cm, **autoclavable**, fiber optic light transmission incorporated, color code: green

VERESS Pneumoperitoneum Needle




26120 JL

26120 JL

VERESS Pneumoperitoneum Needle, with spring-loaded blunt stylet LUER-Lock, **autoclavable**, diameter 2.1 mm, length 13 cm

Trocars and Accessories

Size 6 mm, 11 mm




30103 MC **Trocar**, with conical tip, insufflation stopcock, multifunctional valve, size 11 cm, working length 10.5 cm, color code: green,

including:

Trocar only, with conical tip

Cannula, without valve, with insufflation stopcock

Multifunctional Valve, size 11 mm



330160 MC **Trocar**, with conical tip, insufflation stopcock, multifunctional valve, size 6 mm, working length 10.5 cm, color code: black,

including:

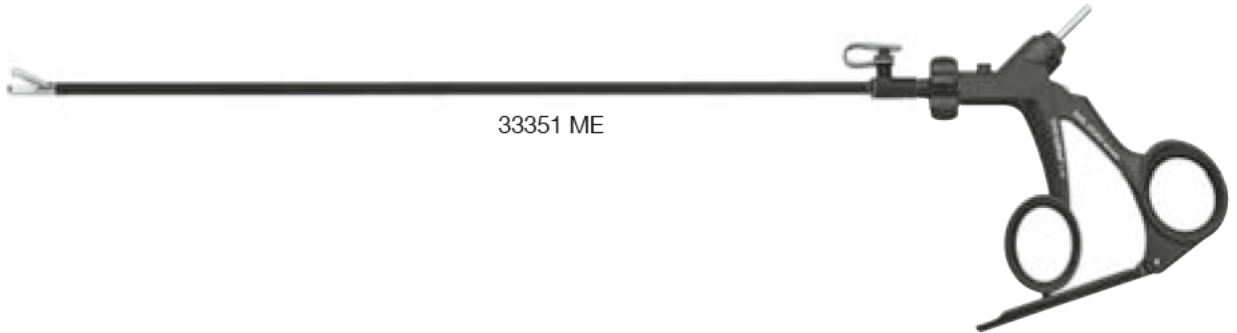
Trocar only, with conical tip

Cannula, without valve, with insufflation stopcock

Multifunctional Valve, size 6 mm



30160 S **Thread Sleeve**, for trocar size 6 mm, color code: black

CLICKLINE® Grasping Forceps

33351 ME



33351 ME

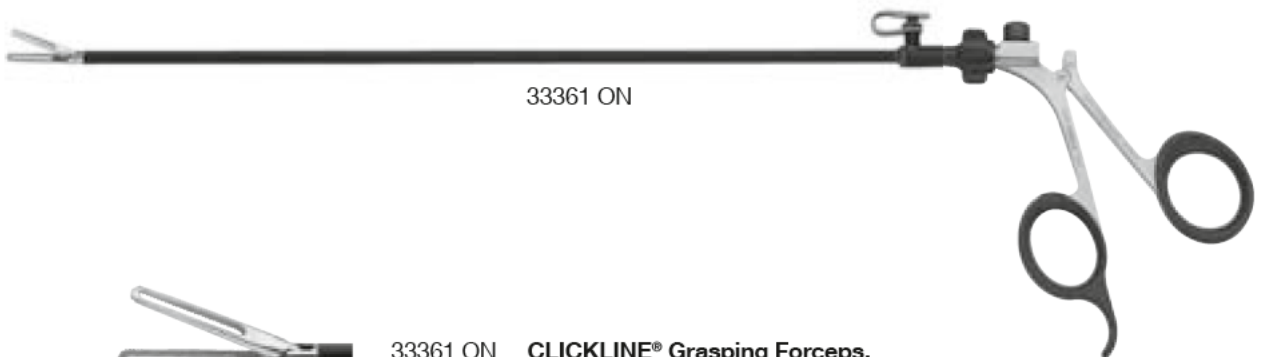
CLICKLINE® MANHES Grasping Forceps, rotating, dismantling, insulated, with connector pin for unipolar coagulation, with irrigation connection for cleaning, single action jaws, width of jaws 4.8 mm, with multiple teeth, for atraumatic and accurate grasping, size 5 mm, length 36 cm,

including:

Plastic Handle, with MANHES style ratchet

Outer Sheath, insulated

Forceps Insert



33361 ON



33361 ON

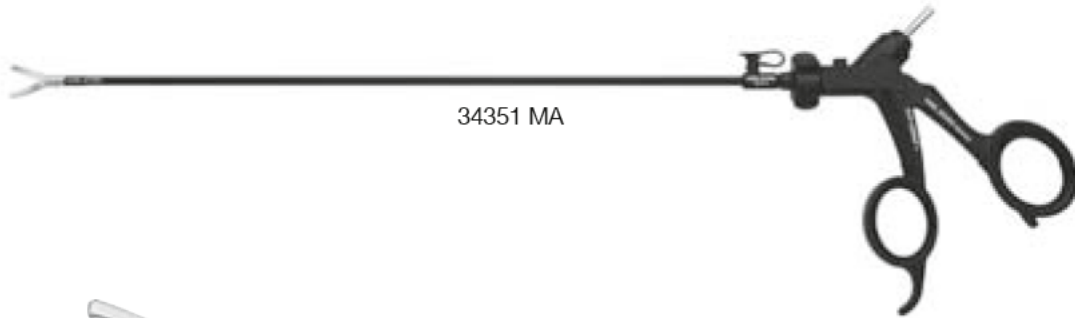
CLICKLINE® Grasping Forceps, rotating, dismantling, without connector pin for unipolar coagulation, single action jaws, with especially fine serration, fenestrated, size 5 mm, length 36 cm

including:

Metal Handle, without ratchet

Outer Sheath, insulated

Forceps Insert

CLICKLINE® Grasping Forceps

34351 MA



33351 SN

CLICKLINE® SCHNEIDER Lymph Node Grasping Forceps, rotating, dismantling, insulated, with connector pin for unipolar coagulation, single action jaws, atraumatic, size 5 mm, length 36 cm

including:

Plastic Handle, without ratchet**Outer Sheath**, insulated**Forceps Insert**

33351 ML

CLICKLINE® KELLY Dissecting and Grasping Forceps, rotating, dismantling, insulated, with connector pin for unipolar coagulation, double action jaws, size 5 mm, length 36 cm

including:

Plastic Handle, without ratchet**Outer Sheath**, insulated**Forceps Insert**

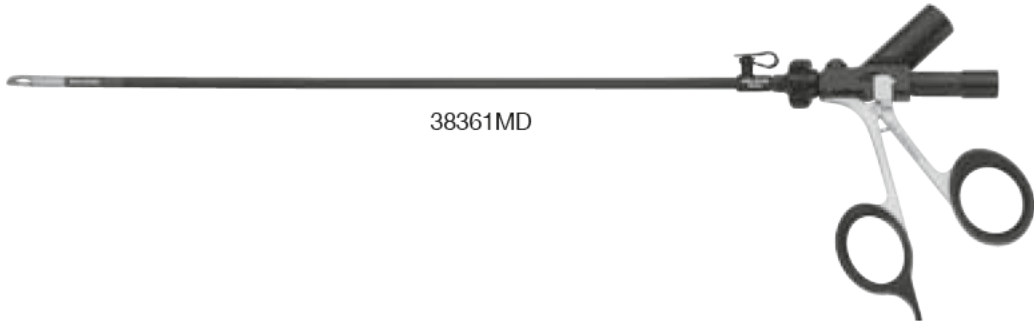
34351 MA

CLICKLINE® Scissors, rotating, dismantling, insulated, with connector pin for unipolar coagulation, double action jaws, length of blades 17 mm, serrated, curved, spoon-shaped blades, size 5 mm, length 36 cm

including:

Plastic Handle, without ratchet**Outer Sheath**, insulated**Scissors Insert**

RoBi® Grasping Forceps



38361MD



38361 MD

RoBi® KELLY Dissecting and Grasping Forceps, CLERMONT-FERRAND Model, rotating, dismantling, with connector pin for bipolar coagulation, with LUER-Lock irrigation connector for cleaning, double action jaws, especially suitable for dissection, size 5 mm, length 36 cm,

including:

Ring Handle, without ratchet, with larger contact area

Metal Outer Sheath, insulated

Forceps Insert



38361 ML

RoBi® KELLY Dissecting and Grasping Forceps, CLERMONT-FERRAND Model, rotating, dismantling, with connector pin for bipolar coagulation, with LUER-Lock irrigation connector for cleaning, double action jaws, especially suitable for dissection, size 5 mm, length 36 cm,

including:

Ring Handle, without ratchet, with larger contact area

Metal Outer Sheath, insulated

Forceps Insert



38361 ON

RoBi® Grasping Forceps, CLERMONT-FERRAND model, rotating, dismantling, with connector pin for bipolar coagulation, with LUER-Lock irrigation connector for cleaning, double action jaws, fenestrated, with especially fine atraumatic serration, size 5 mm, length 36 cm,


including:

Ring Handle, without ratchet, with larger contact area

Metal Outer Sheath, insulated

Forceps Insert

Suction and Irrigation Tube



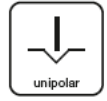
26173 BN



26173 BN

Suction and Irrigation Tube, anti-reflex surface, with two-way stopcock, for single hand control, size 5 mm, length 36 cm

MANHES High Frequency Needle



30675 ND



30675 ND **MANHES High Frequency Needle**,
for splitting and coagulation, insulated,
with connector pin for unipolar coagulation,
length 31 cm

Coagulating and Dissecting Electrodes



26775 UF



26775 UF **Coagulating and Dissecting Electrode**,
L-shaped, with connector pin for unipolar coagulation,
size 5 mm, length 36 cm



26775 UE **Coagulating and Dissecting Electrode**,
spatula-shaped, blunt,
with connector pin for unipolar coagulation,
size 5 mm, working length 36 cm

High Frequency Cords




26005 M **Unipolar High Frequency Cord**, with 5 mm plug for HF unit,
models **KARL STORZ** AUTOCON® system (50, 200, 350),
AUTOCON® II 400 (111, 115) and Erbe type ICC, length 300 cm



26176 LE **Bipolar High Frequency Cord**, to **KARL STORZ** Coagulator
26021 B/C/D, 860021 B/C/D, 27810 B/C/D, 28810 B/C/D,
AUTOCON® system (50, 200, 350), AUTOCON® II 400 system
(111, 113, 115) and Erbe-Coagulator, T- and ICC-row,
length 300 cm

Plastic Container for Sterilizing and Storage of Two Telescopes



39301 A – D

- 39301 C **Plastic Container for Sterilizing and Storage of Two Telescopes**, perforated, with transparent lid, with silicone telescope holder, external dimensions (w x d x h): 520 x 90 x 45 mm including:
- Bottom Part**
 - Lid**
 - Silicone Telescope Holder**
- For 10 mm Laparoscopy Telescopes and similar

Silicone Telescope Holder



39301 CH



- 39301 CH **Silicone Telescope Holder**, for **two** telescopes, up to size 10 mm, i. e. for use with plastic containers 39301 B to D

SZABO-BERCI Needle Holder “PARROT-JAW®”



26173 SP



26173 SP **SZABO-BERCI Needle Holder “PARROT-JAW®”**, with diamond coated jaws, straight handle, with ratchet, for use with trocars size 6 mm, length 33 cm, for use with suture material 2/0 – 4/0, needle size SH (Ethicon), EN-S (Ski), V 20 (USSC)


CICE Knot Tier



26596 CL



26596 CL **CICE Knot Tier**, CLERMONT-FERRAND model, for extracorporeal knotting, size 5 mm, length 36 cm

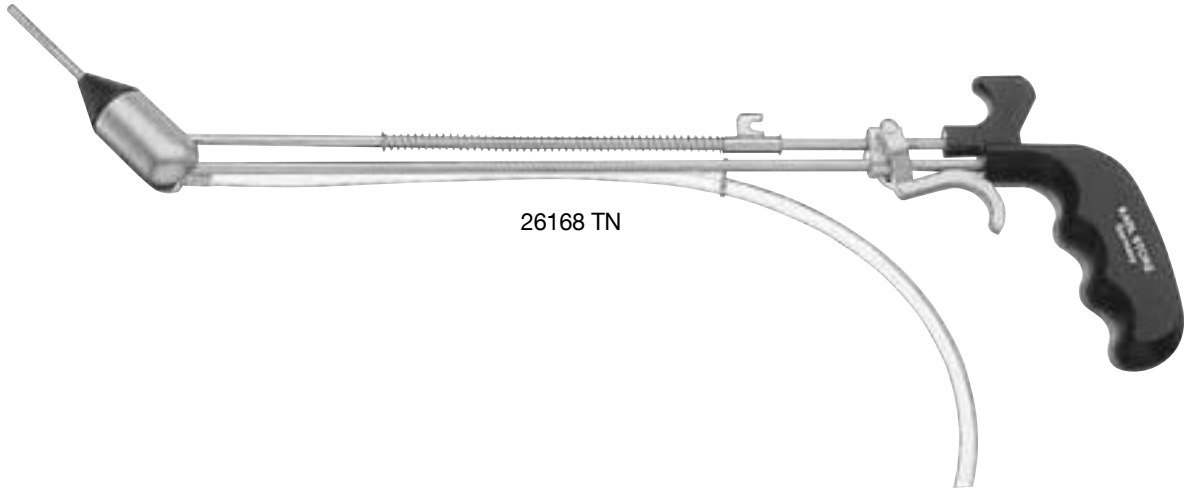
CLERMONT-FERRAND **Uterine Manipulator**

- 26168 D **Uterine Manipulator**, CLERMONT-FERRAND Model, complete, including:
- Manipulator Handle**
 - Manipulator rod**
 - Sealing cylinder**
 - Silicone seals**, package of 3 pieces (3 sizes)
 - Manipulator tube**
 - Manipulator insert**, conical, with thread, medium
 - Manipulator insert**, cylindrical, without thread
 - Anatomical blade**, short

Optional accessories (not contained in the set):

- 26168 DF **Manipulator insert**, conical, with thread, short
- 26168 DH **Manipulator insert**, conical, with thread, long
- 26168 DM **Anatomical blade**, medium
- 26168 DL **Anatomical blade**, long

TINTARA Uterine Manipulator



26168 TN



26168 TNB



26168 TNC



26168 TND



26168 TNF

- 26168 TN TINTARA Uterine Manipulator, complete including:
Handle
Working Insert, size 4.0 mm, length 50 mm
Working Insert, size 4.5 mm, length 50 mm
Working Insert, size 4.8 mm, length 80 mm
Tube Support

Optional Accessories:

- NEW** 26168 TNF **Working Insert**, size 4 mm, length 40 mm, for use with 26168 TN
- NEW** 26168 TNS **Pertubation Tube**, with LUER-Lock Tube Connector 600008
- 26168 V **Uterine Tenaculum Forceps**, length 22 cm

Myoma Fixation Instrument




26175 BL



- 26175 BL **Myoma Fixation Instrument**, screw-shaped, size 5 mm

ROTOCUT G1 Morcellator



- 267130 18 **ROTOCUT G1**, diameter 12 mm/15 mm cutter,
for laparoscopic application, for use with UNIDRIVE® S III
including:
- 1x **Hollow shaft motor**
 - 1x **Obturator**, with blunt tip, diameter 12 mm
 - 1x **Same**, diameter 15 mm
 - 1x **Trocarbush**, askew, diameter 12 mm
 - 1x **Same**, diameter 15 mm
 - 1x **Handle**, laparoscopic
 - 1x **Cutter**, laparoscopic, diameter 12 mm
 - 1x **Same**, diameter 15 mm
 - 1x **Protective cap**, diameter 12 mm
 - 1x **Same**, diameter 15 mm
 - 1x **Motor valve**, diameter 12 mm
 - 1x **Same**, diameter 15 mm
 - 1x **Sealing cap**, for single use, 10 pieces
 - 1x **CLICKLINE® Tenaculum Forceps**, diameter 12 mm
 - 1x **Same**, diameter 15 mm
 - 1x **Spacer**, package of 5 pcs

Maintenance and care of the motor components (Rotocut G1, EC-motor), must be carried out with the universal spray 280052 B+C).

Please order separately.

Accessories

Cleaning Adaptor for ROTOCUT G1

Manual Cleaning



267130 80 **Cleaning Adaptor** with cone adaption for cleaning pistol for fast and easy manual rinsing or drying of hollow shaft motor ROTOCUT G1 **267130 30**

Machine Cleaning



267130 81 **Cleaning Adaptor** with LUER-Lock connector for cleaning machine for fast and easy mechanically rinsing of hollow shaft motor ROTOCUT G1 **267130 30**

Accessories


Tray system for cleaning, sterilization and storage of ROTOCUT G1 Morcellator system for laparoscopic use.

Special features:

- Ensures a suitable, validated reprocessing of the ROTOCUT G1 morcellator system
- Combined or separate use of trays
- Lid with opening for cleaning adaptor
- Mechanical cleaning and disinfection is facilitated by cleaning ports
- Safe transport and handling during routine use in the OR and CSSD (Central Sterile Supply Department)
- Protection of the whole ROTOCUT G1 system during transportation, cleaning and storage




- 39510 G **Wire Tray System for ROTOCUT G1**, for cleaning, sterilization and storage of one ROTOCUT G1 Morcellator system, including:
Base Tray
Upper Tray
Lid
 External dimensions (w x d x h):
 535 x 250 x 210 mm
 (ROTOCUT G1 articles not included)



- 39510 GA **Bottom Level** to wire tray system 39510 G (forceps level), external dimensions (w x d x h): 535 x 250 x 100 mm
 (ROTOCUT G1 articles not included)



- 39510 GB **Upper Level** to wire tray system 39510 G (motor level), external dimensions (w x d x h): 535 x 250 x 100 mm
 (ROTOCUT G1 articles not included)



- 39510 GL **Lid** for wire tray system 39510 G, with handles, external dimensions (w x d): 530 x 250 mm
 (can be mounted either on Base Tray or on Upper Tray)

IMAGE1 HUB™ HD

FULL HD Camera Control Unit



- Maximum resolution and the consistent use of the 16:9 aspect ratio guarantee FULL HD (High Definition)
- Endoscopic camera systems are equipped with three CCD chips that support the 16:9 input format as well as capturing images with a resolution of 1920 x 1080 pixels

The benefits of FULL HD (High Definition) for medical applications are:

- High input resolution of the camera head delivers more detail and depth of field with natural color rendition
- Using 16:9 format during image acquisition enlarges the field of view
- The 16:9 format of the widescreen monitor supports ergonomic viewing
- Enhanced color brilliance for optimal diagnosis
- Progressive scan technology provides a steady, flicker-free display and helps eliminate eyestrain and fatigue



22201011U1XX

22201011U1

IMAGE1 HUB™ HD Camera Control Unit SCB

for use with IMAGE1 FULL HD and IMAGE1 standard one- and three-chip camera heads, max. resolution 1920 x 1080 pixels, with integrated **KARL STORZ-SCB** and digital Image Processing Module, color systems **PAL/NTSC**, power supply 100 – 240 VAC, 50/60 Hz including:

Mains Cord**BNC/BNC Video Cable****S-Video (Y/C) Connecting Cable****Special RGBS Connecting Cable**2x **Connecting Cable**, for controlling peripheral units**DVI-D Connecting Cable****SCB Connecting Cable****Keyboard**, with US English character set

22201011U102

IMAGE1 HUB™ HD Camera Control Unit SCB, with SDI module

for use with IMAGE1 FULL HD and IMAGE1 standard one- and three-chip camera heads, max. resolution 1920 x 1080 pixels, **with integrated SDI (Serial Digital Interface) module**, **KARL STORZ-SCB** and digital Image Processing Module, color systems **PAL/NTSC**, power supply 100 – 240 VAC, 50/60 Hz including:

Mains Cord**BNC/BNC Video Cable****S-Video (Y/C) Connecting Cable****Special RGBS Connecting Cable**2x **Connecting Cable**, for controlling peripheral units**DVI-D Connecting Cable****SCB Connecting Cable****Keyboard**, with US English character set

IMAGE 1 HUB™ HD

FULL HD Camera Control Unit



22201011U11X

22201011U110 IMAGE 1 HUB™ HD Camera Control Unit SCB, with ICM module

for use with IMAGE 1 FULL HD and IMAGE 1 standard one- and three-chip camera heads, max. resolution 1920 x 1080 pixels, **with integrated ICM (Image Capture Module), KARL STORZ-SCB** and digital Image Processing Module, color systems **PAL/NTSC**, power supply 100 – 240 VAC, 50/60 Hz including:

Mains Cord

BNC/BNC Cable

S-Video (Y/C) Connecting Cable

Special RGBS Connecting Cable

2x Connecting Cable, for controlling peripheral units

DVI-D Connecting Cable

SCB Connecting Cable

Keyboard, with US English character set

2x KARL STORZ USB Stick, 4 GB

22201011U112 IMAGE 1 HUB™ HD Camera Control Unit SCB, with SDI/ICM module

for use with IMAGE 1 FULL HD and IMAGE 1 standard one- and three-chip camera heads, max. resolution 1920 x 1080 pixels, **with integrated ICM (Image Capture Module) and SDI (Serial Digital Interface) modules, KARL STORZ-SCB** and integrated digital Image Processing Module, color systems **PAL/NTSC**, power supply 100 – 240 VAC, 50/60 Hz including:

Mains Cord

BNC/BNC Video Cable

S-Video (Y/C) Connecting Cable

Special RGBS Connecting Cable

2x Connecting Cable, for controlling peripheral units

DVI-D Connecting Cable

SCB Connecting Cable

Keyboard, with US English character set

2x KARL STORZ USB Stick, 4 GB

Specifications:

Signal-to-noise ratio	IMAGE 1 HUB™ HD, three-chip camera systems ≥ 60 dB
AGC	Microprocessor-controlled
Video output	- FULL HD signal to DVI-D socket (2x) - SDI signal to BNC socket, (only IMAGE 1 HUB™ HD with SDI module (2x)) - RGBS signal to D-Sub socket - S-Video to 4-pin Mini-DIN socket (2x) - Composite signal to BNC socket
Input	Keyboard for title generator, 5-pin DIN socket

Control output/input	- KARL STORZ-SCB to 6-pin socket Mini-DIN socket (2x) - 3.5 mm stereo jack plug (ACC 1, ACC 2), - Serial port at RJ-11 - USB port (only IMAGE 1 HUB™ HD with ICM) (2x)
Dimensions w x h x d	305 x 89 x 335 mm
Weight	3.35 kg
Power supply	100–240 VAC, 50/60 Hz
Certified to:	IEC 601-1, 601-2-18, CSA 22.2 No. 601, UL 2601-1 and CE acc. to MDD, protection class 1/CF defibrillation-safe

IMAGE 1 HD**FULL HD Camera Control Unit**

SCB®



222020 11U1XX

222020 11U110 IMAGE 1 HD Camera Control Unit SCB, with ICM module

for use with IMAGE 1 FULL HD three-chip camera heads, max. resolution 1920 x 1080 pixels, **with integrated ICM (Image Capture Module), KARL STORZ-SCB** and digital Image Processing Module, power supply 100 – 240 VAC, 50/60 Hz

including:

Mains Cord2x **Connecting Cable**, for controlling peripheral units**DVI-D Connecting Cable****SCB Connecting Cable****Keyboard**, with US English character set2x **KARL STORZ USB Stick**, 4 GB
222020 11U1 IMAGE 1 HD Camera Control Unit SCB

for use with IMAGE 1 FULL HD three-chip camera heads, max. resolution 1920 x 1080 pixels, with integrated **KARL STORZ-SCB** and digital Image Processing Module, power supply 100 – 240 VAC, 50/60 Hz

including:

Mains Cord2x **SCB Connecting Cable****DVI-D Connecting Cable****Connecting Cable**, for controlling peripheral units**Keyboard**, with US English character set**Specifications:**

Signal-to-noise ratio	IMAGE 1 HD, three-chip camera systems ≥ 60 dB
AGC	Microprocessor-controlled
Video output	FULL HD Signal to DVI-D socket
Input	Keyboard for title generator, 5-pin DIN socket
Control output/input	- USB port (only IMAGE 1 HD with ICM) (2x) - Serial port at RJ-11 - 3.5 mm stereo jack plug (ACC 1, ACC 2) - KARL STORZ-SCB to 6-pin socket Mini-DIN socket (2x)

Dimensions w x h x d	305 x 89 x 335 mm
Weight	3.35 kg
Power supply	100–240 VAC, 50/60 Hz
Certified to	IEC 601-1, 601-2-18, CSA 22.2 No. 601, UL 2601-1 and CE acc. to MDD, protection class 1/CF defibrillation-safe

IMAGE 1 HUB™ HD FULL HD Camera Heads



222200 55-3

222200 55-3 50 Hz 60 Hz IMAGE 1 H3-Z Three-Chip FULL HD Camera Head

max. resolution 1920 x 1080 pixels, progressive scan, soakable, gas- and plasma-sterilizable, with integrated Parfocal Zoom Lens, focal length $f = 15 - 31$ mm (2x), 2 freely programmable camera head buttons

Specifications:

IMAGE 1 FULL HD Camera Heads	H3-Z
50 Hz	222200 55-3 (50/60 Hz)
60 Hz	-
Image sensor	3x 1/8" CCD chip
Pixel output signal H x V	1920 x 1080
Dimensions (w x h x l)	39 x 49 x 114 mm
Weight	270 g
Optical interface	integrated Parfocal Zoom Lens, $f = 15-31$ mm (2x)
Min. sensitivity	F 1.4/1.17 Lux
Grip mechanism	standard eyepiece adaptor
Cable	non-detachable
Cable length	300 cm



222200 56-3

NEW

222200 56-3 50 Hz 60 Hz IMAGE 1 H3-P Three-Chip FULL HD Pendulum Camera Head

with pendulum system and fixed focus, max. resolution 1920 x 1080 pixels, progressive scan, soakable, gas- and plasma-sterilizable, focal length $f = 16$ mm, 2 freely programmable camera head buttons, for use with color systems **PAL/NTSC**

Specifications:

IMAGE1 FULL HD Camera Heads	H3-P
50/60 Hz	222200 56-3 (PAL/NTSC)
Image sensor	3x 1/8" CCD chip
Pixel output signal H x V	1920 x 1080
Dimensions (w x h x l)	35 x 47 x 88 mm
Weight	226 g
Optical interface	pendulum system, fixed focus $f = 16$ mm
Min. sensitivity	F 1.4/1.17 Lux
Grip mechanism	standard eyepiece adaptor
Cable	non-detachable
Cable length	300 cm

For use with IMAGE 1 HUB™ HD Camera Control Unit SCB 222010 11U1xx and IMAGE1 HD Camera Control Unit SCB 222020 11U1xx

IMAGE 1 HUB™ HD *NEW*
FULL HD Camera Heads – autoclavable



22 2200 61-3

22 2200 61-3 50 Hz IMAGE 1 H3-ZA
60 Hz Three-Chip FULL HD Camera Head

autoclavable, max. resolution 1920 x 1080 pixels, progressive scan, soakable, gas- and plasma-sterilizable, with integrated Parfocal Zoom Lens, focal length f = 15 – 31 mm (2x), 2 freely programmable camera head buttons, for use with color systems **PAL/NTSC**



22 2200 60-3

22 2200 60-3 50 Hz IMAGE 1 H3-FA
60 Hz Three-Chip FULL HD Camera Head

autoclavable, max. resolution 1920 x 1080 pixels, progressive scan, soakable, gas- and plasma-sterilizable, **fixed focus**, focal length f = 17 mm, 2 freely programmable camera head buttons, for use with color systems **PAL/NTSC**

Specifications:

IMAGE 1 FULL HD Camera Heads	H3-ZA	H3-FA
50 Hz	22 2200 61-3 (50/60 Hz)	22 2200 60-3 (50/60 Hz)
Image sensor	3x 1/3" CCD chip	3x 1/3" CCD chip
Pixels output signal H x V	1920 x 1080	1920 x 1080
Dimensions (w x h x l)	39 x 49 x 100 mm	39 x 49 x 93 mm
Weight	299 g	261 g
Optical interface	integrated Parfocal Zoom Lens, f = 15-31 mm	fixed focus f = 17 mm
Min. sensitivity	F 1.4/1.17 Lux	F 1.4/1.17 Lux
Grip mechanism	standard eyepiece adaptor	standard eyepiece adaptor
Cable	non-detachable	non-detachable
Cable length	300 cm	300 cm

For use with IMAGE 1 HUB™ HD Camera Control Unit SCB 22 2010 11-1xx and IMAGE 1 HD Camera Control Unit SCB 22 202011-1xx



39301 Z3TS Plastic Container for Sterilization and Storage of camera heads **IMAGE1 H3-Z, H3-ZA and H3-FA**, **autoclavable**, suitable for use with steam, gas and hydrogen peroxide sterilization, Sterrad® compatible, external dimensions (w x d x h): 385 x 255 x 75 mm

Please note: The instrument displayed is not included in the plastic container.

Only camera heads marked "autoclave" can be placed in the tray for steam sterilization.



NEW 39301 PHTS Plastic Container for Sterilization and Storage of camera heads **IMAGE1 H3-P and H3-ZI**, **autoclavable**, suitable for use with steam, gas and hydrogen peroxide sterilization, Sterrad® compatible, external dimensions (w x d x h): 385 x 255 x 75 mm

Please note: The instrument displayed is not included in the plastic container.

Only camera heads marked "autoclave" can be placed in the tray for steam sterilization.

KARL STORZ FULL HD Monitors ^{NEW}



9619 NB



9626 NB/NB-2

KARL STORZ HD and FULL HD Monitors	19"	26"	26"
Wall-mounted with VESA 100 adaption	9619 NB	9626 NB	9626 NB-2
Inputs:			
DVI-D	1x	1x	2x
Fiber Optic	optional	optional	optional
RGBS/VGA	1x	1x	2x
S-Video	1x	1x	2x
Composite/FBAS	1x	1x	2x
Outputs:			
DVI-D	●	●	●
S-Video	●	●	●
Composite/FBAS	●	●	●
Signal Format Display:			
4:3	●	●	●
5:4	●	●	●
16:9	●	●	●
Picture-in-Picture	●	●	●
PAL/NTSC compatible	●	●	●

The following accessories are included:

Mains Cord

External 24VDC Power Supply

Signal cables: DVI-D, BNC

Optional accessories:

9626 SF Pedestal, for 96XX monitor series

Specifications:

KARL STORZ FULL HD Monitors	19"	26"
Desktop with pedestal	optional	optional
Wall-mounted with 100 adaption	9619 NB	9626 NB/NB-2
Brightness	280 cd/m ²	400 cd/m ²
Max. viewing angle	178° vertical	178° vertical
Pixel distance	0.29 mm	0.30 mm
Reaction time	12 ms	12 ms
Contrast ratio	700:1	700:1
Mount	100 mm VESA	100 mm VESA
Weight	10 kg	14 kg
Rated power	120 W	120 W
Operating conditions	0–40°C	0–40°C
Storage	-20–60°C	-20–60°C
Rel. humidity	max. 80%	max. 80%
Dimensions w x h x d	469.5 x 416 x 75.5 mm	699 x 445.6 x 87.5 mm
Power supply	85–264 VAC	85–264 VAC

KARL STORZ HD, HD WIDEVIEW™ and HD LED Backlight Monitors



9524 NB, 9526 NBL, 9726 NB

	TFT Flat Screens		HD WIDEVIEW Monitors		
	15"	19"	24"	26"	
Wall-mounted with VESA 100 adaption	9515 NB	9519 NB	9524 NB	9526 NBL	9726 NB
Inputs:					
SDI	●	●	–	–	–
HD-SDI	●	●	●	●	●
3G-SDI	–	–	–	●	●
RGBS	●	●	●	●	●
S-Video	●	●	●	●	●
Composite/FBAS	●	●	●	●	●
SOG	–	●	●	●	●
DVI-D	●	●	●	●	●
Fiber Optic	–	–	–	–	●
VGA	●	●	●	●	●
Outputs:					
SDI	–	●	●	●	●
HD-SDI	–	●	●	●	●
3G-SDI	–	–	–	●	●
RGBS	–	●	●	●	●
S-Video	–	●	●	●	●
Composite/FBAS	–	●	●	●	●
DVI-D	–	●	●	●	●
Signal Format Display:					
4:3	●	●	●	●	●
5:4	–	●	●	●	●
16:9	–	–	●	●	●
16:10	–	–	●	–	–
Picture-in-Picture	–	●	●	●	●
PAL/NTSC compatible	●	●	●	●	●

The following accessories are included:

Mains Cord

External 24VDC Power Supply

Signal cables

Optional accessories:

9526 SF **Pedestal** for 15", 19", 24" and 26" monitors from the 95XX- and 97XX-series

KARL STORZ HD, HD WIDEVIEW™ and HD LED Backlight Monitors



Specifications:

Wall-mounted with VESA 100 adaption	15"	19"	24"	26"	26"
	9515 NB	9519 NB	9524 NB	9526 NBL	9726 NB
Brightness	430 cd/m ²	300 cd/m ²	400 cd/m ²	400 cd/m ²	800 cd/m ²
Max. viewing angle	178° vertical	178° vertical	178° vertical	178° vertical	178° vertical
Pixel distance	0.297 mm	0.294 mm	0.270 mm	0.3 mm	0.3 mm
Reaction time	10–15 ms	10–16 ms	5–12 ms	8 ms	8 ms
Contrast ratio	500:1	600:1	1000:1	1000:1	1000:1
Mount	100 mm VESA	100 mm VESA	100 mm VESA	100 mm VESA	100 mm VESA
Weight	4.8 kg	6.8 kg	7.3 kg	7.3 kg	8.2 kg
Rated power	40 Watt	65 Watt	115 Watt	60 Watt	130 Watt
Operating conditions	0–40 °C	0–38 °C	0–40 °C	0–40 °C	0–40 °C
Storage	-20–60 °C	-20–60 °C	-20–60 °C	-20–60 °C	-20–60 °C
Rel. humidity	5–85%, non-condensing	5–85%, non-condensing	20–85%, non-condensing	20–85%, non-condensing	20–85%, non-condensing
Dimensions w x h x d	386 x 302 x 81 mm	465 x 400 x 98 mm	597 x 401 x 100 mm	73 x 418 x 88 mm	673 x 418 x 88 mm
Power supply	100–240 VAC	100–240 VAC	100–240 VAC	100–240 VAC	100–240 VAC

9515 NB ^{NEW} 15" Monitor

Wall-mounted with VESA 100 adaption, color systems **PAL/NTSC**, max. screen resolution 1024 x 768, power supply 100 – 240 VAC, 50/60 Hz

including:

Power Supply

Mains Cord

Signal cables: S-Video (Y/C), DVI-D

9519 NB 19" HD Monitor

Wall-mounted with VESA 100 adaption, color systems **PAL/NTSC**, max. screen resolution 1280 x 1024, power supply 100 – 240 VAC, 50/60 Hz

including:

Power Supply

Mains Cord

Signal cables: DVI-D, BNC

9524 NB 24" HD WIDEVIEW Monitor

Wall-mounted with VESA 100 adaption, color systems **PAL/NTSC**, max. screen resolution 1920 x 1200, image format 16:10, power supply 100 – 240 VAC, 50/60 Hz

including:

Power Supply

Mains Cord

Signal cables: DVI-D, BNC

LED Backlight Monitors ^{NEW}

9526 NBL 26" HD Monitor with LED Backlight

Wall-mounted with VESA 100 adaption, color systems **PAL/NTSC**, max. screen resolution 1920 x 1080, image format 16:10, power supply 100 – 240 VAC, 50/60 Hz

including:

Power Supply

Mains Cord

Signal cables: DVI-D, BNC

9726 NB 26" HD Monitor (Highbright with LED Backlight)

Wall-mounted with VESA 100 adaption, optical input, color systems **PAL/NTSC**, max. screen resolution 1920 x 1080, image format 16:10, power supply 100 – 240 VAC, 50/60 Hz

including:

Power Supply

Mains Cord

Signal cables: DVI-D, BNC

Electronic CO₂-ENDOFLATOR with KARL STORZ SCB



26 4305 20-1

26 4305 08-1 Electronic CO₂-ENDOFLATOR SCB

including:

**Electronic CO₂-ENDOFLATOR®
with KARL STORZ SCB**

power supply: 100 – 240 VAC, 50/60 Hz

Mains Cord

Silicone Tubing Set, sterilizable

Universal Wrench

SCB Connecting Cable, length 100 cm

* **CO₂/N₂O-Gas Filter**, sterile, for single use,
package of 10

**Subject to the needs of the customer,
additional accessories must be ordered
and acquired separately.**

Please note: For fully utilizing maximum insufflation capacity of the **Electronic ENDOFLATOR® SCB** the use of **KARL STORZ HiCap® Trocars** is recommended. For additional information see catalog LAPAROSCOPY.

*) This product is marketed by **mtp**.
For additional information, please apply to:



mtp medical technical promotion gmbh,
Take-Off Gewerbepark 46,
D-78579 Neuhausen ob Eck
E-mail: info@mtp-tut.de

HAMOU® ENDOMAT® with KARL STORZ SCB Suction and Irrigation System



- 26331101-1** HAMOU® ENDOMAT® SCB,
power supply 100 – 240 VAC, 50/60 Hz
including:
Mains Cord
5x **HYST Tubing Set***, for single use
5x **LAP Tubing Set***, for single use
SCB Connecting Cable, length 100 cm
VACUsafe Promotion Pack Suction*, 2 l

Subject to the customer's application-specific requirements additional accessories must be ordered separately.

* This product is marketed by **mtp**.

For additional information, please apply to:



mtp medical technical promotion gmbh,
Take-Off Gewerbepark 46,
D-78579 Neuhausen ob Eck, Germany

HYSTEROMAT E.A.S.I.™



- 26340001-1** HYSTEROMAT E.A.S.I.™ Set,
power supply 100 – 240 VAC, 50/60 Hz,
HYSTEROMAT E.A.S.I.™: SCB ready,
compatible from RUI Release 44,
including:
Mains Cord
SCB Connecting Cable, length 100 cm
* **Basic Tubing Set**, for single use

Recommended accessories:

- * 031717-10 **IRRIGATION tubing set**, for single use, sterile, package of 10, for use with KARL STORZ HYSTEROMAT E.A.S.I.™
- * 031217-10 **SUCTION tubing set**, for single use, sterile, package of 10, for use with KARL STORZ HYSTEROMAT E.A.S.I.™

Optional accessories:

- 26340330 Two-Pedal Footswitch**, one-stage, digital, for use with HYSTEROMAT E.A.S.I.™

* This product is marketed by **mtp**.

For additional information, please apply to:



mtp medical technical promotion gmbh,
Take-Off Gewerbepark 46,
D-78579 Neuhausen ob Eck, Germany

Cold Light Fountain XENON 300 SCB



- 20133101-1 Cold Light Fountain XENON 300 SCB**
with built-in antifog air-pump, and integrated
KARL STORZ Communication Bus System SCB
power supply:
100–125 VAC/220–240 VAC, 50/60 Hz
including:
Mains Cord
Silicone Tubing Set, autoclavable, length 250 cm
SCB Connecting Cable, length 100 cm
- 20133027 Spare Lamp Module XENON**
with heat sink, 300 watt, 15 volt
- 20133028 XENON Spare Lamp**, only,
300 watt, 15 volt

Fiber Optic Light Cable



- 495 NCS Fiber Optic Light Cable**,
with straight connector, extremely heat-resistant,
diameter 4.8 mm, length 250 cm

AUTOCON® II 400 SCB



- 2053520x-12x AUTOCON® II 400**
with KARL STORZ SCB
including:
Mains Cord
SCB Connecting Cable, length 100 cm
- 20535201-125 AUTOCON® II 400 High-End, Set SCB**,
power supply 220 - 240 VAC, 50/60 Hz,
HF connecting sockets: Bipolar combination,
Multifunction, Unipolar 3-pin + Erbe,
Neutral electrode combination 6.3 mm,
jack and 2-pin, System requirements:
SCB R-UI Software,
Release 20090001-43 or higher
including:
AUTOCON® II 400 with KARL STORZ SCB
Mains Cord
SCB Connecting Cable, length 100 cm

UNIDRIVE® S III SCB ^{NEW}**Recommended System Configuration**

For use with electronic morcellators SuperCut Morcellator SAWALHE II, Rotocut G1 and DrillCut-X® II Shaver Handpiece GYN

Special Features:

- Continuously variable revolution range
- Maximum number of revolutions can be preset
- Consistently high motor performance over the entire range of revolutions
- Processor controlled number of revolutions and motor torque
- Optimized user control
- Operating elements are simple and clear to read
- Automatic handpiece recognition
- Integrated control connection for KARL STORZ pump systems in combination mode
- For use with:
 - Rotocut G1
 - SuperCut Morcellator SAWALHE II
 - DrillCut-X® II Shaver Handpiece GYN
- With connections to the KARL STORZ Communication Bus (KARL STORZ-SCB)



- 26701001-1 UNIDRIVE® S III SCB,**
power supply 100 – 120/230 – 240 VAC,
50/60 Hz
including:
Mains Cord
One-Pedal Footswitch, two-stage,
with proportional function
and pump switch function
SCB Connecting Cable, length 100 cm

Specifications:

Operation mode	- oscillating (shaver) - clockwise (morcellator)	Dimensions w x h x d	305 x 165 x 233 mm
Max. rotations	40,000 (rpm)	Weight	6.1 kg
Power supply	100-120/230-240 VAC, 50/60 Hz	Certified to	IEC 601-1, CE acc. to MDD

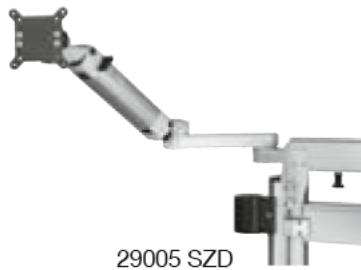
Equipment Cart



- 29005 DRB **Equipment cart,**
rides on 4 antistatic dual wheels,
2 equipped with locking brakes (rear),
3 fixed shelves, 1 with handles,
mains switch in vertical beam,
1 drawer unit with lock,
integrated cable conduits in both
vertical beams,
1 set of non-sliding stands for units,
double rear panel with integrated
electrical subdistributors with 12 sockets,
holder for power supplies,
potential earth connectors and cable
winding on the outside, 1 camera holder,
2 equipment rails sidewise,

Dimensions:

*Equipment cart: 730 x 1490 x 716 mm (w x h x d),
shelf: 630 x 480 mm (w x d),
caster diameter: 150 mm*



- 29005 SZD **Monitor Swivel Arm,**
height and side adjustable,
can be turned to the left or the right side,
swivel range 180°, overhang 600 mm,
overhang from vertical beam 800 mm,
load capacity max. 14 kg,
with monitor fixation VESA 75/100,
for usage with equipment cart 29005 DRB

Recommended Accessories for Equipment Cart



29005 TBG

29005 TBG **Isolation Transformer**,
2000 VA, with 8 IEC-sockets,
8 potential earth connectors,
230 VAC (50/60 Hz)



29003 IW

29003 IW **Earth Leakage Monitor**,
for mounting at equipment cart,
for usage with isolation transformer
29005 TBG and 29003 TBK



29005 KKM

29005 KKM **Special Power Cord**,
length 100 cm,
with IEC-plug and socket,
with UL-approval,
for usage with isolation transformer
29005 TBG and 29003 TBK



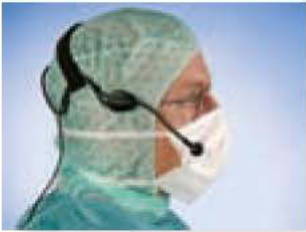29005 MZD

29005 MZD **Monitor Holding Arm**,
height and side adjustable,
swiveling and tilting,
centrally mountable, swivel range 190°,
overhang 300 mm,
load capacity max. 15 kg,
with monitor fixation VESA 75/100,
for usage with equipment cart 29005 DRB

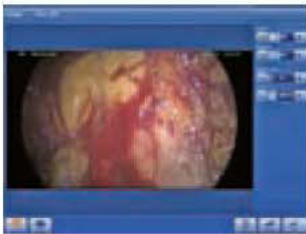Data Management and Documentation

KARL STORZ AIDA® compact NEO (HD/SD) Brilliance in documentation continues!

AIDA® compact NEO from KARL STORZ combines all the required functions for integrated and precise documentation of endoscopic procedures and open surgeries in a single system.



AIDA® compact NEO:
Voice control



AIDA® compact NEO:
Review screen



AIDA® compact NEO: Automatic
creation of standard reports



AIDA® compact NEO:
Efficient archiving

Data Acquisition

Still images, video sequences and audio comments can be recorded easily during an examination or intervention on command by either pressing the on-screen button, via voice control, foot switch pedal or the camera head button. All captured images will be displayed on the right hand side as a “thumbnail” preview to confirm that the still image has been generated.

The patient data can be entered via the on-screen keyboard or a standard keyboard.

Flexible post editing and data storage

Captured still images or video files can be previewed before final storage or can be edited and deleted easily in the edit screen.

Reliable storage of data

- Digital storage of all image, video and audio files on DVD, CD-ROM, USB stick, external/internal hard-drive or by archiving data to the hospital server via DICOM / H7
- Buffering ensures data backup if temporary storage is not possible
- Constant access to created image, video and audio files for medical documentation, patient records and for research and teaching purposes.

Efficient data archiving

Once a procedure has been completed, KARL STORZ AIDA® compact HD / SD saves all captured data efficiently on DVD, CD-ROM, USB stick, external hard-drive, internal hard-drive and/or the respective network on the FTP server. Another interesting option is to store the data directly on the PACS / HIS server, over the interface package AIDA® communication HL7 / DICOM.

Data that could not be archived successfully is maintained in a buffer memory until final storage. A two-line report header and a logo can be added to the default setting and thus tailored to the individual needs of the customer.

Multisession and Multipatient

Efficient storage of data collected from multiple patients / multiple treatment sessions via DVD, CD-ROM or a USB stick.

Functions and capabilities

- Still images up to 1920 x 1080 can be taken with both systems (advanced/standard). Videos can be recorded at up to 1080p with the advanced version and up to 720p with the standard version (through HD-SDI)*
- Storage of audio files is available in both systems
- Includes DICOM/HL7 interface package
- Printing from the recording area (individual image with meta data)
- Burns DVDs, reads blue-ray
- AIDA® Restore Configuration supports the simple import and export of system settings
- Reference screen with new QuickView (favorite folder)
- Video settings (contrast, etc.) can be made separately for all channels
- GUI adjustment options
- Compressed DICOM
- Support of OR1™ CHECKLIST V1.1
- Improved support of 15" screens with OR1™ CHECKLIST installation
- Scalable watermark
- High-quality function and switching of image and video quality without going to settings
- Sterile, ergonomic operation via touch screen, camera head buttons, and/or foot switch
- Data export on DVD, CD ROM, or USB stick, multi-session and multi-patient network storage option
- Automated generation of standard reports
- Systems approved for use in the OR environment according to EN 60601-1
- Compatible with the KARL STORZ Communication Bus (SCB) and with KARL STORZ OR1™ AV NEO
- KARL STORZ AIDA® compact advanced/standard represents an attractive, digital alternative to video printers, video recorders, and dictation devices

* A separate converter is required for DVI-IN use.



200409 12 **KARL STORZ AIDA® compact NEO standard**, documentation system for digital storage of still images, video sequences and audio files, power supply: 115/230 VAC, 50/60 Hz

200409 13 **KARL STORZ AIDA® compact NEO advanced**, documentation system for digital storage of still images, video sequences and audio files, power supply: 115/230 VAC, 50/60 Hz

Specifications:

Video Systems	- PAL - NTSC
Signal Inputs	- S-Video (Y/C) - Composite - RGBS – only in standard version - SDI - HD-SDI – only in standard version - DVI – only in standard version
Image Formats	- JPG - BMP

Video Formats	- MPEG2
Audio Formats	- WAV
Storage Media	- DVD+R - DVD+RW - DVD-R - DVD-RW - CD-R - CD-RW - USB stick

Notes: